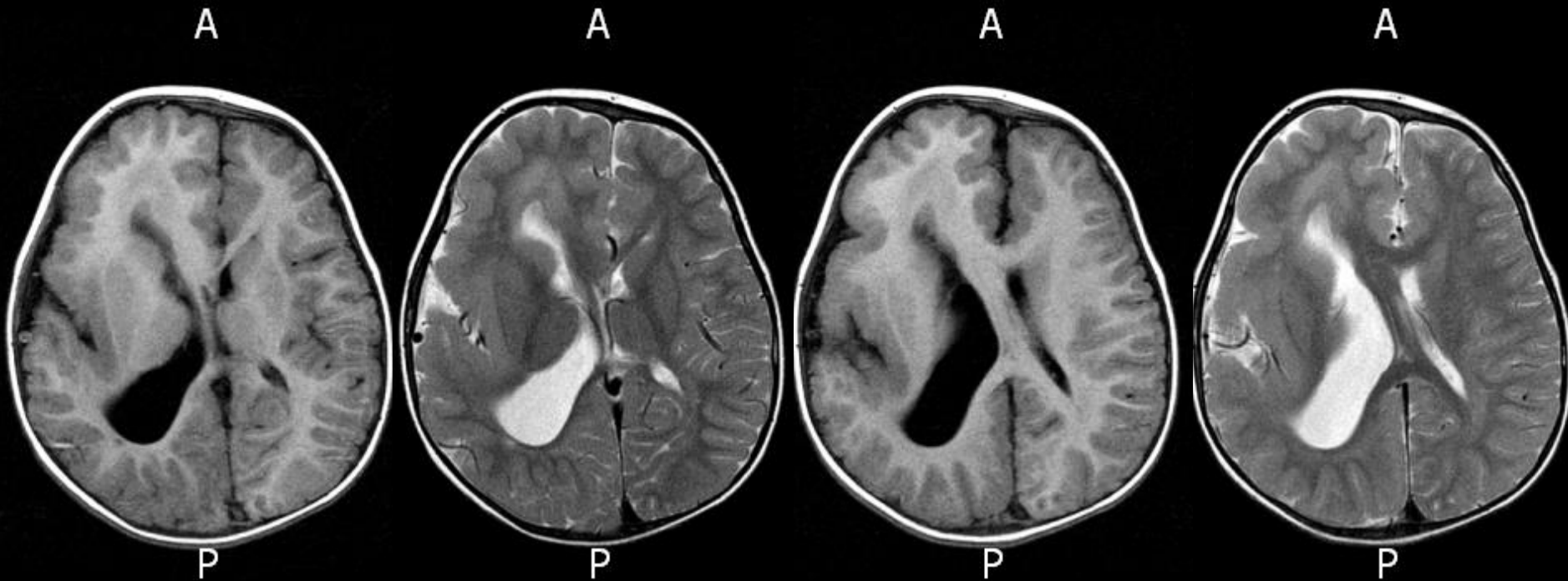


2013年11月22日  
中華民國放射線醫學會  
住院醫師閱片測驗-答案

出題醫院  
台北馬偕醫院放射線部

Q1

## 2 Y/O Male Seizure

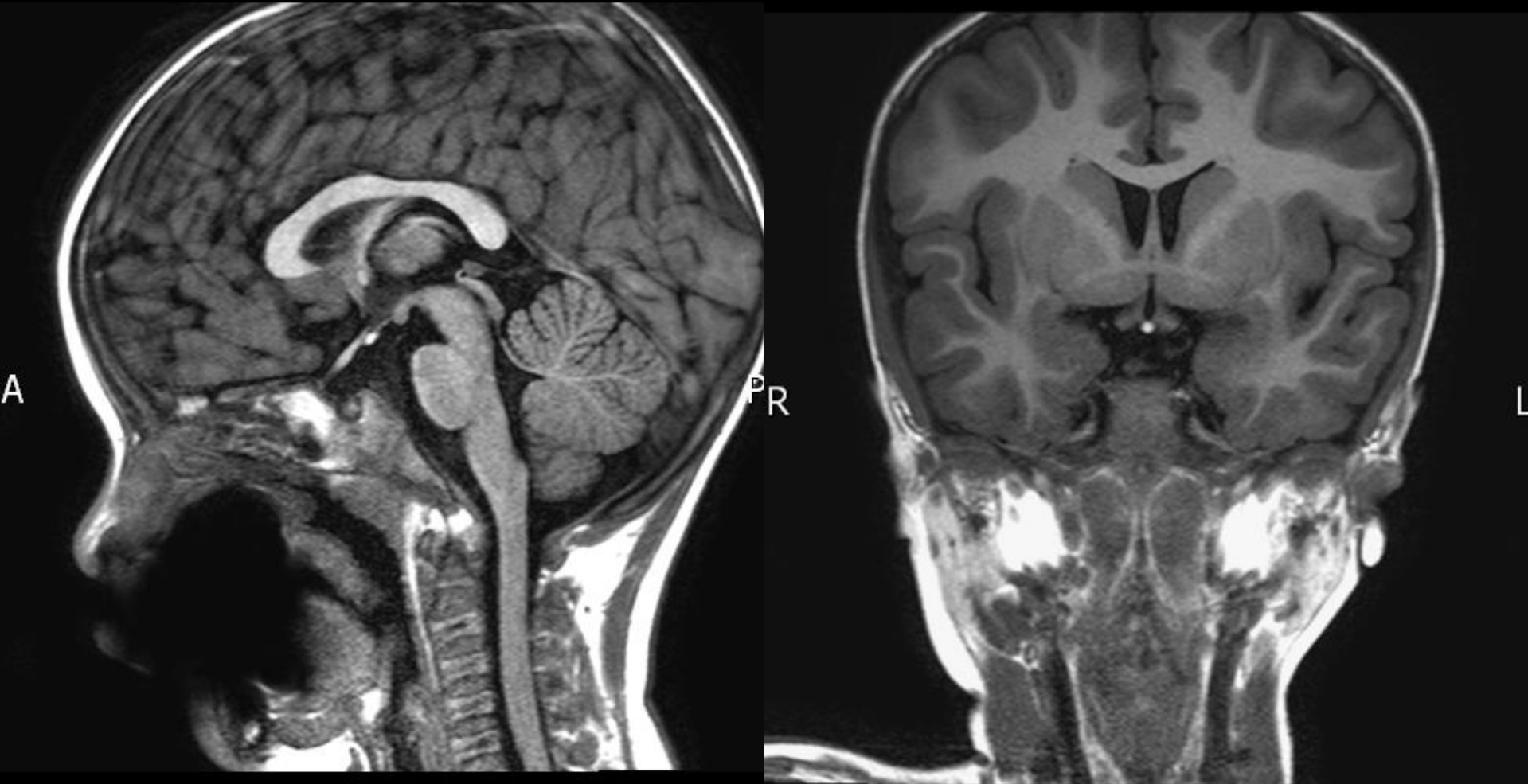


What's the proper impression ?

Megalencephaly, Rt. cerebral hemisphere

Q2

4 Y/O Male Short stature



<sup>F</sup>What's the proper impression<sup>F</sup> ?

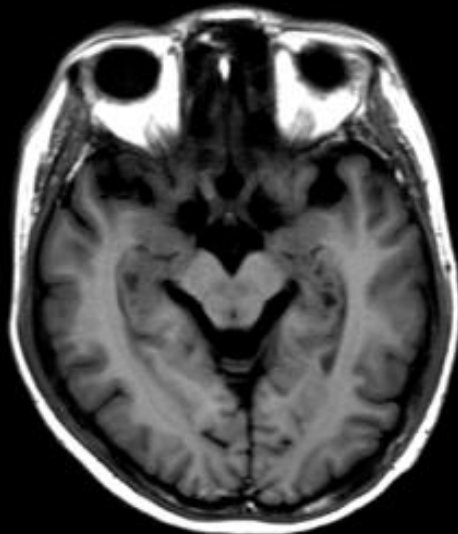


Ectopic posterior lobe of the  
pituitary gland

Q3

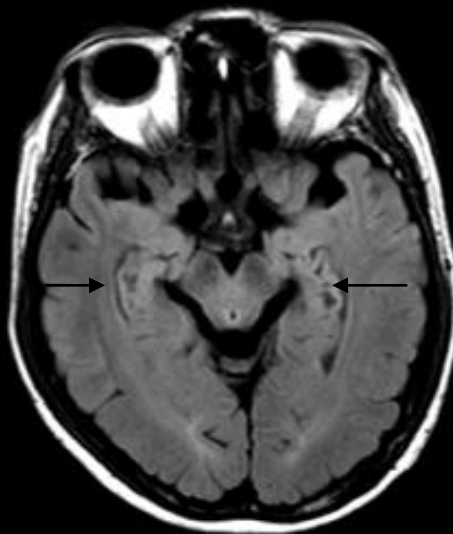
52 Y/O Female 體檢

A



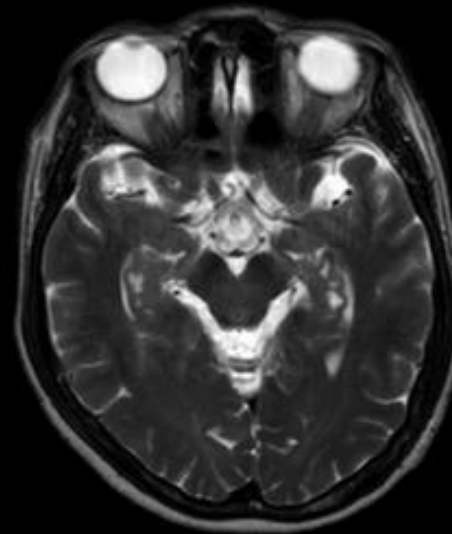
P

A



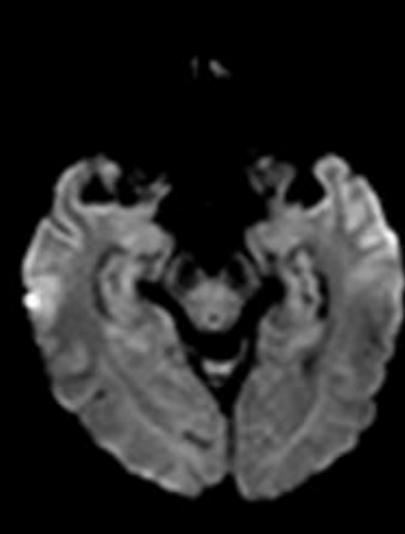
P

A



P

A



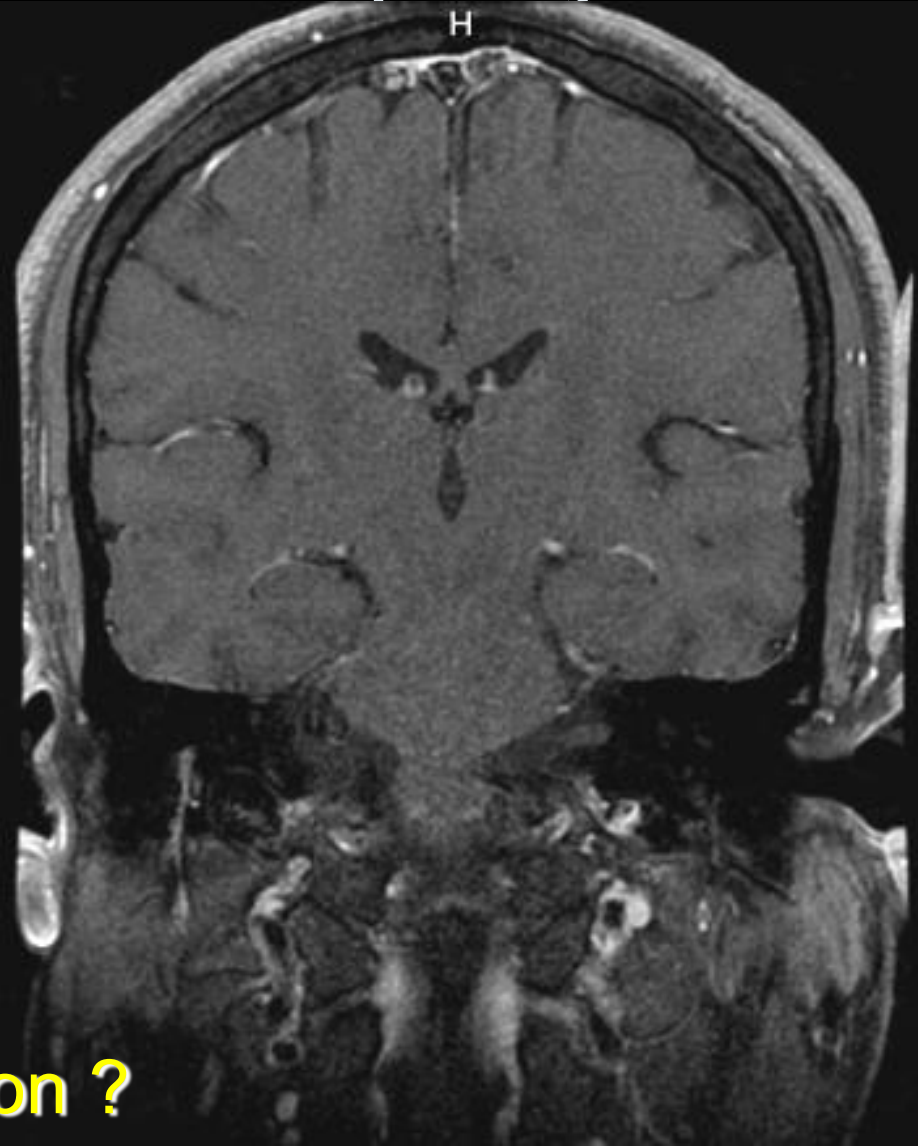
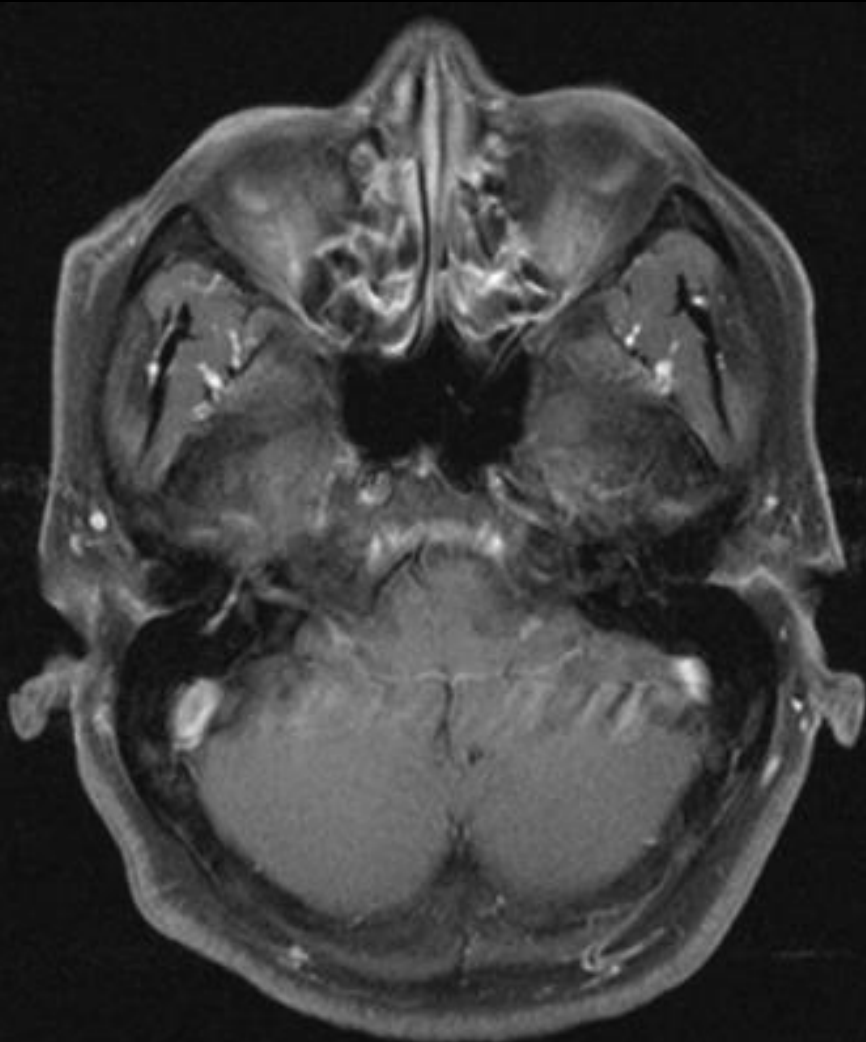
P

What is the diagnosis ?

Hippocampal sulcus remnant  
cyst

Q4

50 Y/O Male presented with  
tinnitus & facial palsy

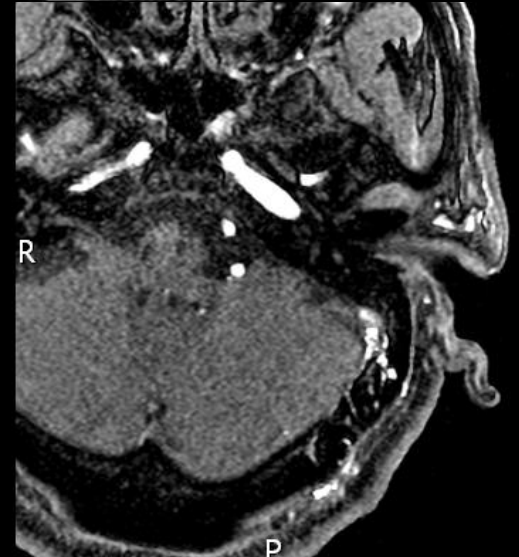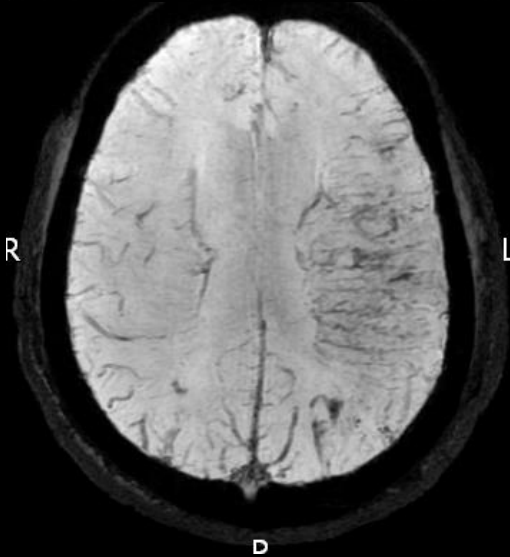
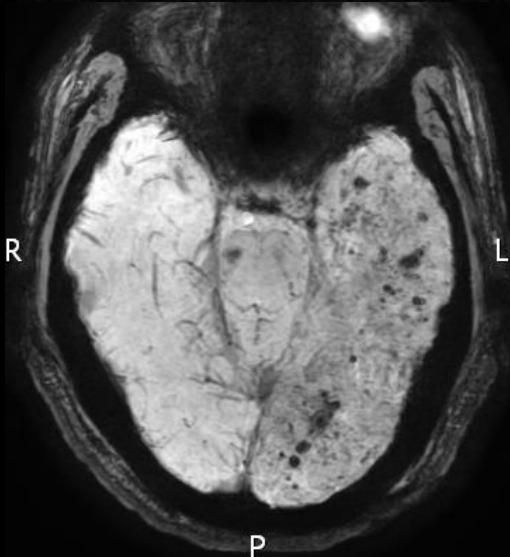
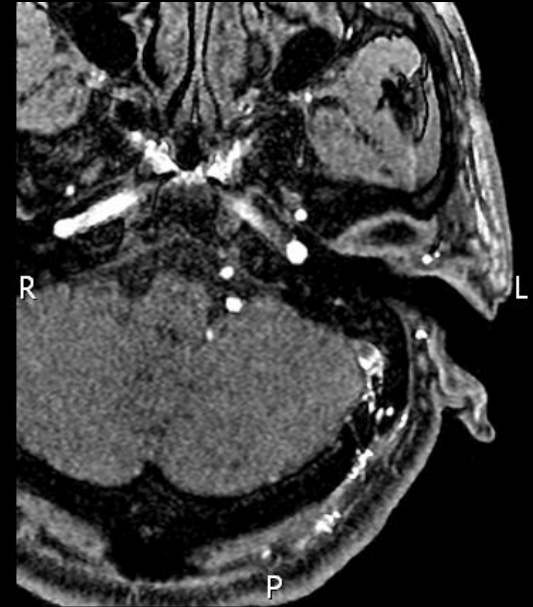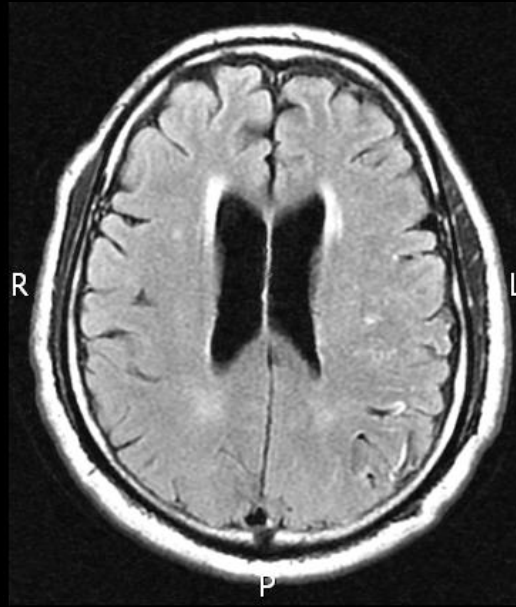


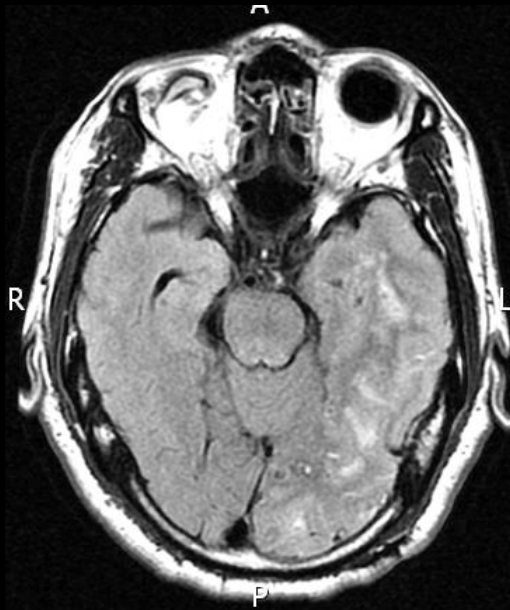What's the proper impression ?

Bell's palsy

Q5

70 Y/O M tinnitus



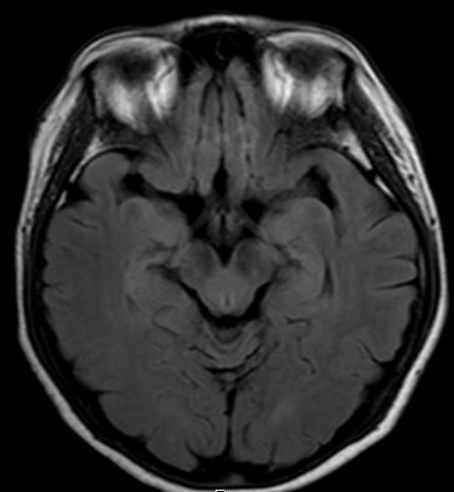
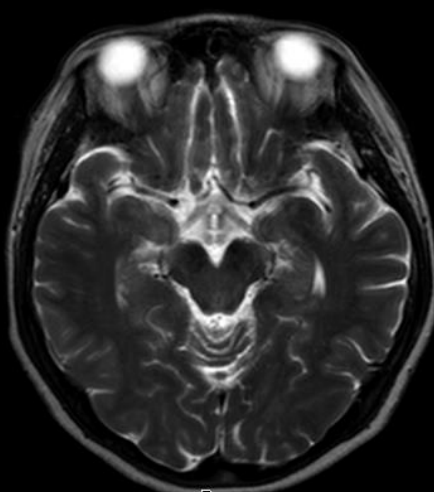
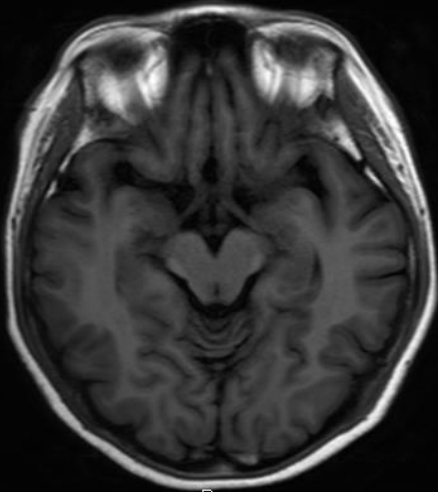
What's the proper impression ?

# Dural arteriovenous fistula

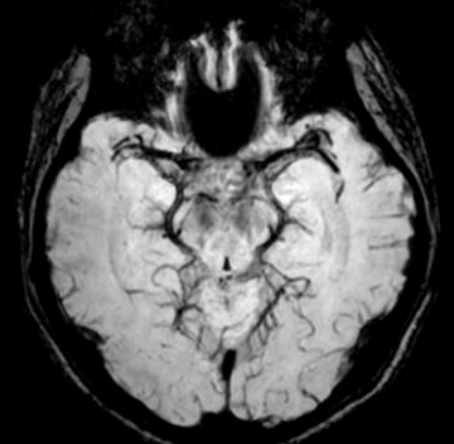
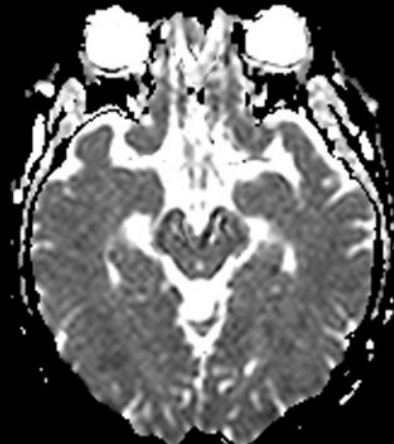
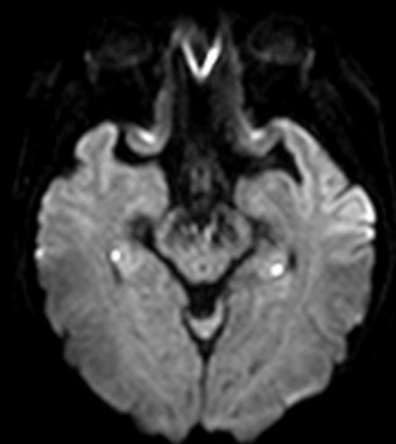


Q6

54 Y/O Female presented with  
disorientation & repetitive questioning



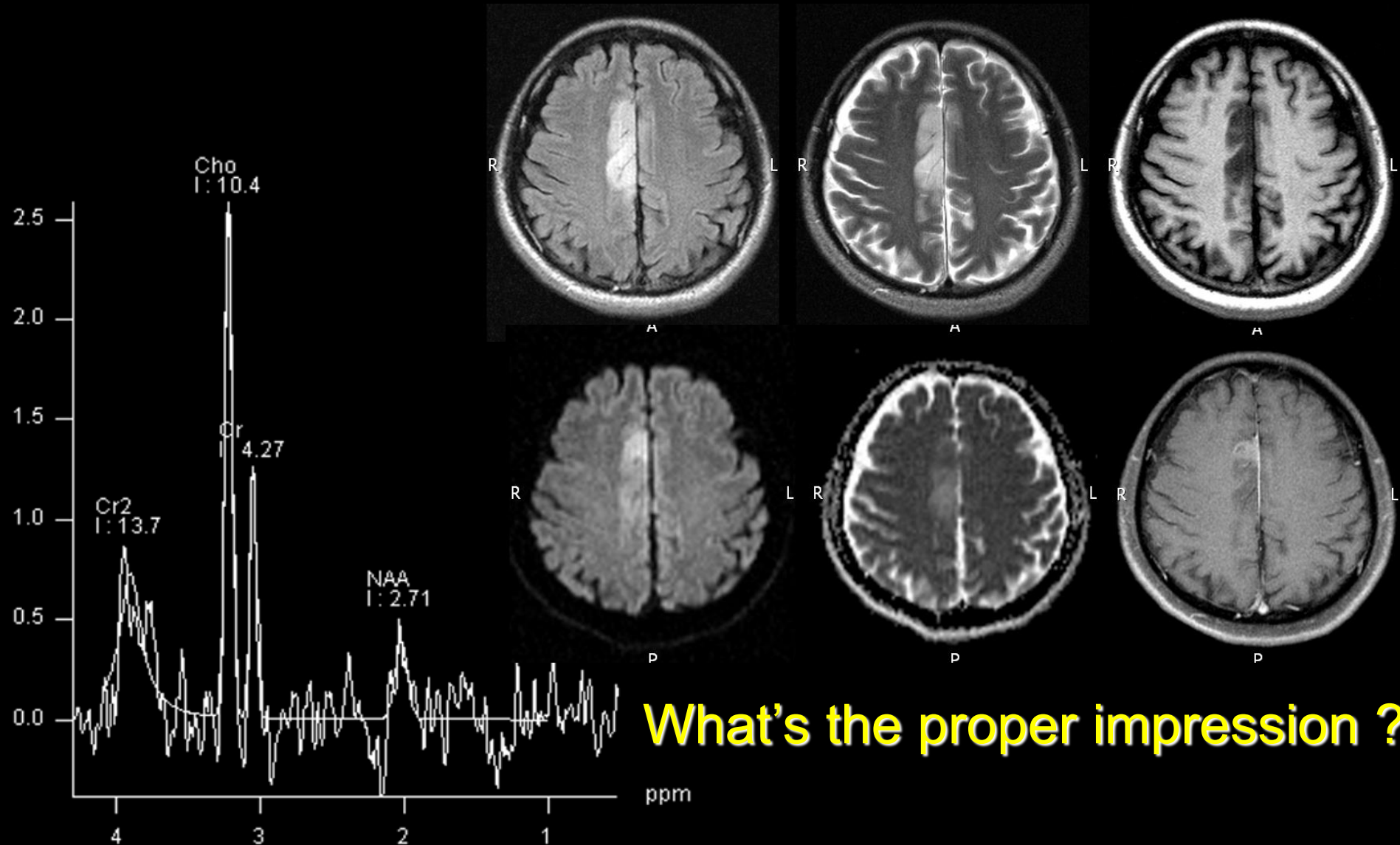
What's the proper impression ?





Transient global amnesia

**Q7** 60 Y/O Male seizure, left sided weakness

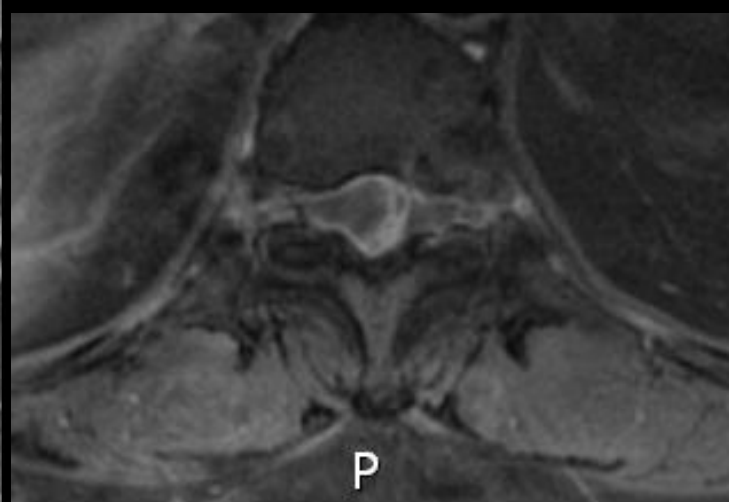
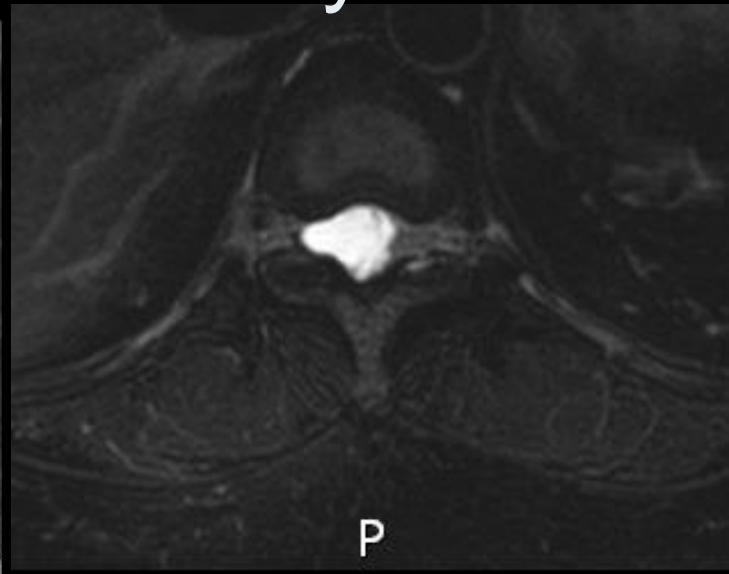
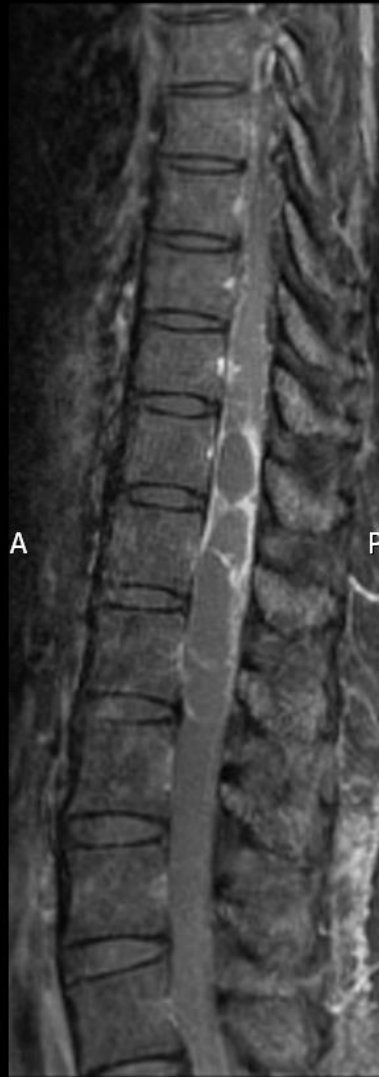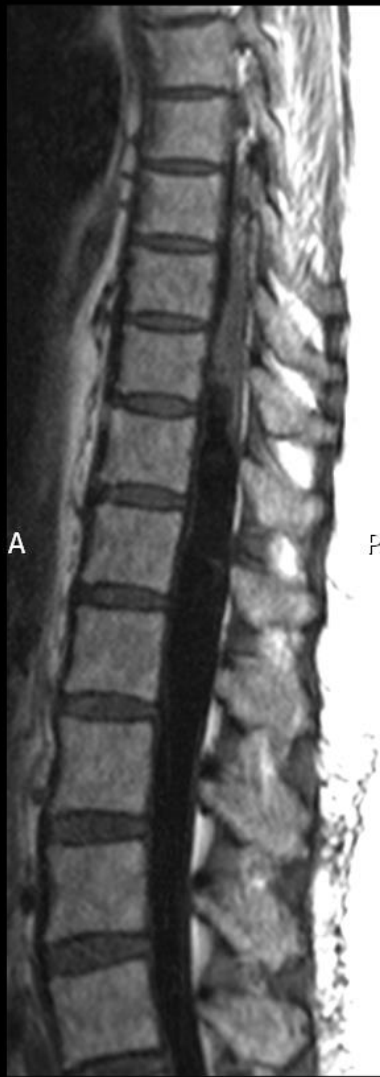
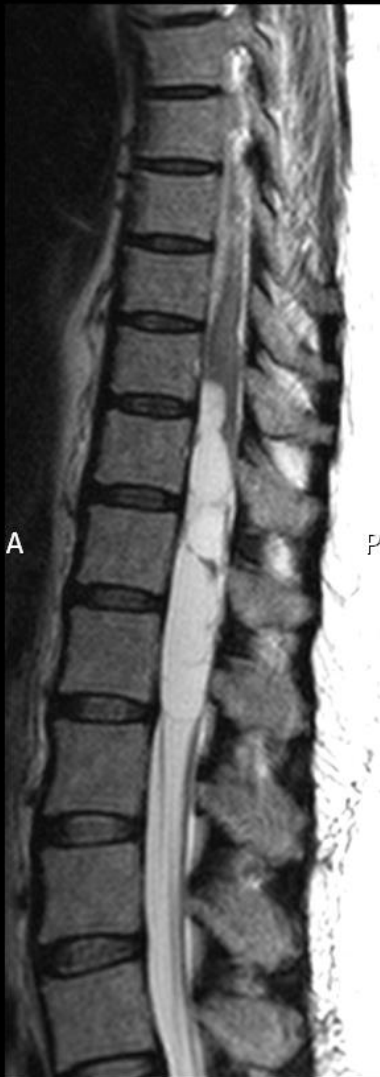


**What's the proper impression ?**

Glioblastoma, WHO grade IV

Q8

50 Y/O Female Both legs weakness  
and numbness for half a year

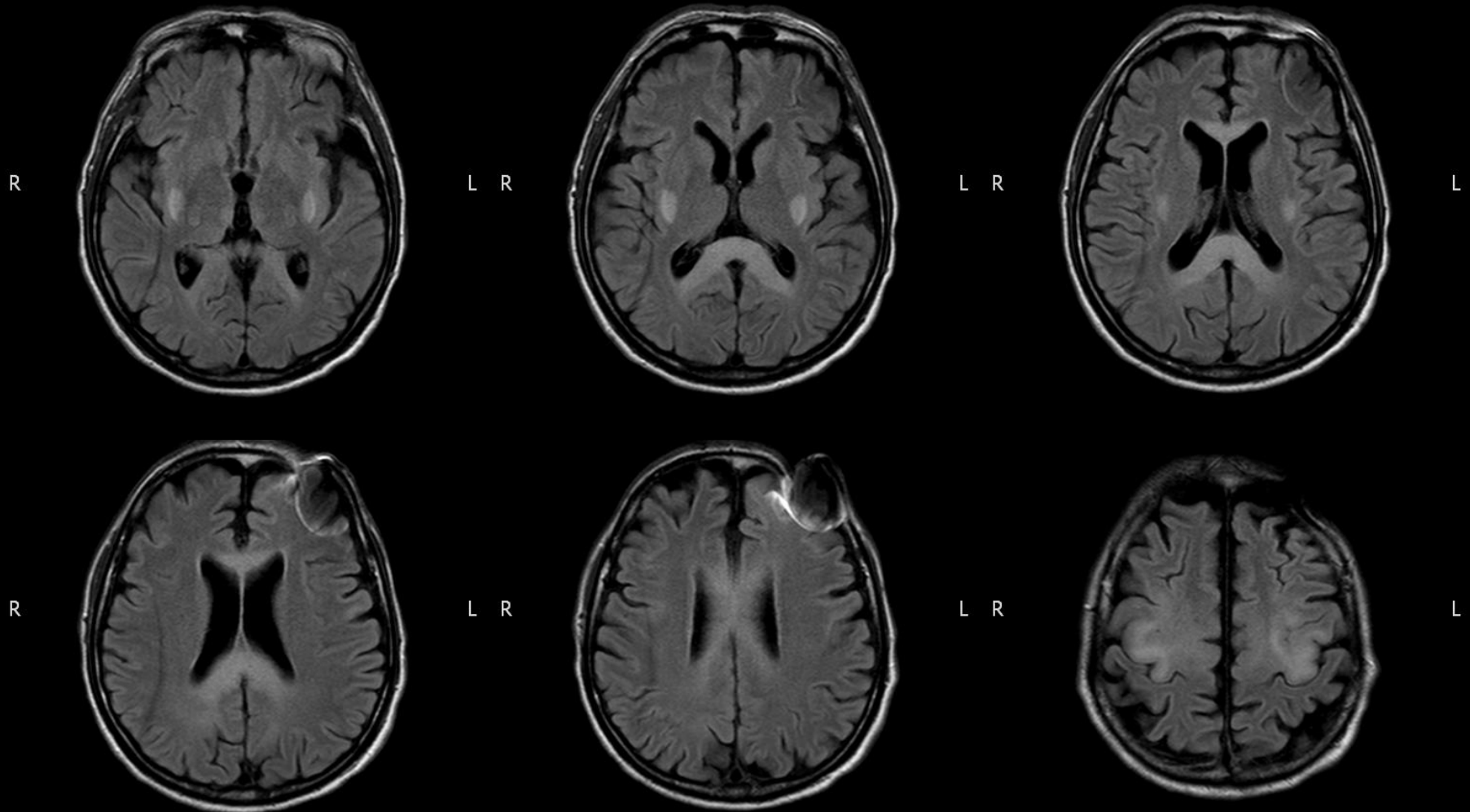


What's the proper impression ?

# Neurilemmoma

Q9

53 Y/O alcoholic male with sepsis,  
consciousness disturbance



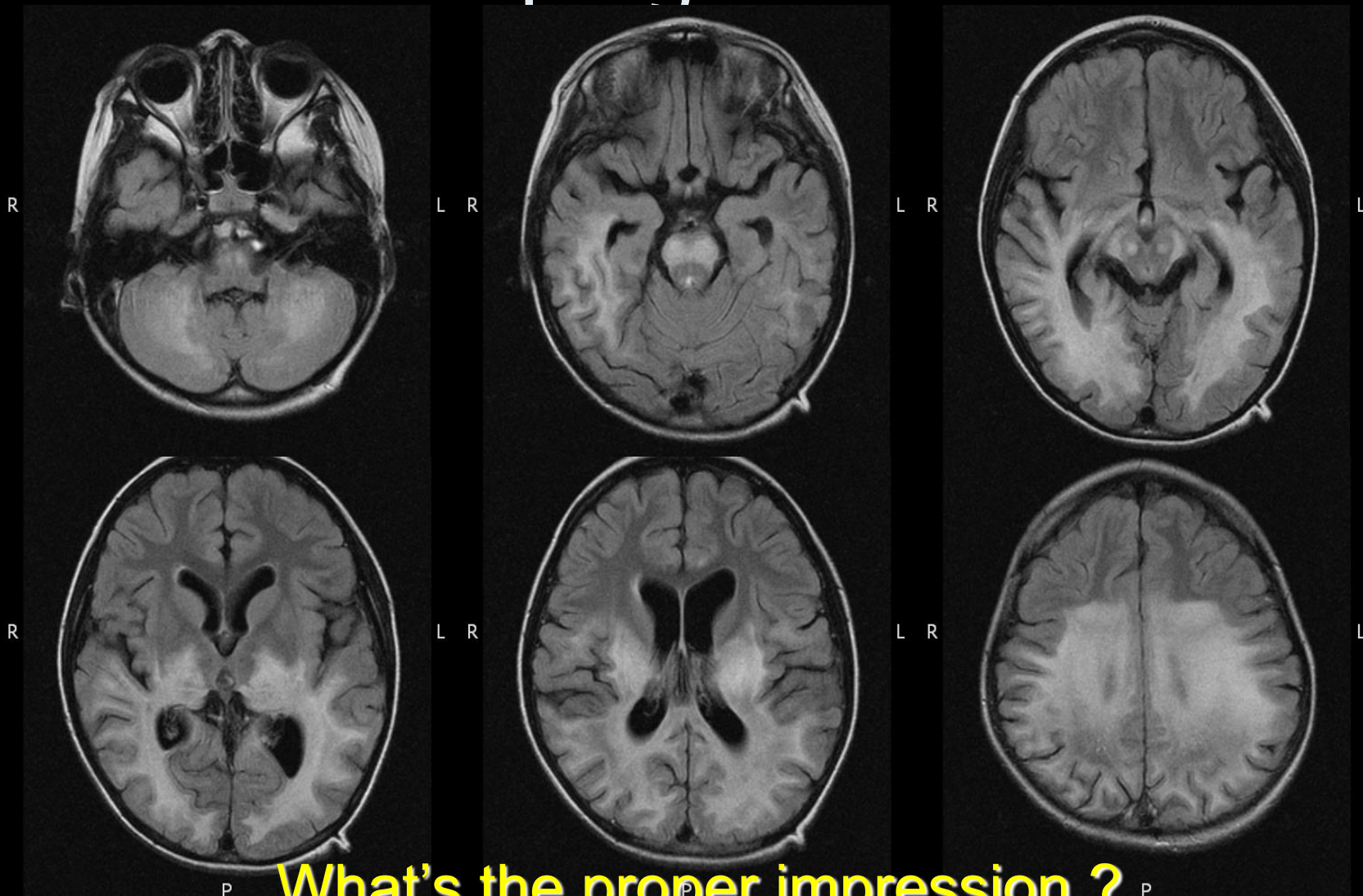
What's the proper impression ?

Marchiafava-Bignami disease



Q10

6 Y/O boy, behavioral difficulties  
and progressive ataxia



What's the proper impression ?



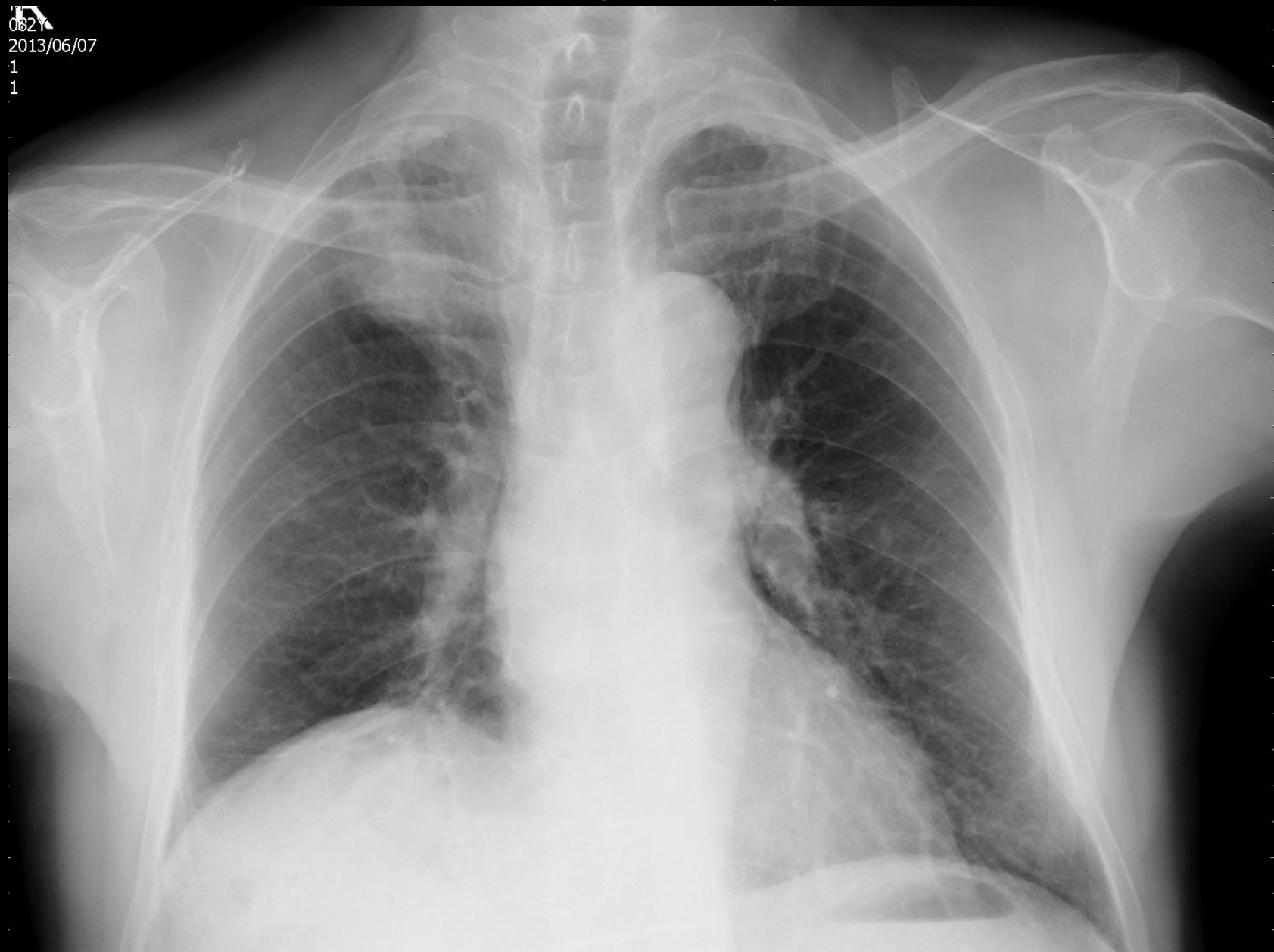# X-Linked Adrenoleukodystrophy

Q11-A

性別：male

年齡：79

主訴或重要病史或物理檢查：history of NPC (T2N2cMx) Post  
R/T(991228: 7000 cGy to primary)

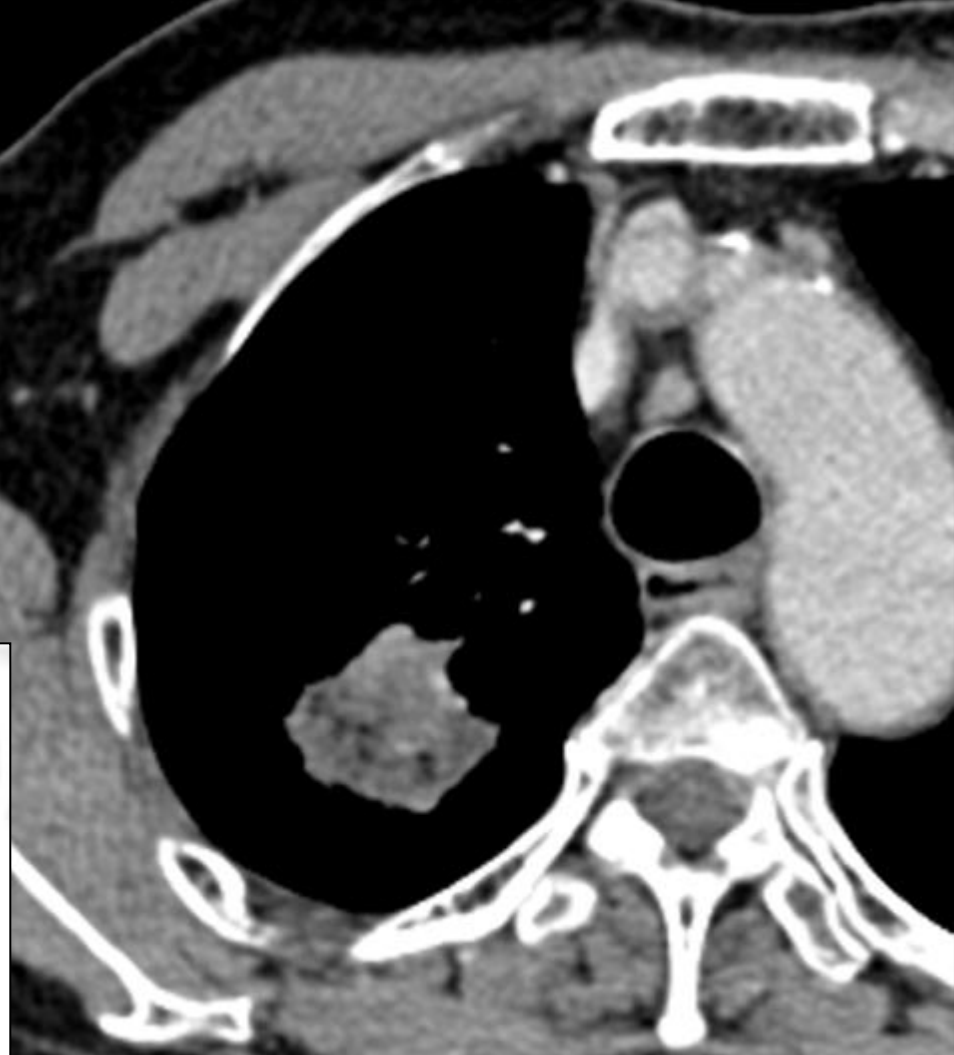
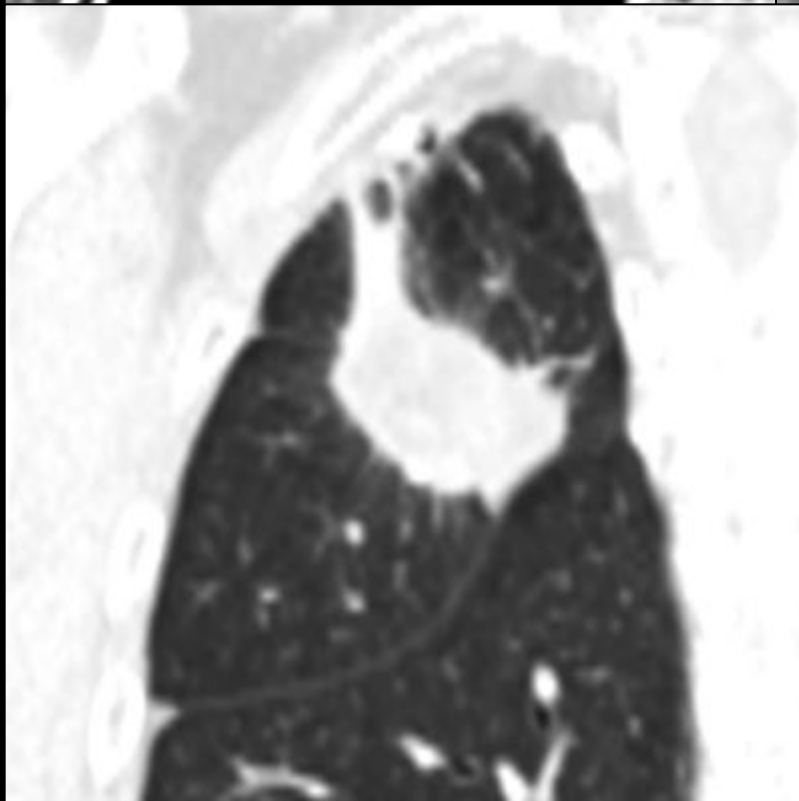
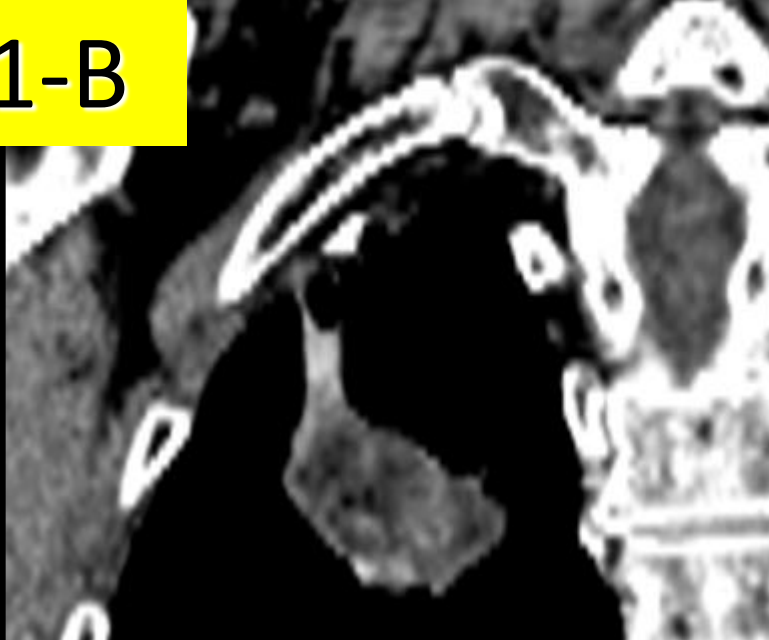


0821  
2013/06/07  
1  
1

本題有二張投影片，第一張

## Q11-B

本題有二張投影片，第二張



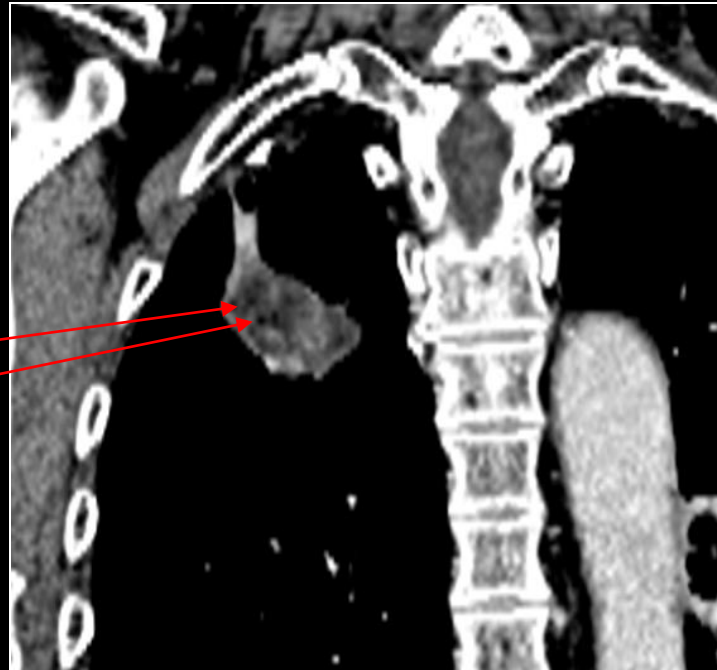
What's the proper impression?

## Chronic lipoid pneumonia

A 3x2cm hypodense mass at apical segment of RUL, is considerable for chronic lipoid pneumonia because of the presence of negative attenuation values (-40~-50 H.U) within areas of consolidation. It means some fatty component within the lesion.

-40~-50 H.U

Using paraffine for dryness  
of nasopharyngeal mucosa



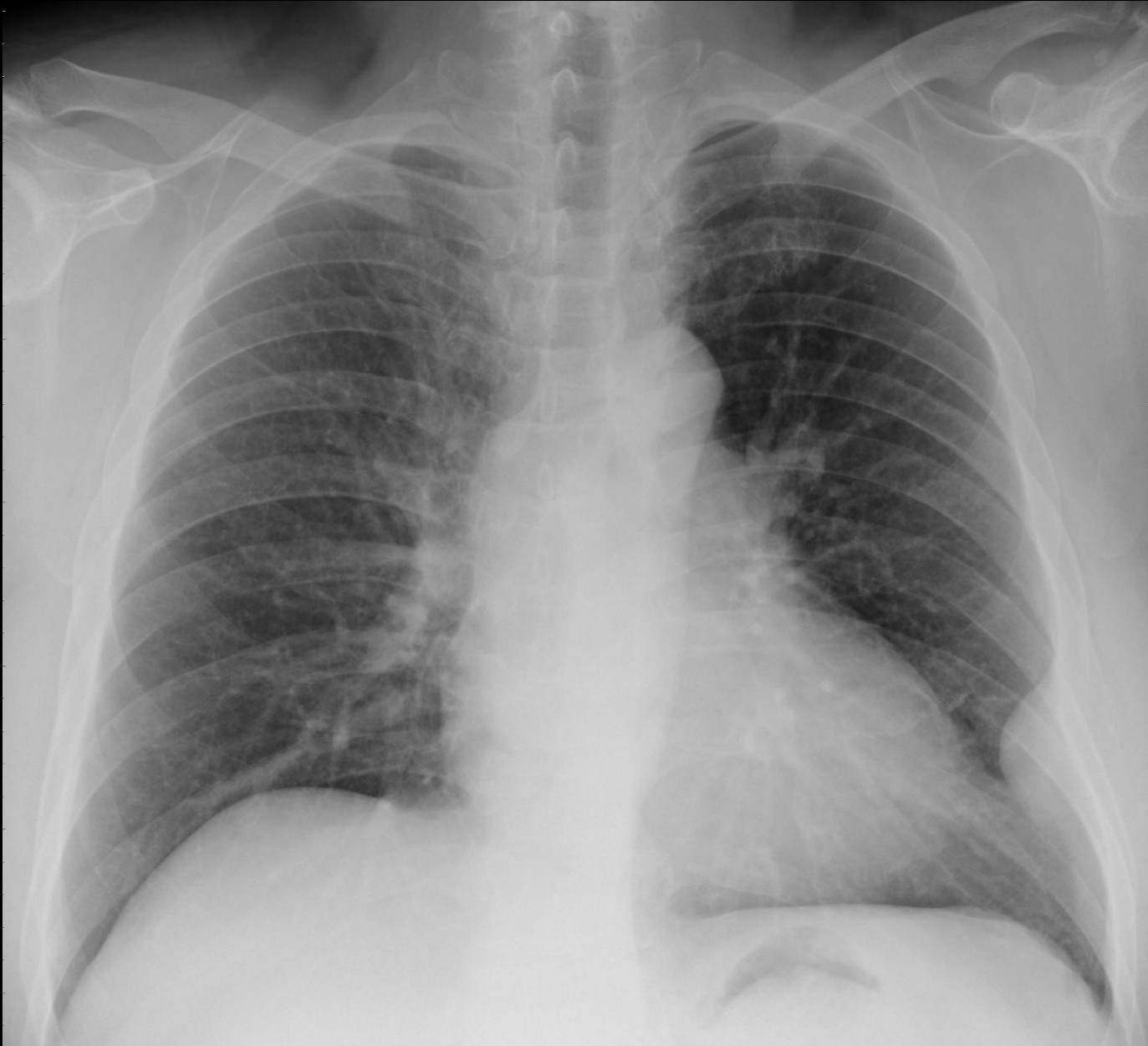
**Q12-A**

性別：**male**

年齡：**59**

主訴或重要病史或物理檢查：Left chest pain for 2 months

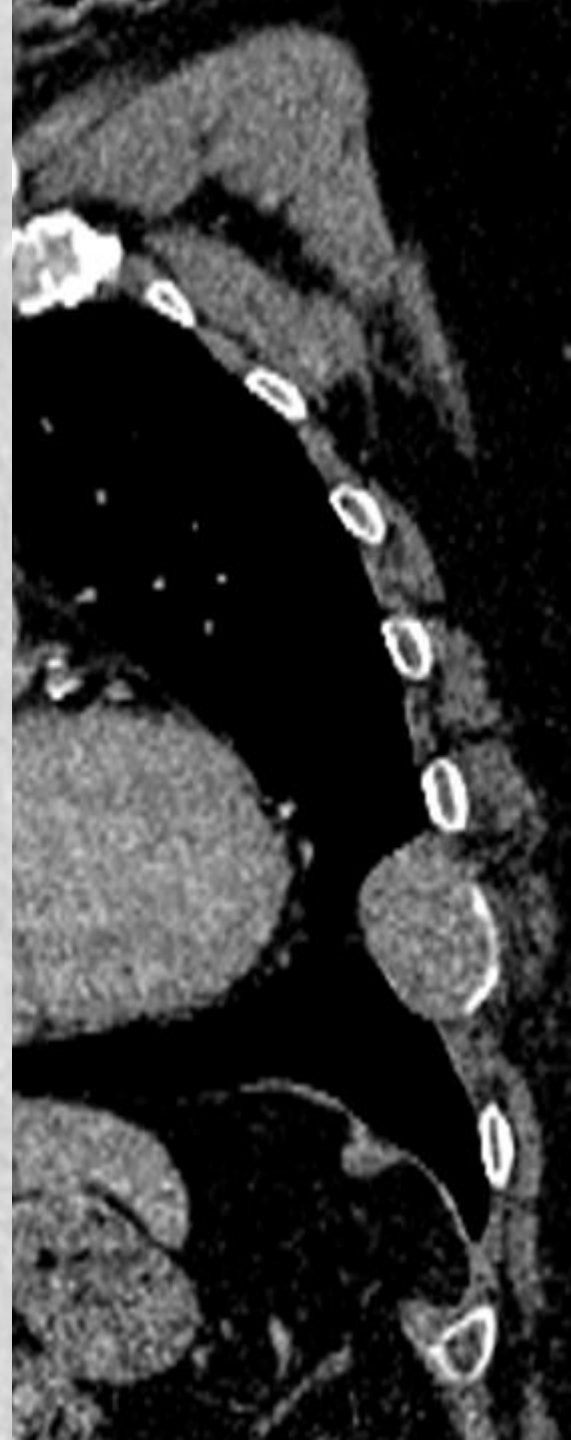
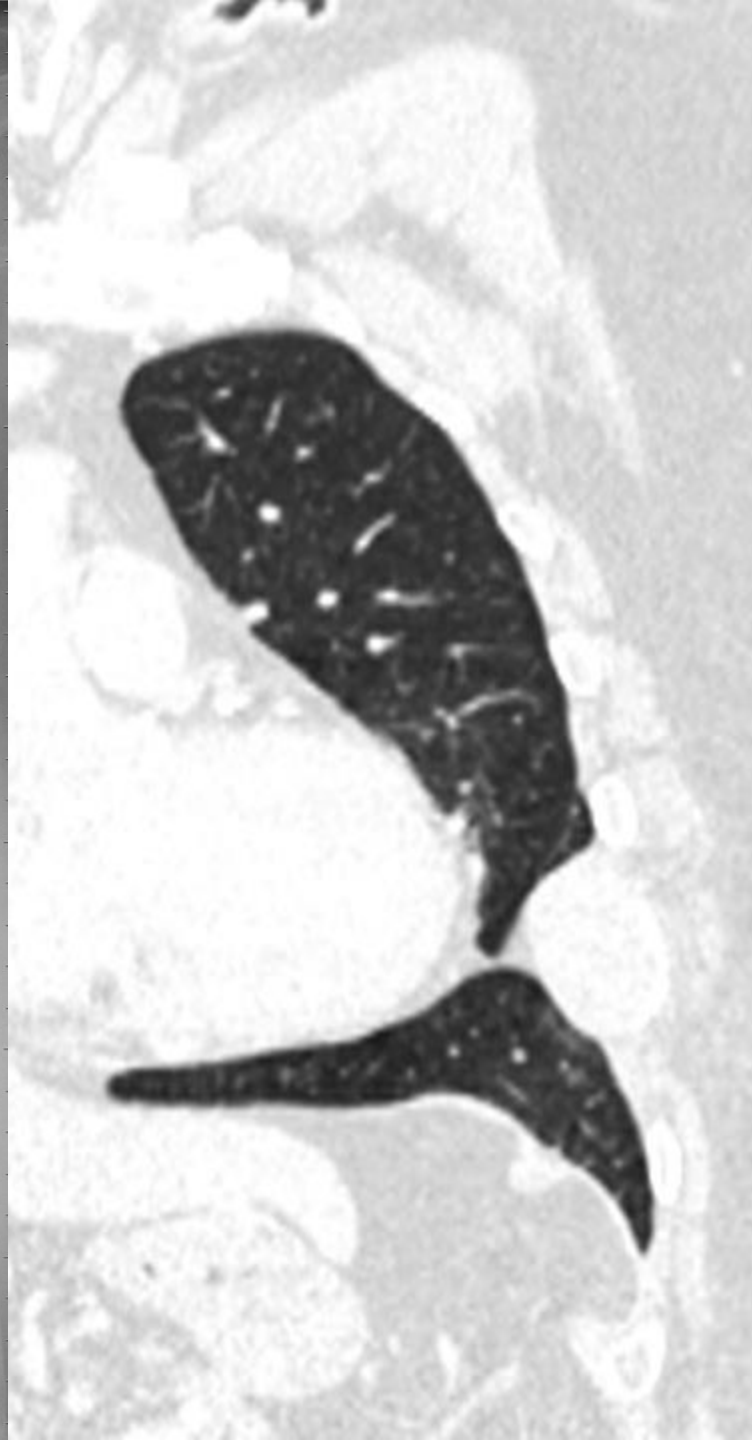
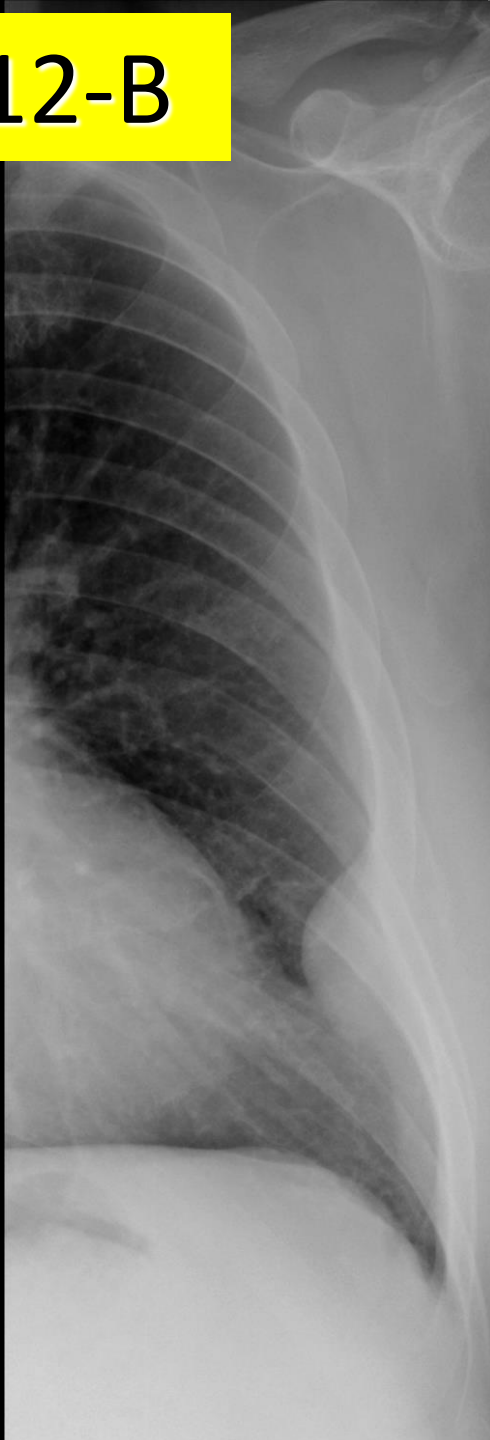
本題有三張投影片，第一張





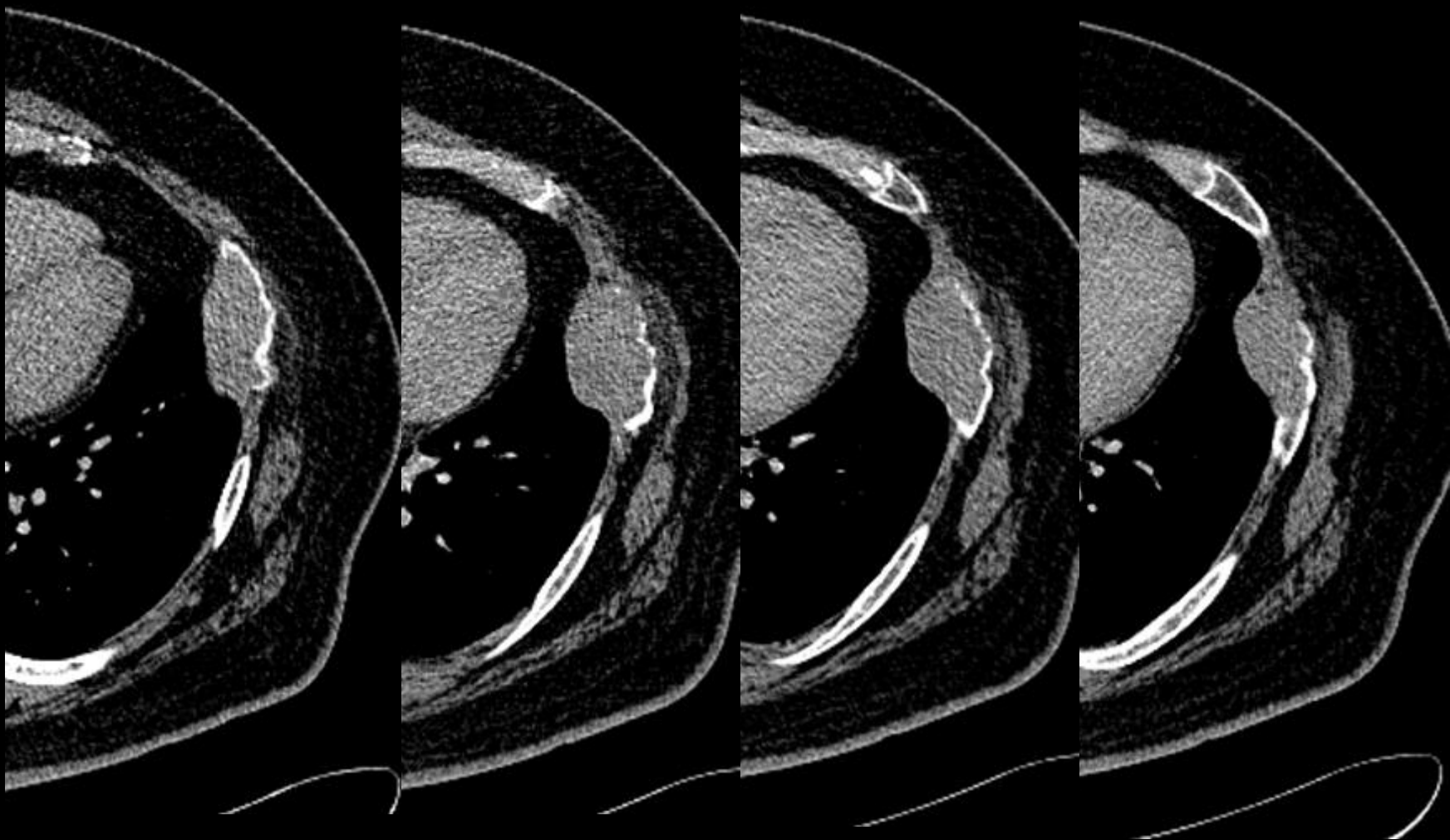
Q12-B

本題有三張投影片，第二張



## Q12-C

本題有三張投影片，第三張



What's the proper impression ?

## “Solitary bone plasmacytoma ”

A well defined fusiform soft tissue mass about 4.2x3.0x6.0cm involving the inner chest wall with destruction of the inner cortex of left 7th rib and inward extension to compress the lung with a smooth interface. The mass appears to have homogeneous enhancement and preserve the outer cortex of the involved rib, highly suggestive of a chest wall tumor, likely a "solitary bone plasmacytoma ".

Bone marrow, iliac, needle biopsy, plasma cell myeloma.



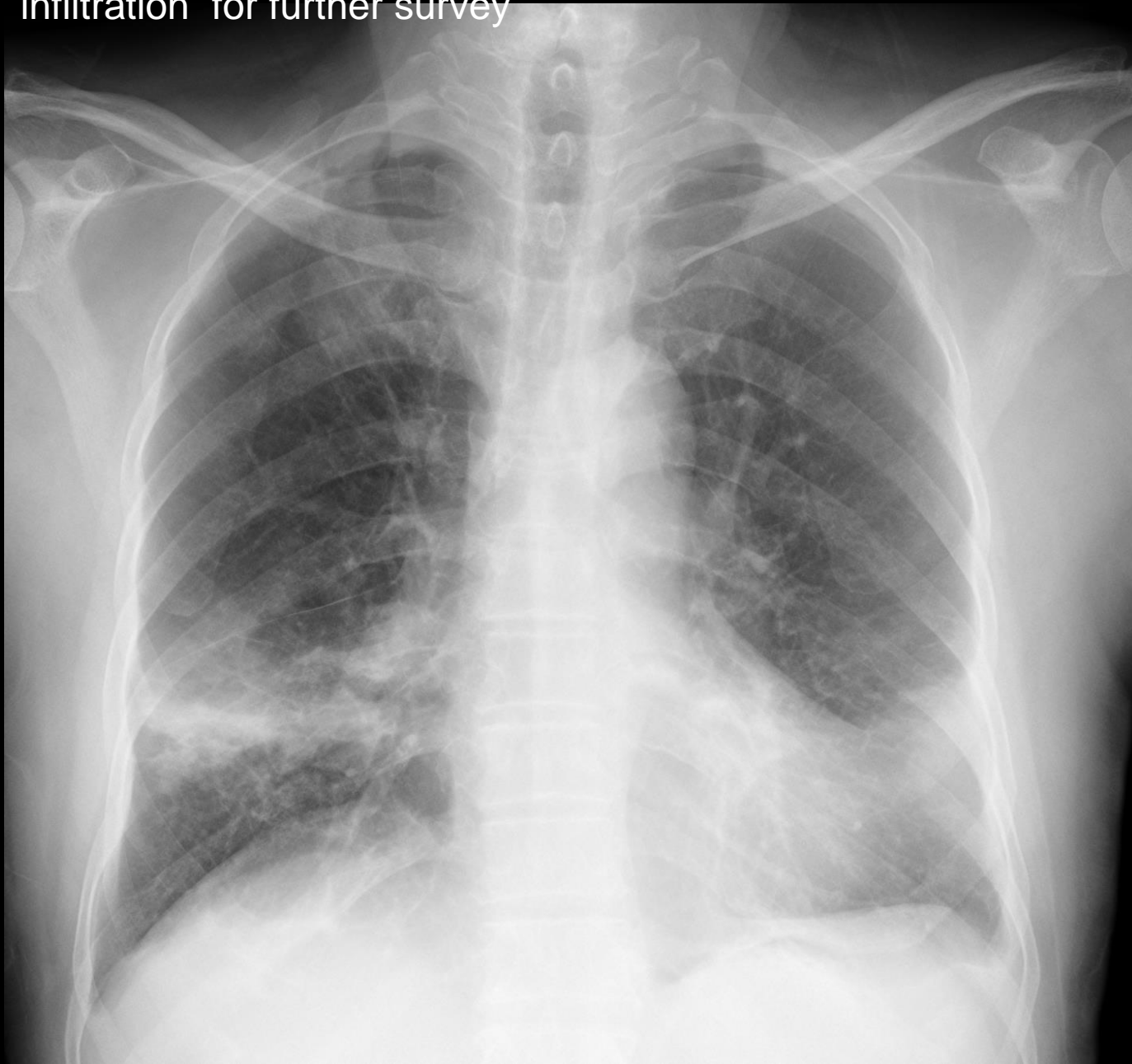Q13-A

性別：male

年齡：66

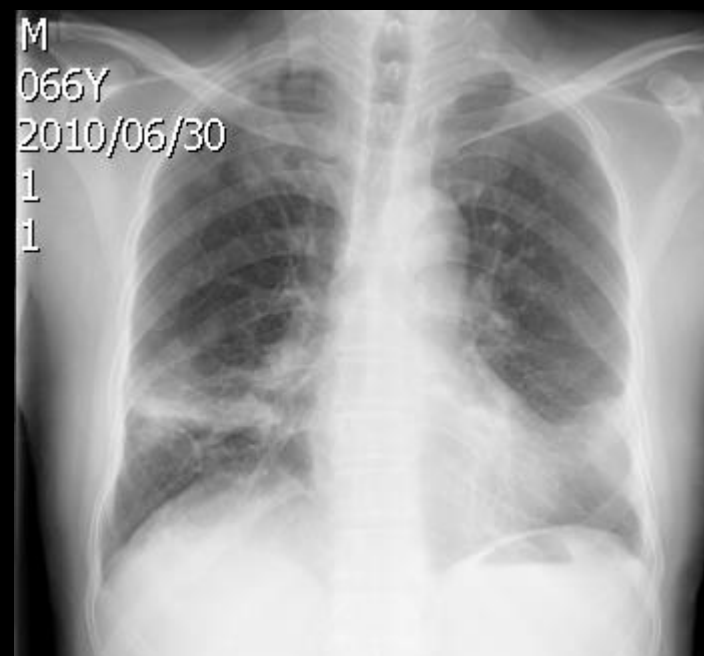
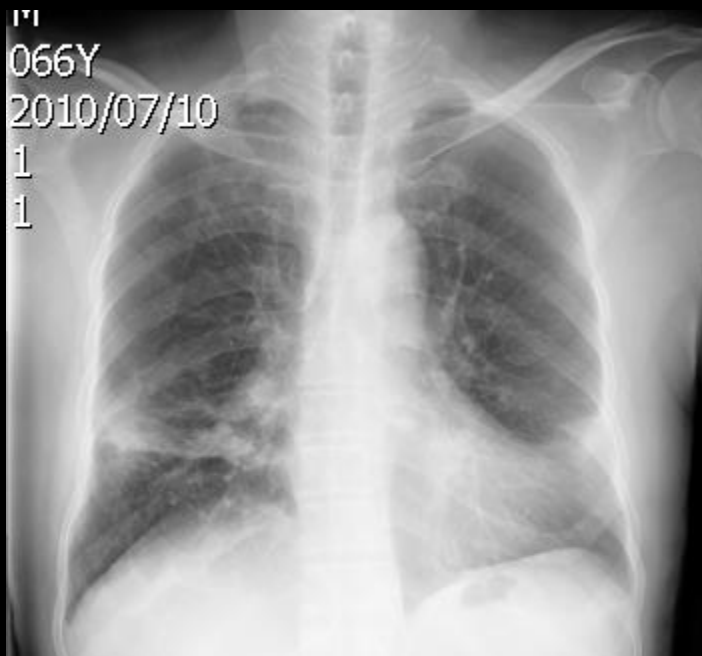
主訴或重要病史或物理檢查：Poorly improved bil. lower lung infiltration for further survey

本題有三張投影片，第一張

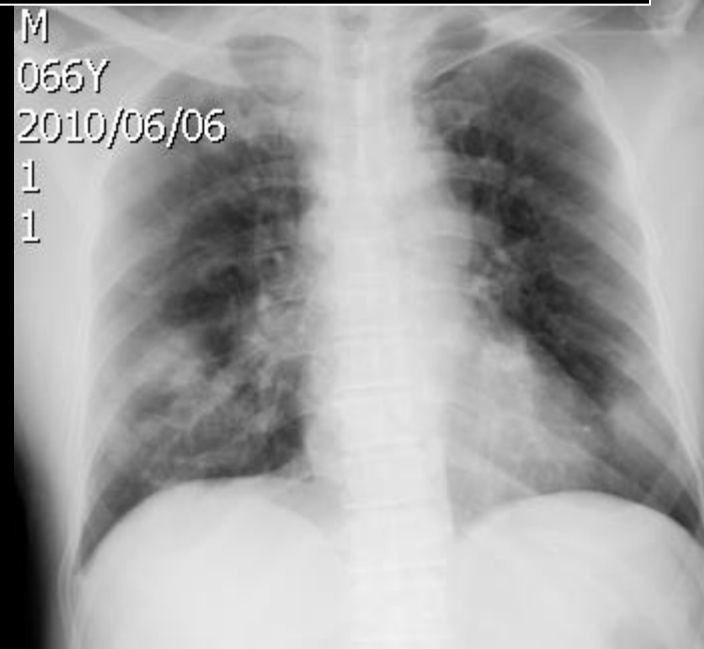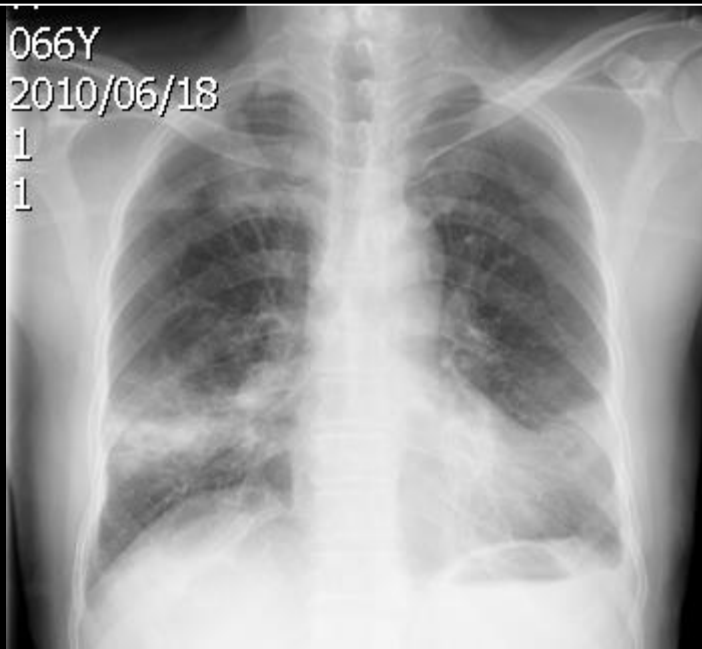


# Q13-B

本題有三張投影片，第二張

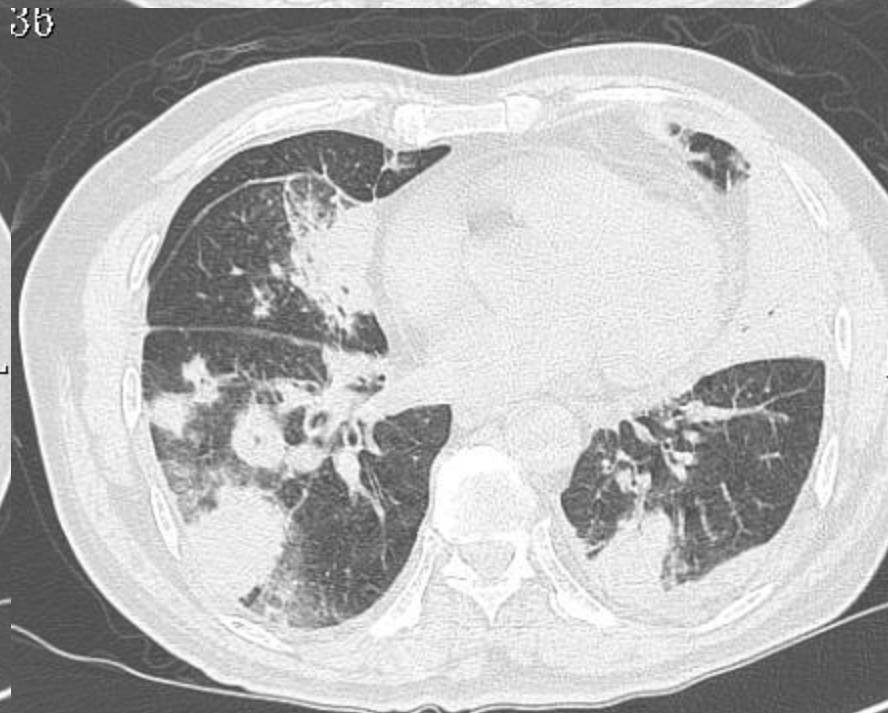
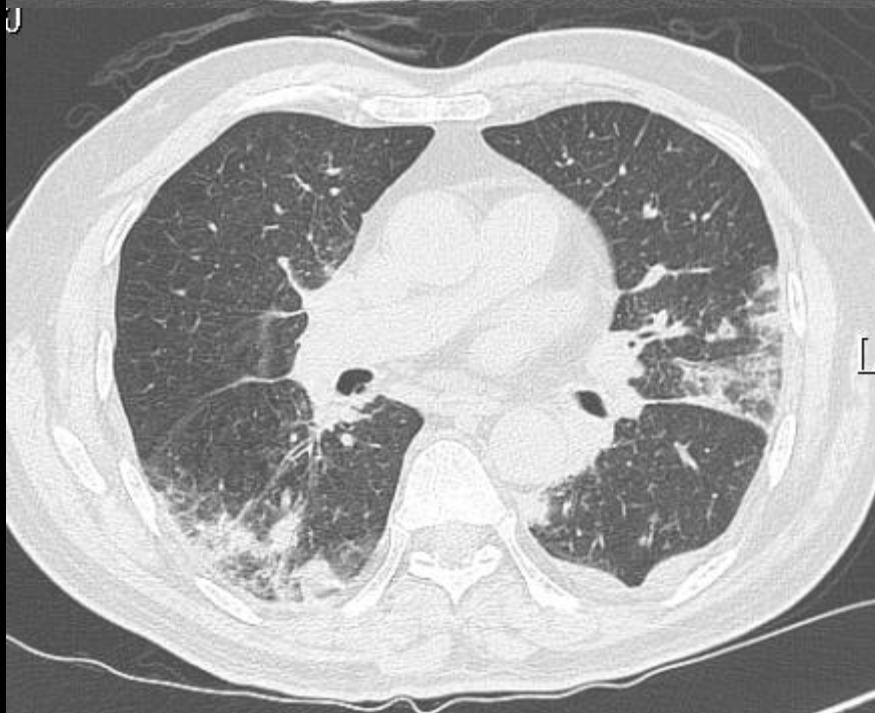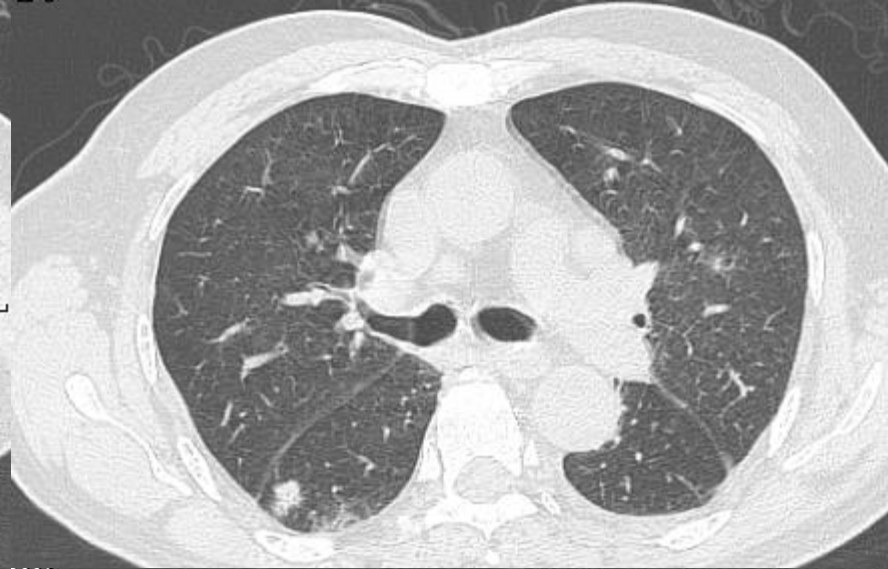

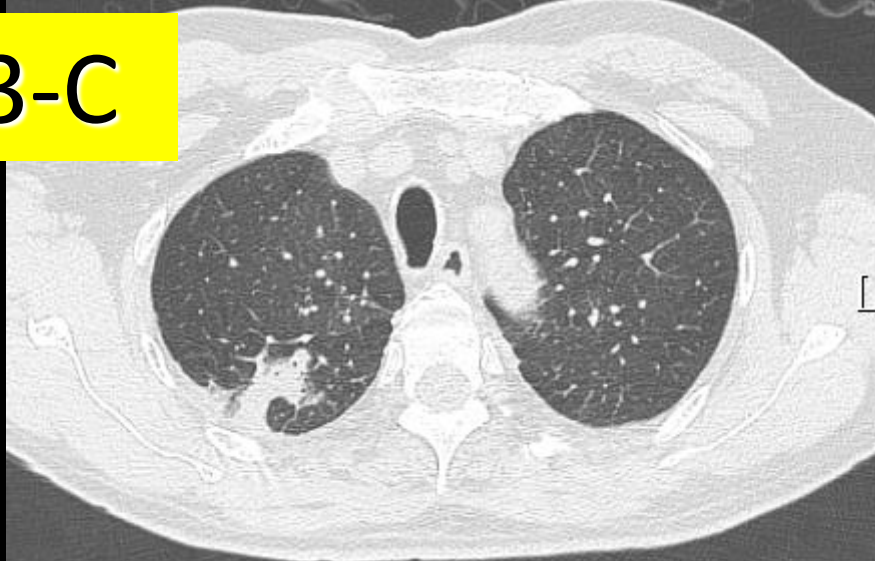
Poorly improved bil. lower lung infiltration for 5 weeks



# Q13-C

本題有三張投影片，第三張



What's the proper impression ?

## Cryptogenic organizing pneumonia

Multiple lobular and segmental pneumonic consolidations with cavitation as well as surrounding ground glass edge seen in the peripheral parenchyma of RML, the lingula and bilateral lower lobes. ( asymmetry, pleura-based, lower lobe predominance)

病理報告 : Lung, RLL, wedge resection, organizing pneumonia with features of BOOP



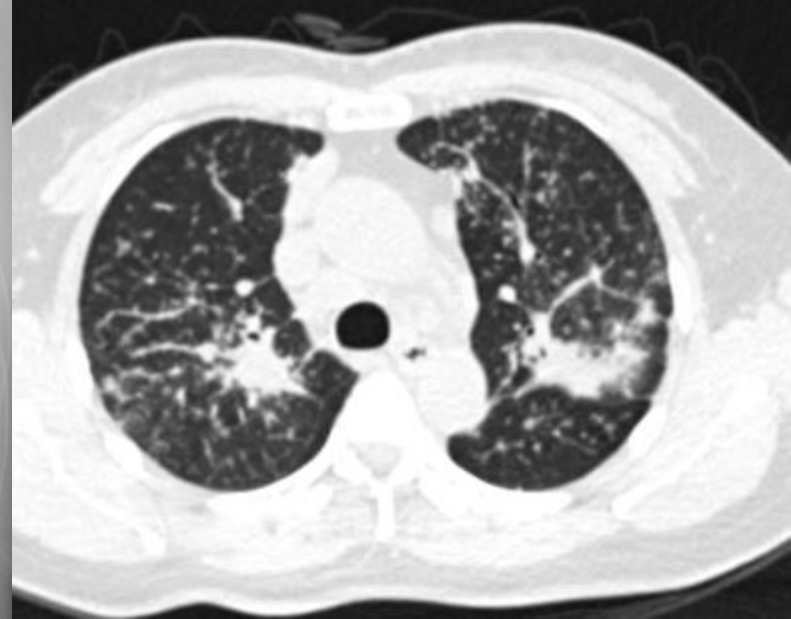
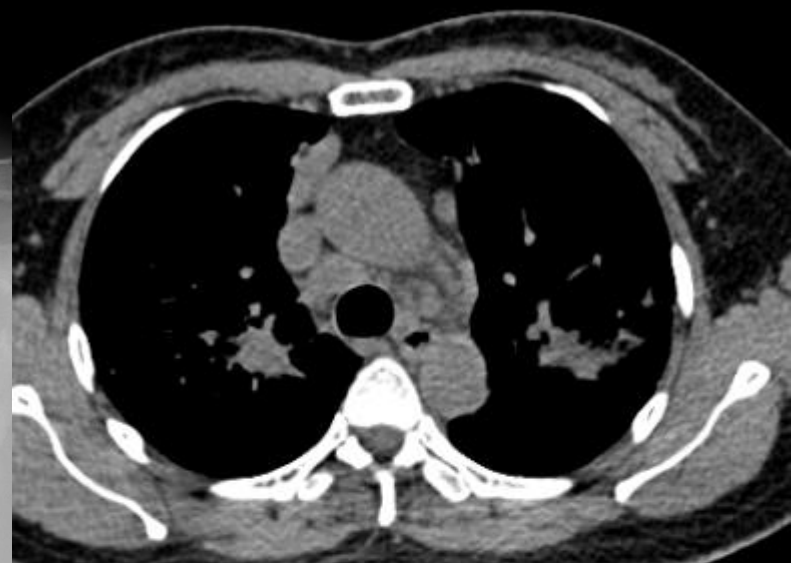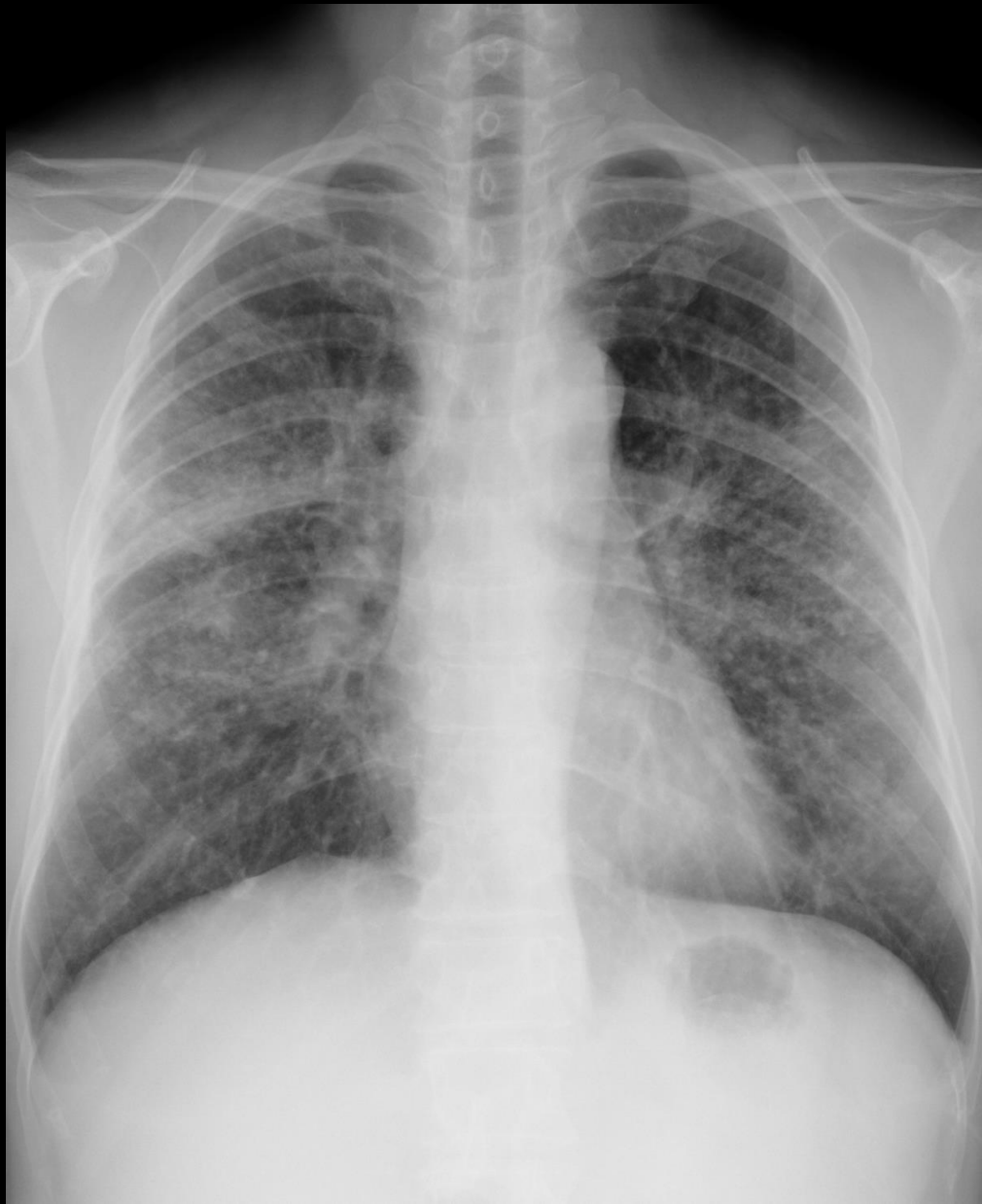Q14-A

性別：**female**

年齡：**54**

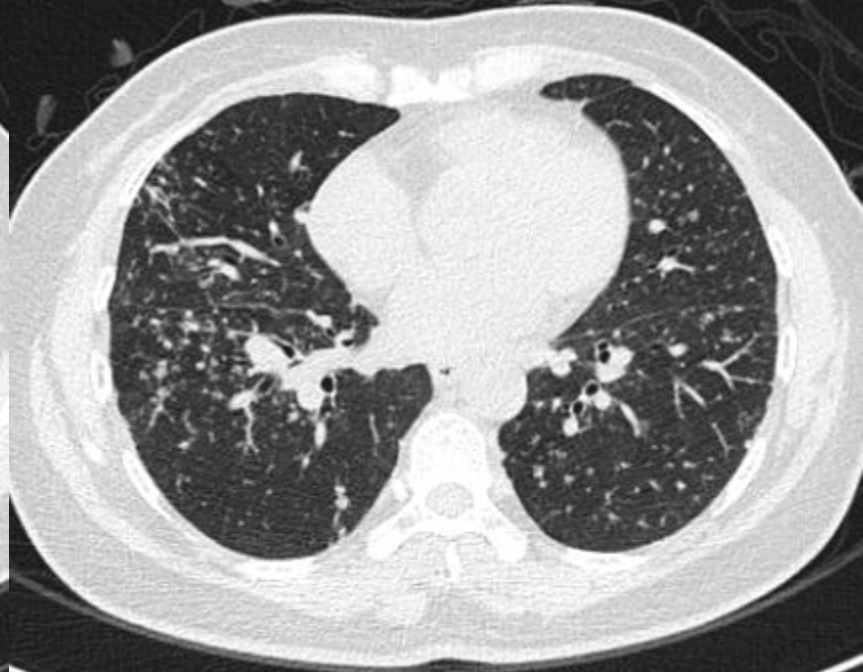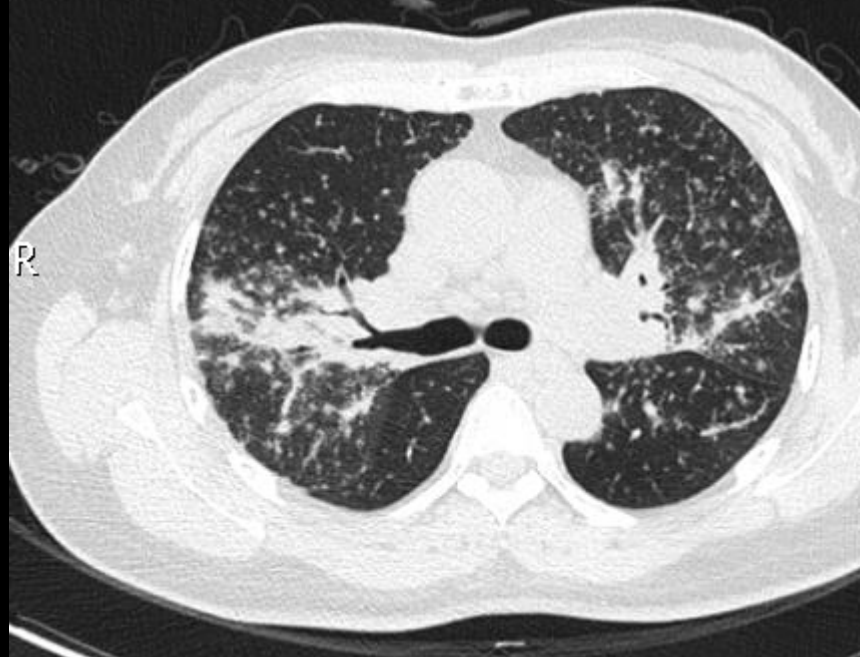
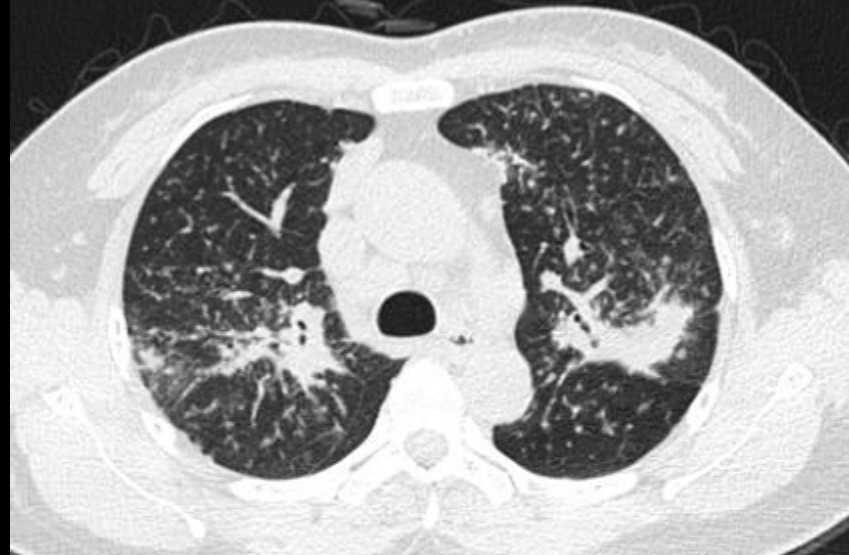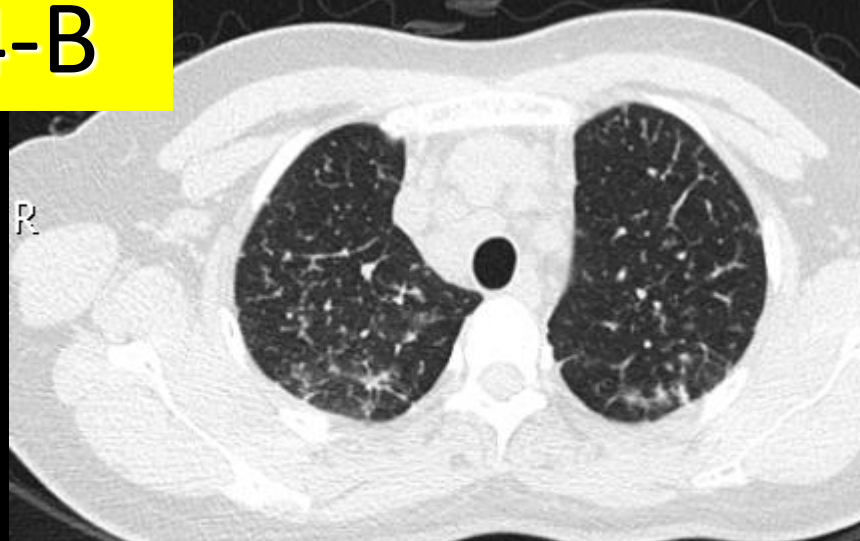主訴或重要病史或物理檢查：Cough with sputum for 2 yrs,  
SOB for 6 months, no fever, no wt loss,

本題有二張投影片，第一張



# Q14-B

本題有二張投影片，第二張



What's the proper impression ?

# Sarcoidosis stage II.

- 1) Multiple grossly enlarged LNs in left supraclavicle, paratracheal, subcarinal and bil. hilar regions indicating granulomatous lymphadenopathy, likely sarcoidosis.
- 2) Numerous micronodules along the peribronchovascular bundles and the interlobar fissures of both lungs, and two conglomerated mass lesions of bil. upper lobes are consistent with diffuse pulmonary involvement of sarcoidosis at stage II.

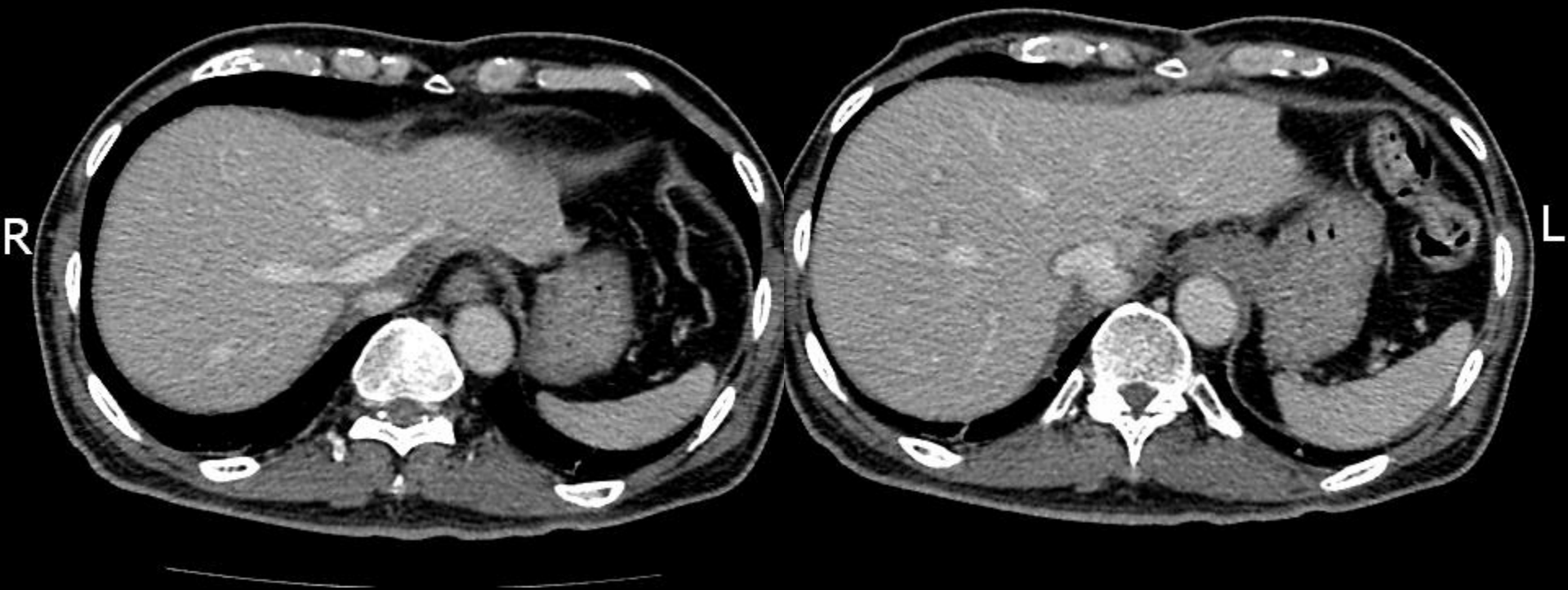**Skin biopsy: sarcoidosis**



Q15

64 Y/O M Liver transplant

What's the technique use in  
venous restoration ?

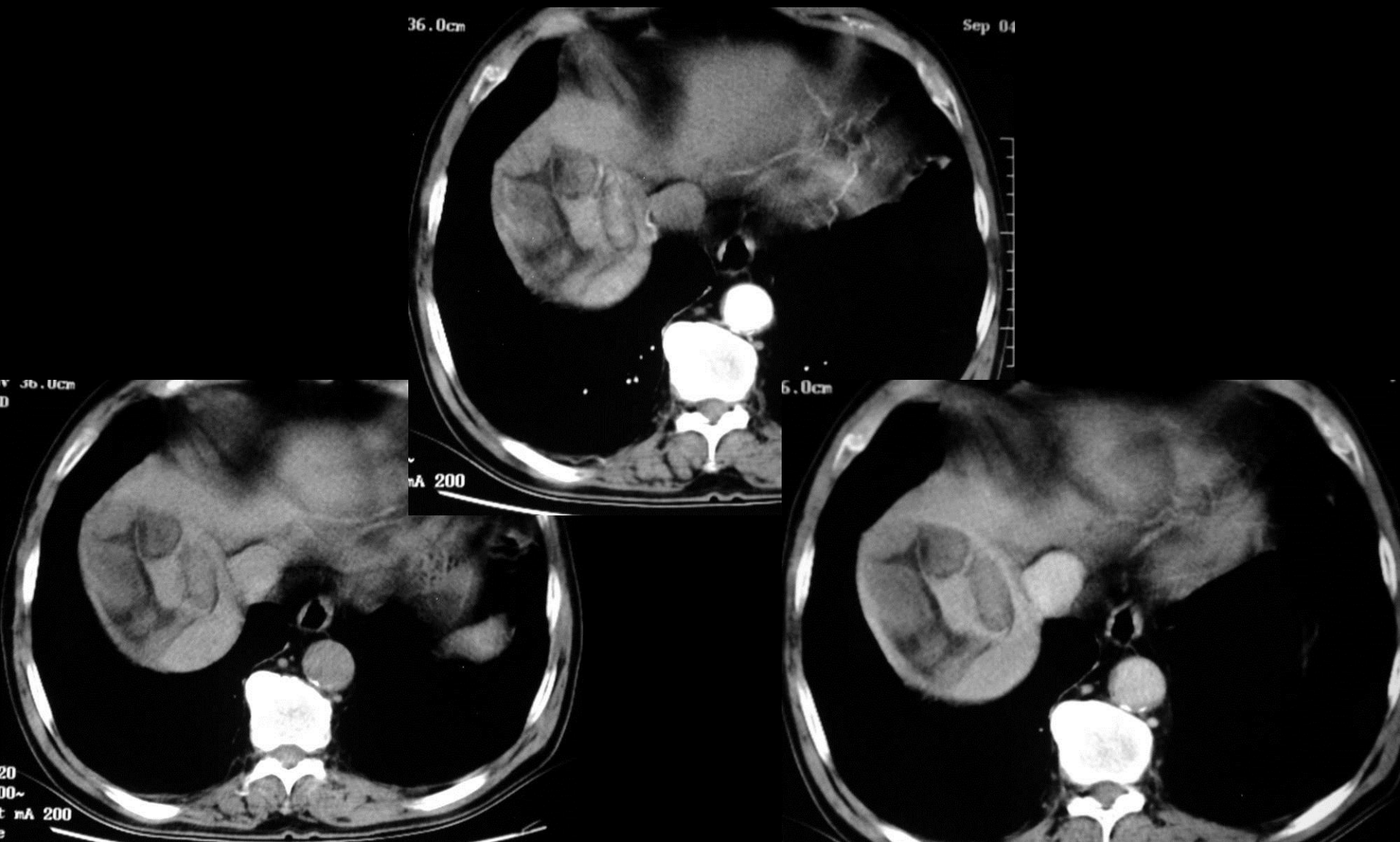




Piggy-back technique

Q16

71 Y/O Male Hepatic tumor

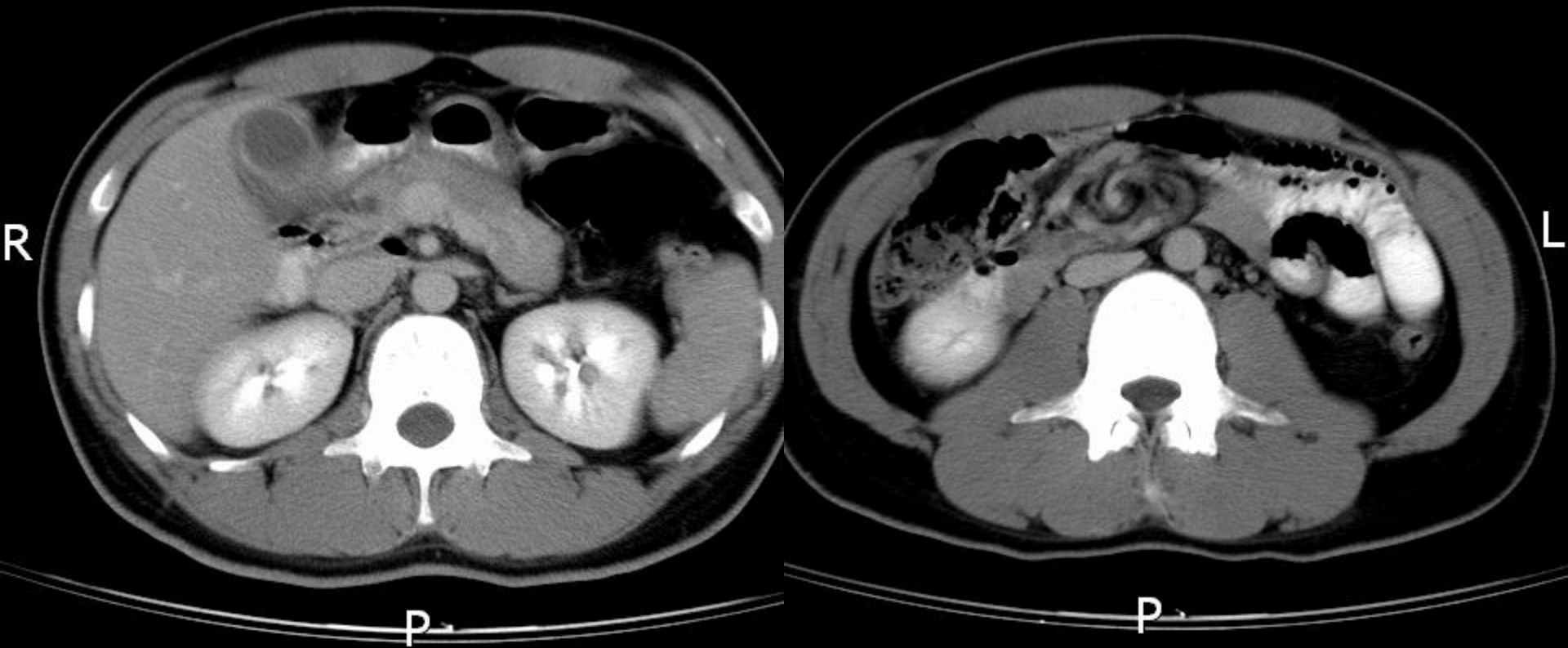


What's the proper impression ?

Fat-containing HCC

Q17

29 Y/O Male Abdominal pain



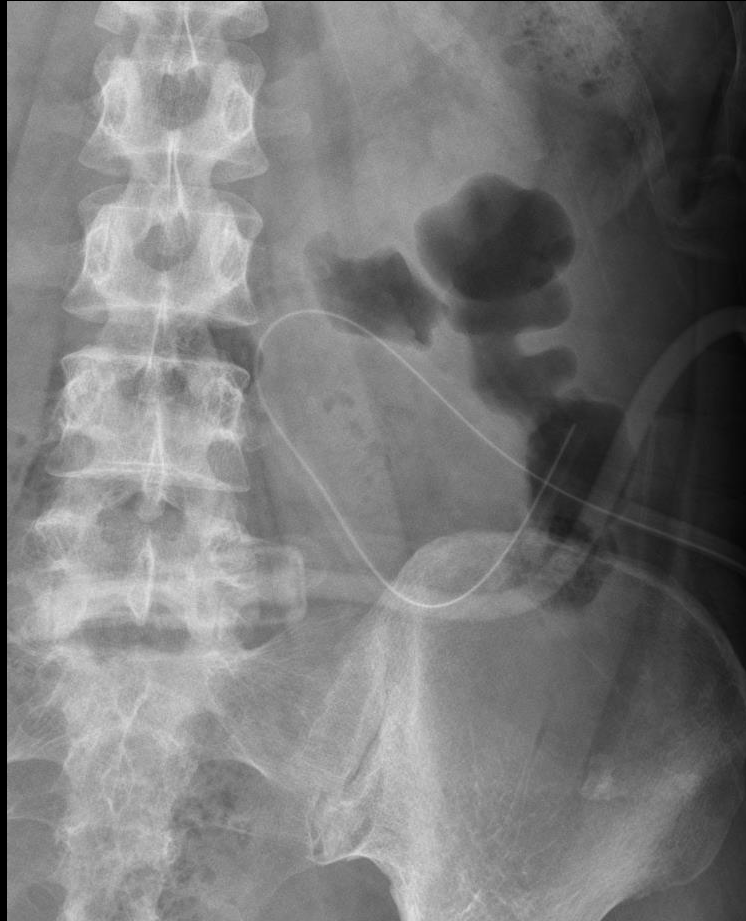
What's the proper impression ?

Mid-gut volvulus

Whirl's sign ½ point

Q18

# Uremic patient elevating BUN & Creatinine



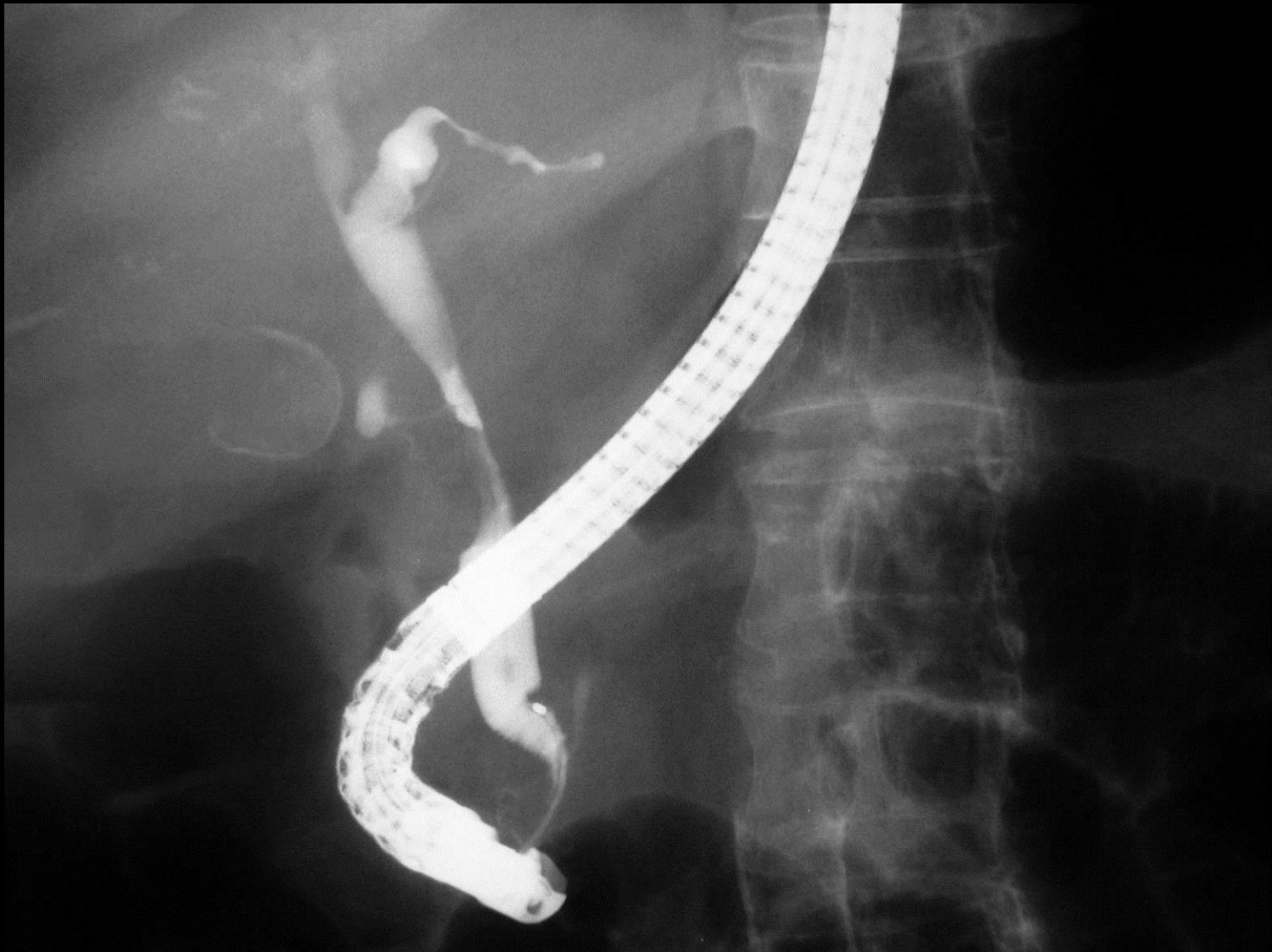**What's the proper impression ?**

CAPD catheter migration /kinking



Q19

73 Y/O F    Jaundice



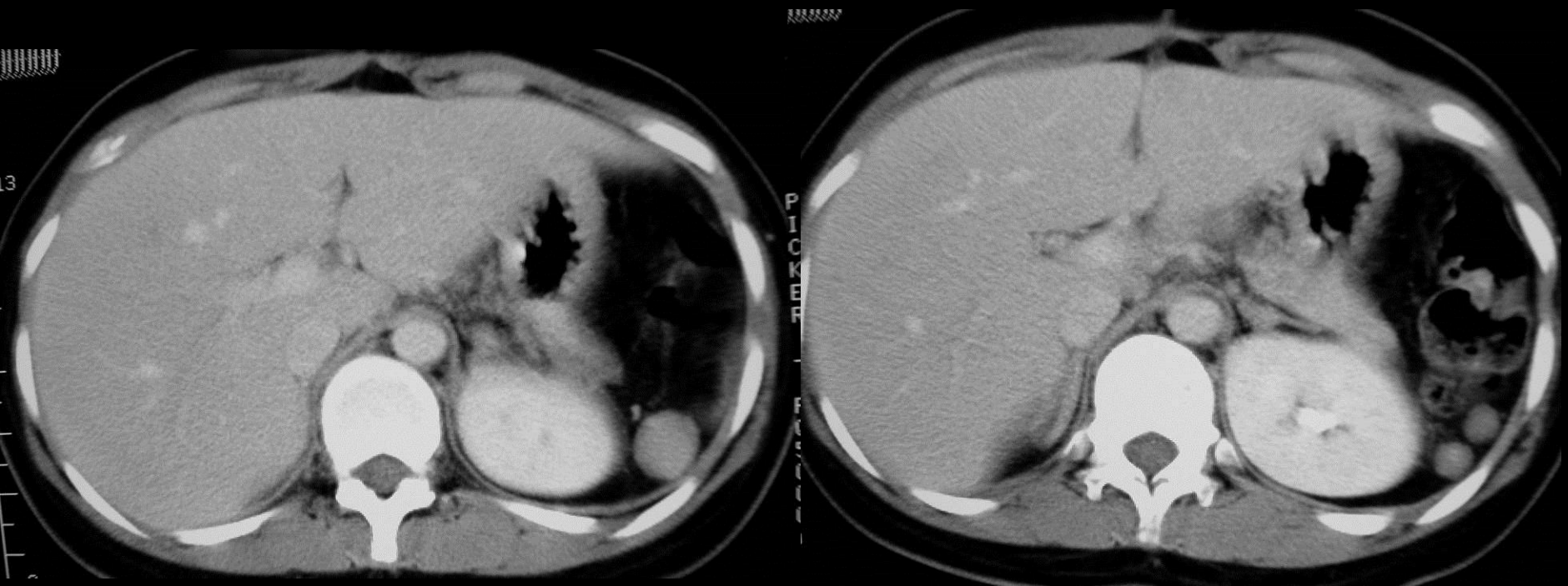
What's the proper impression ?

Mirrizzi syndrome

**Q20**

**17 Y/O Female**

**Blunt abdominal trauma s/p  
splenectomy one year ago**

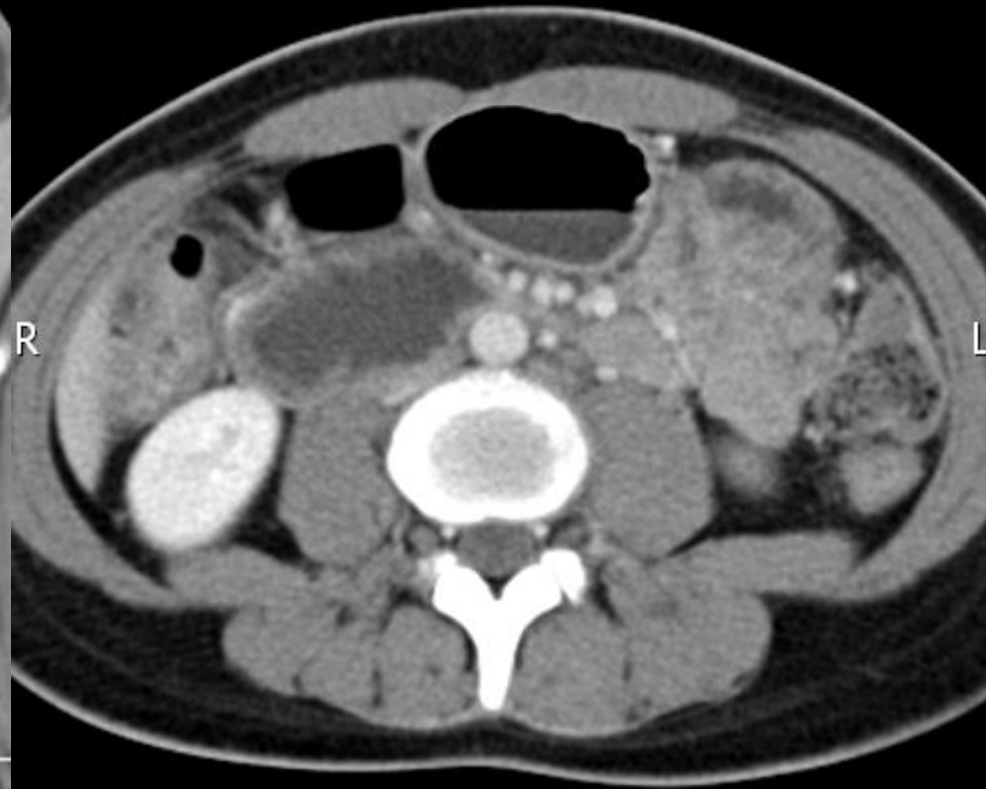
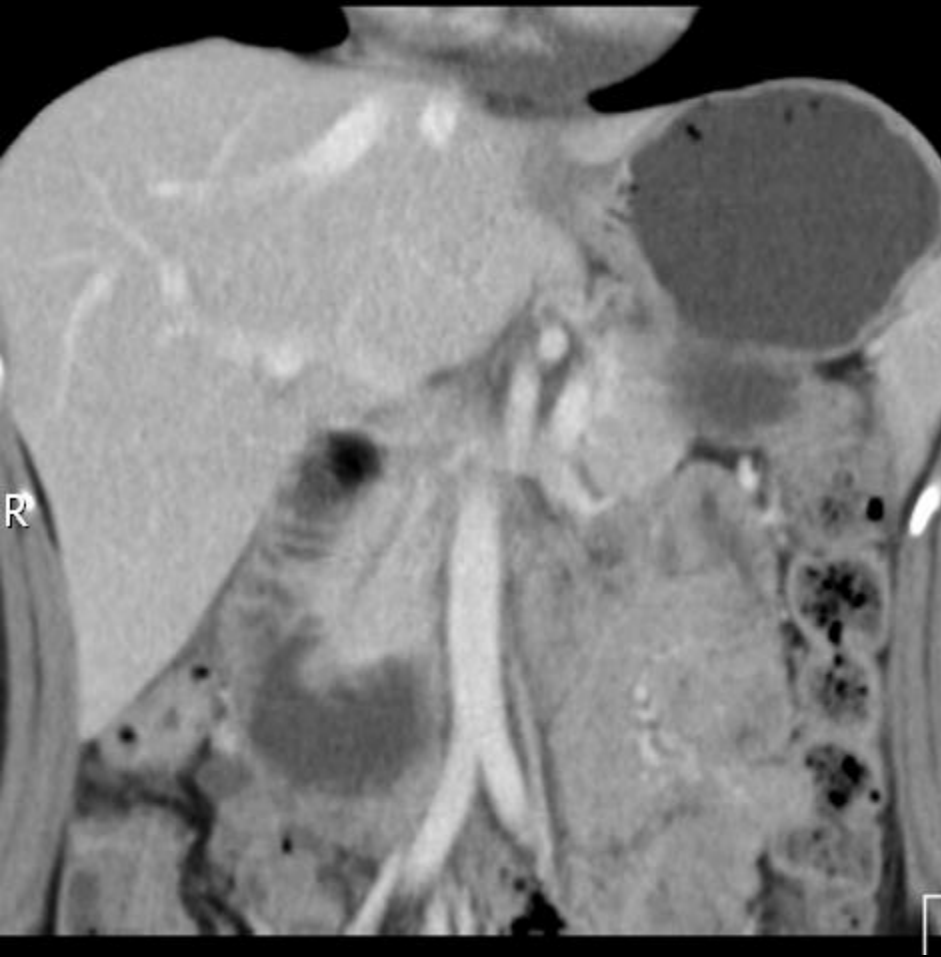
**What's the proper impression ?**

# Splenosis

Q21

27 Y/O Female upper  
abdominal fullness



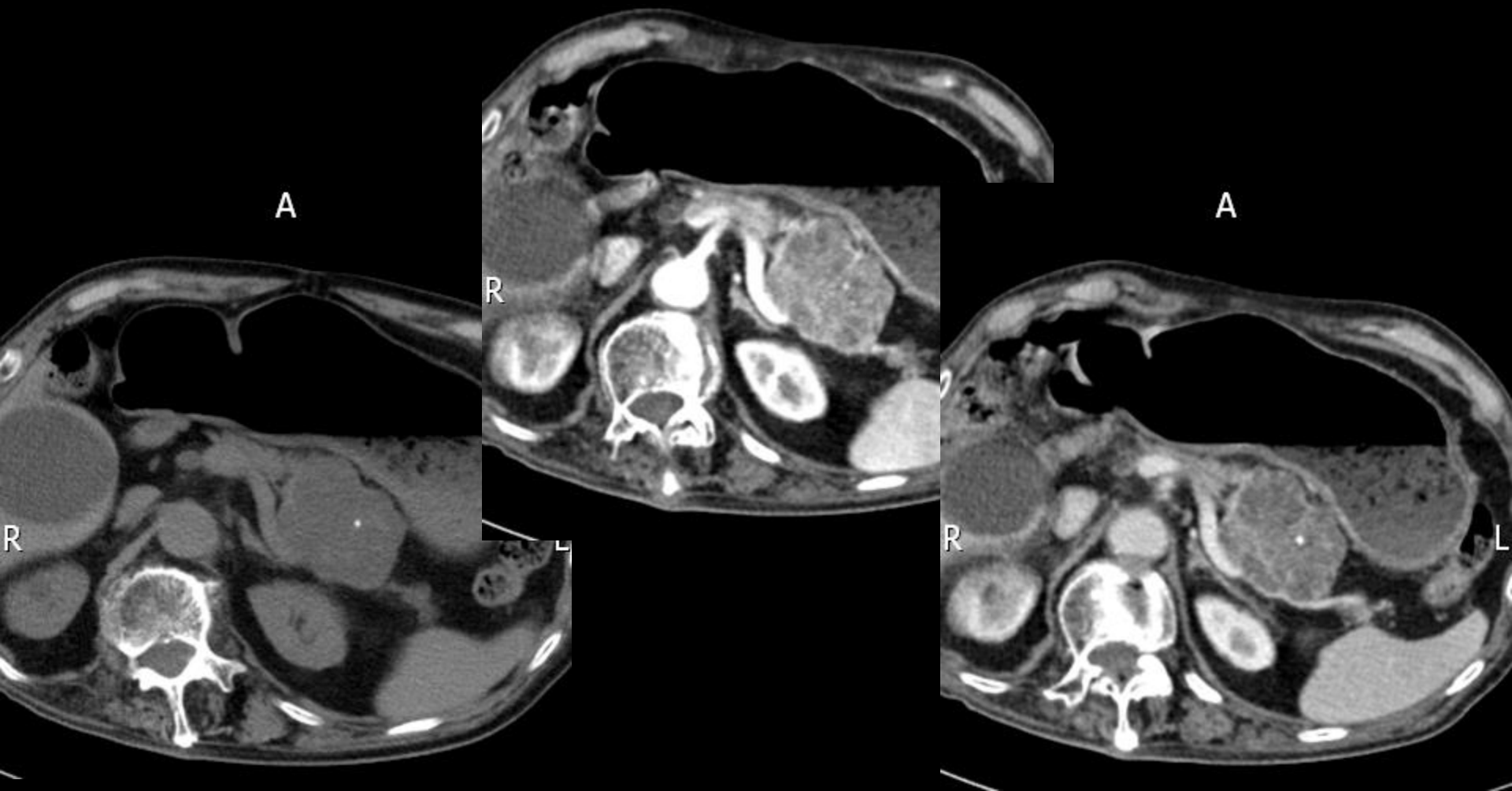
What's the proper impression ?

SMA syndrome



Q22

89 Y/O Male pancreatic  
mass



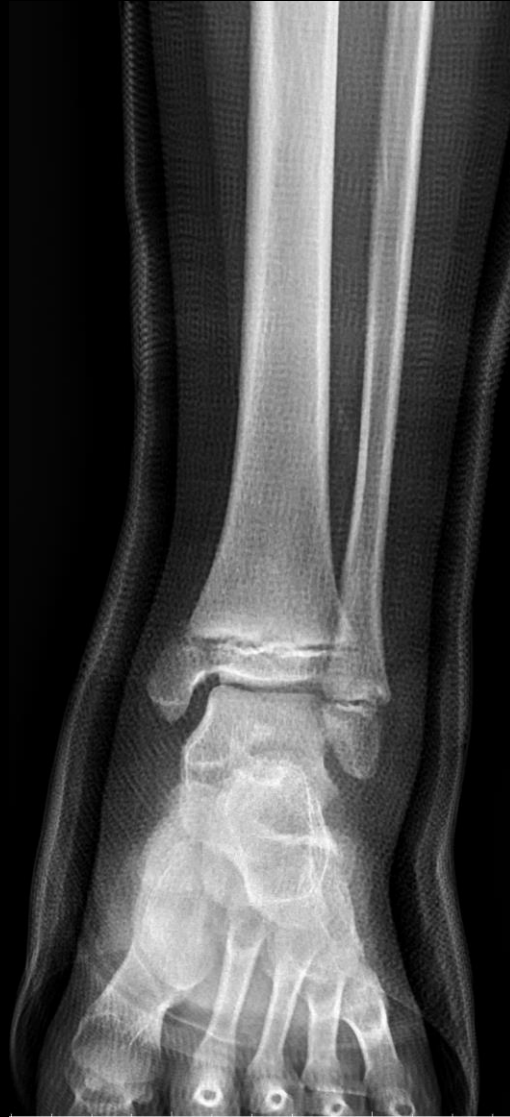What's the proper impression ?

Microcystic adenoma pancreas /  
Serous cystadenoma of pancreas

**Q23-A**

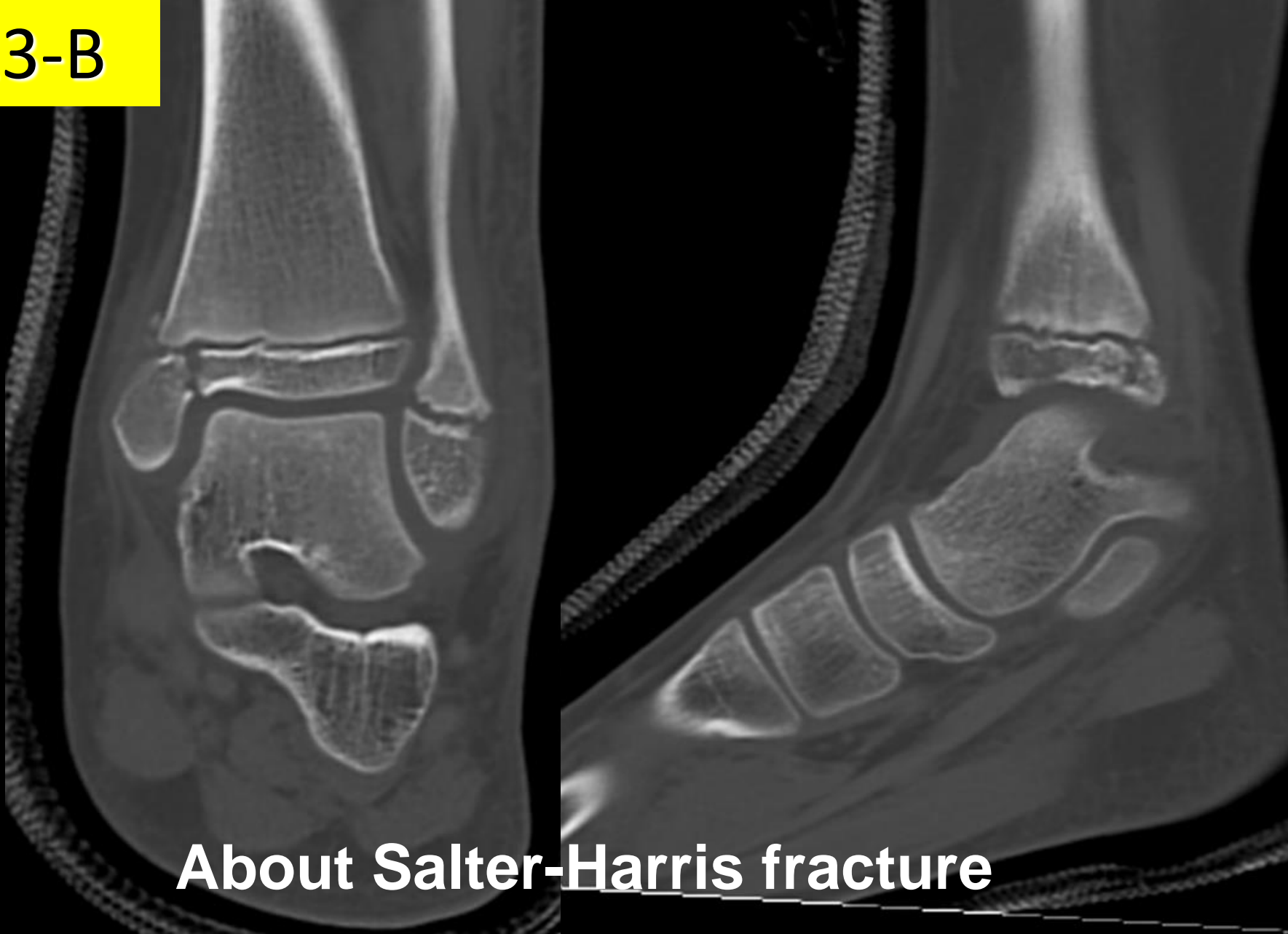# **13 Y/O Male left ankle sprain after jumping**

本題有二張投影片，第一張



Q23-B

本題有二張投影片，第二張



About Salter-Harris fracture

**What is the Salter-Harris type for this case ?**

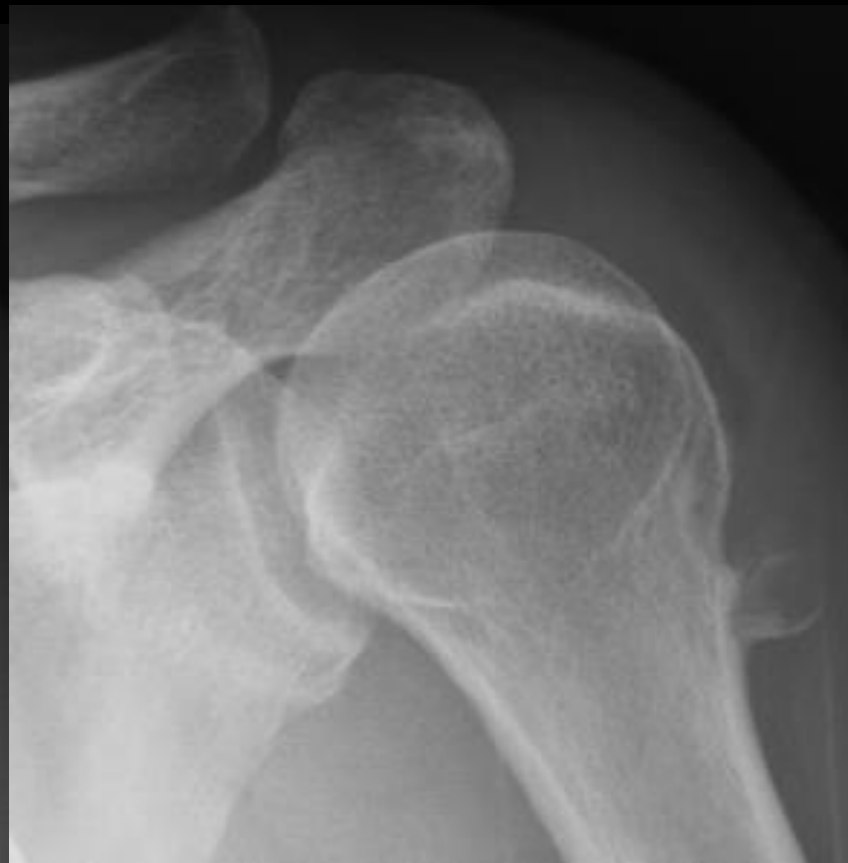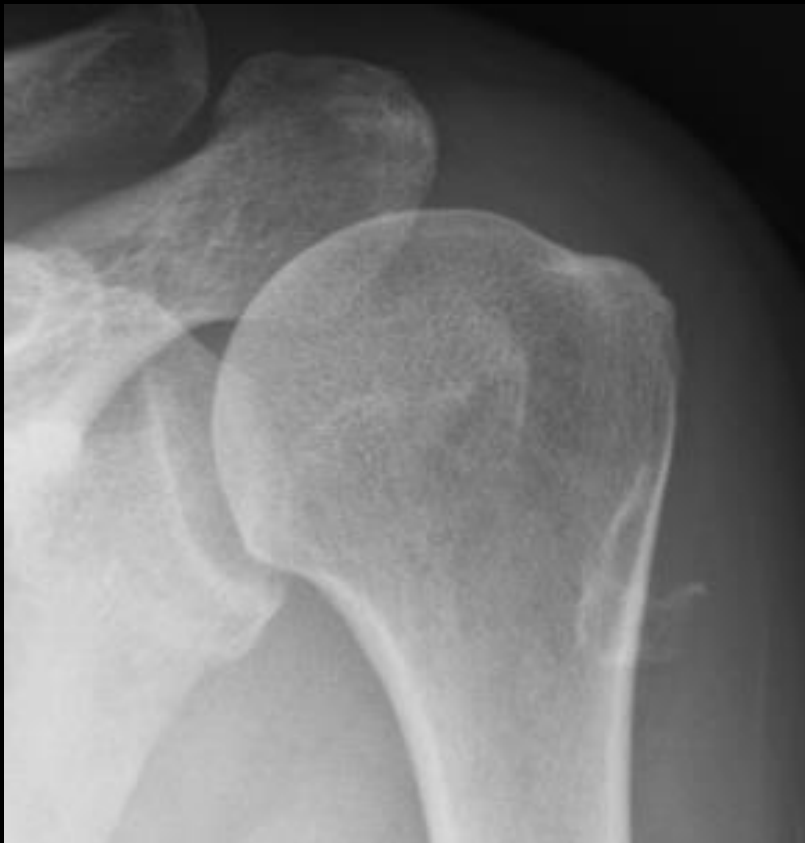**Salter-Harris type III**



**Q24-A**

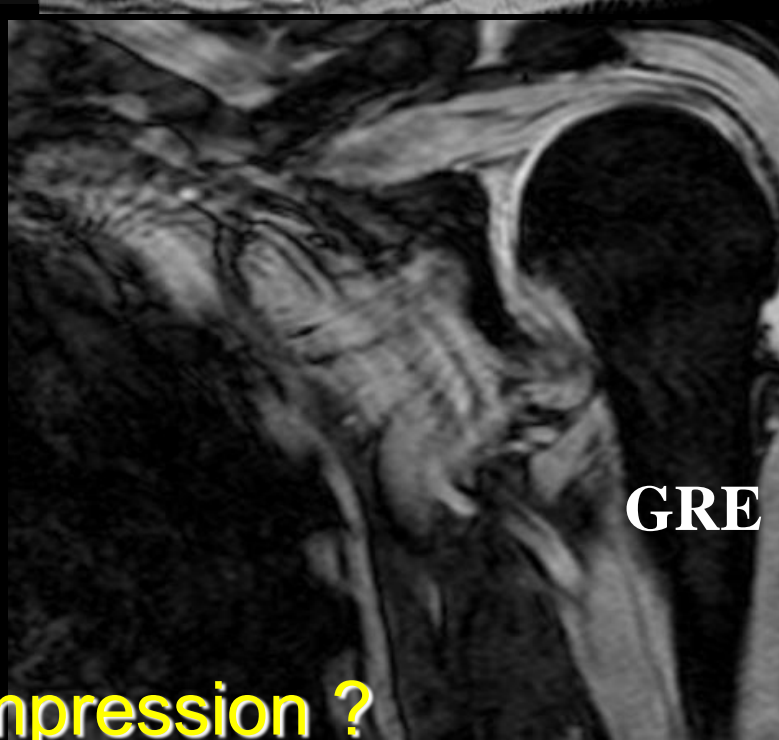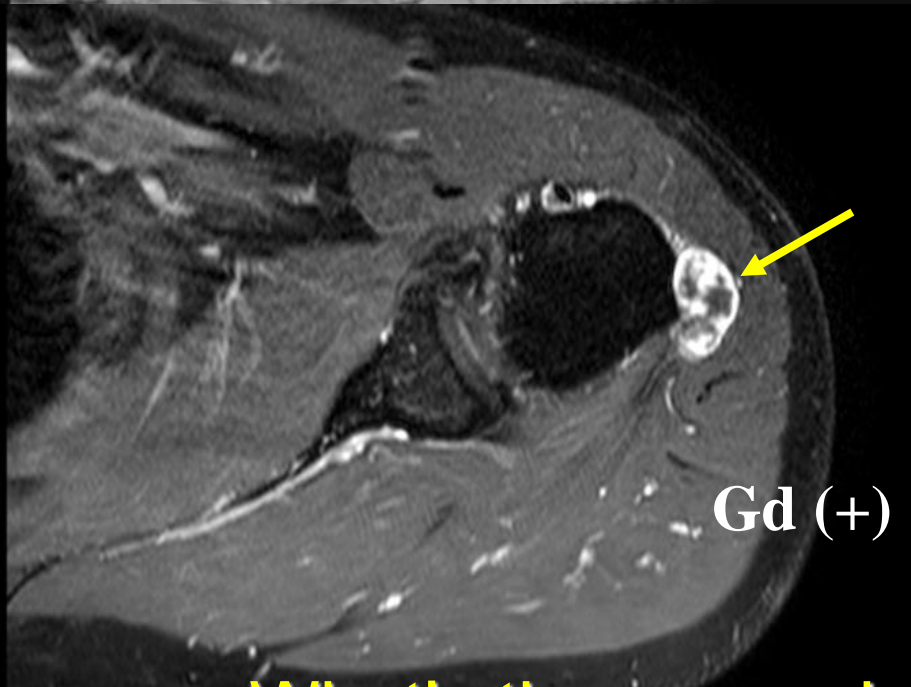
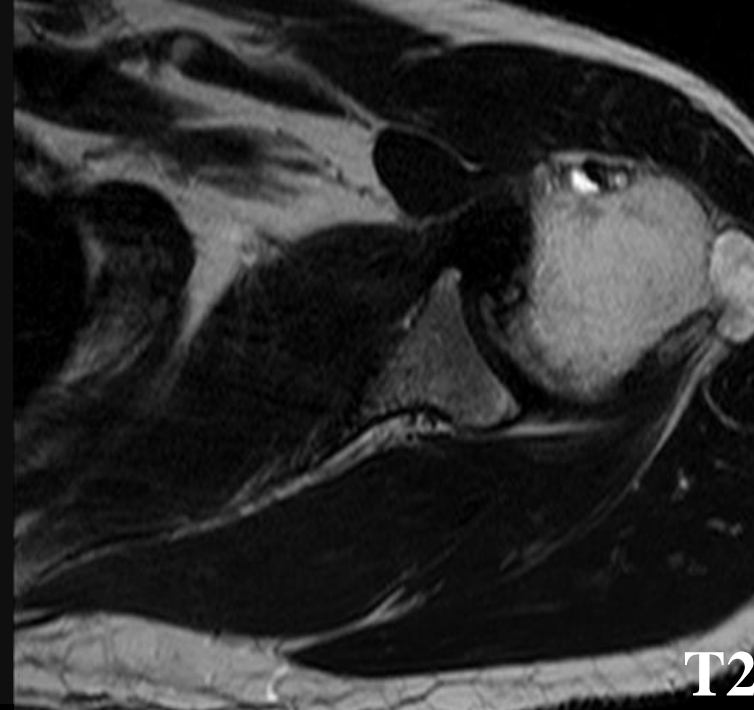
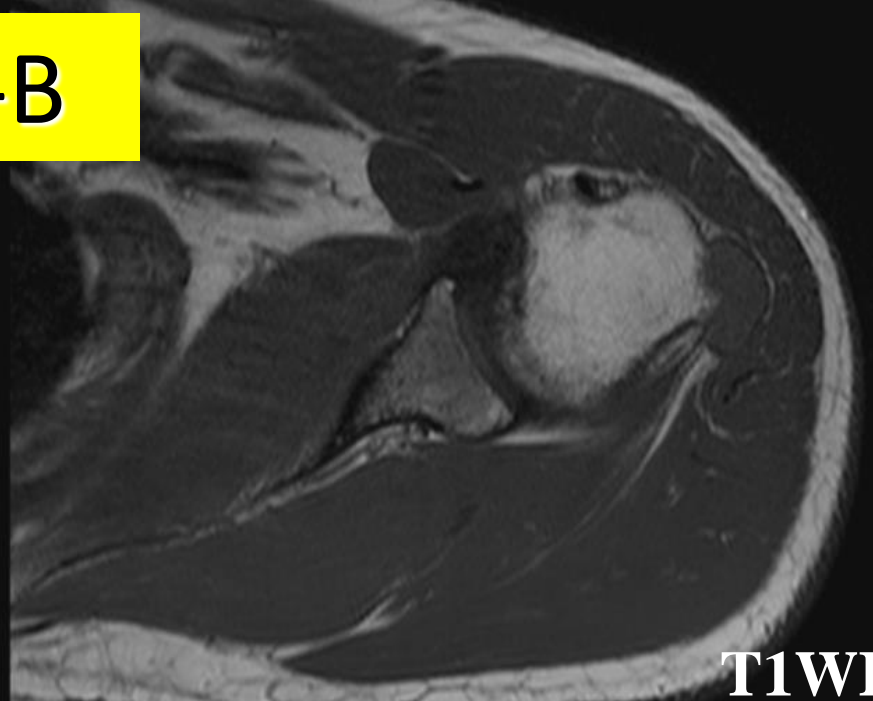
**46 Y/O Male  
Pain of left shoulder and  
neck for 10 + year**

本題有二張投影片，第一張



Q24-B

本題有二張投影片，第二張

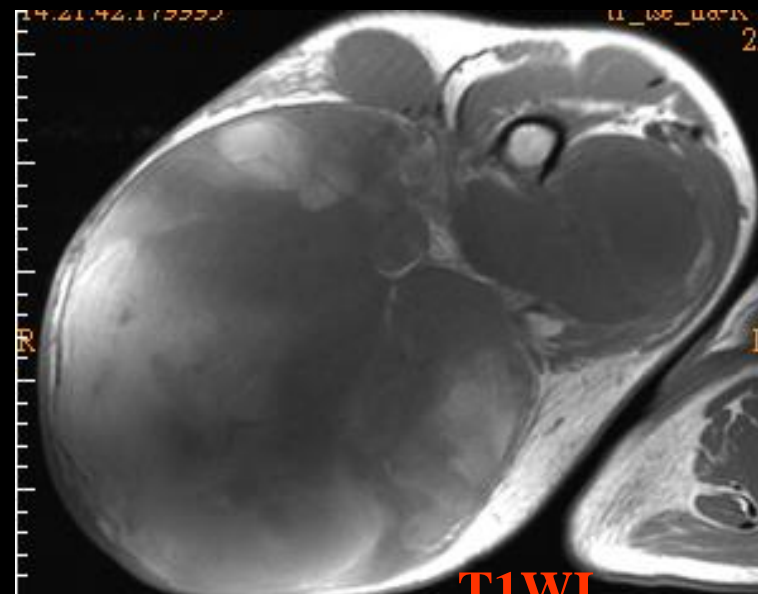
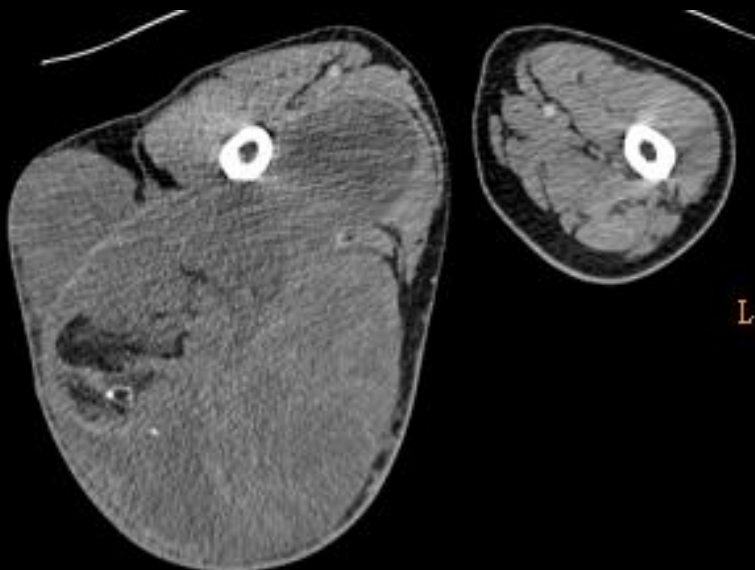


What's the proper impression ?

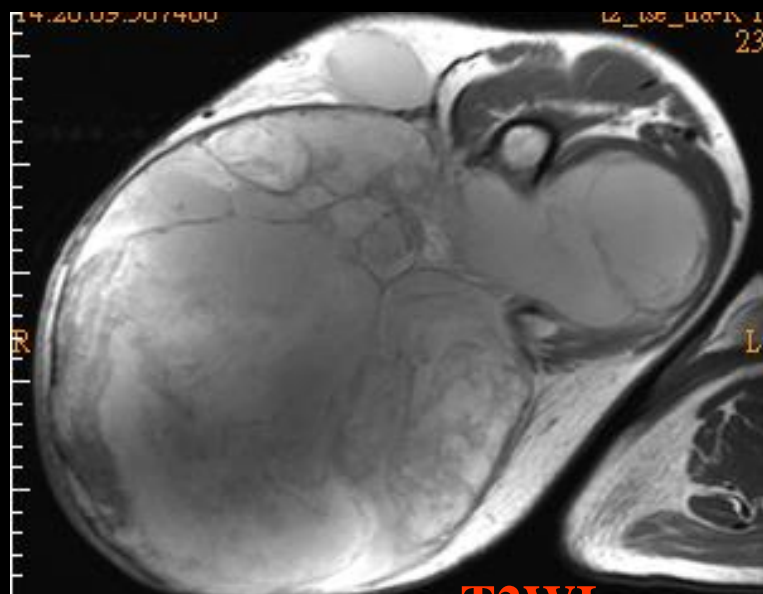
# Periosteal chondroma

**Q25**

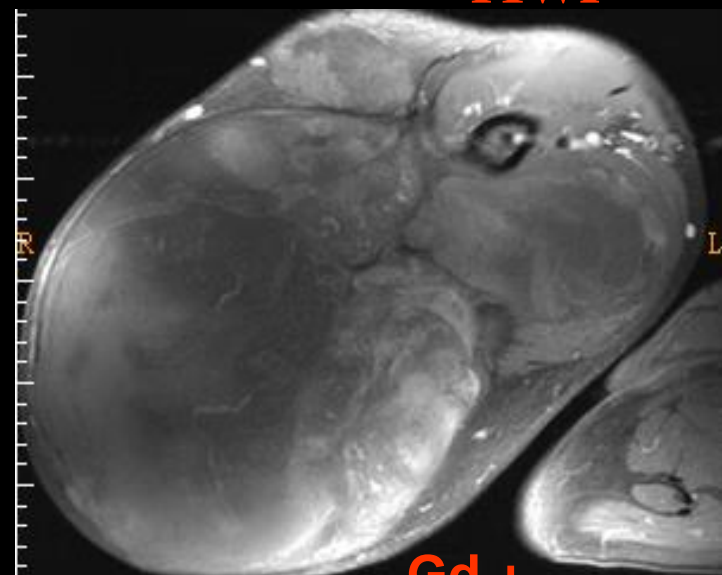
**56 Y/O M Right buttock~thigh huge hard mass for years, rapid growth recently**



**T1WI**



**T2WI**



**Gd +**

**What's the proper impression ?**

# Myxoid liposarcoma

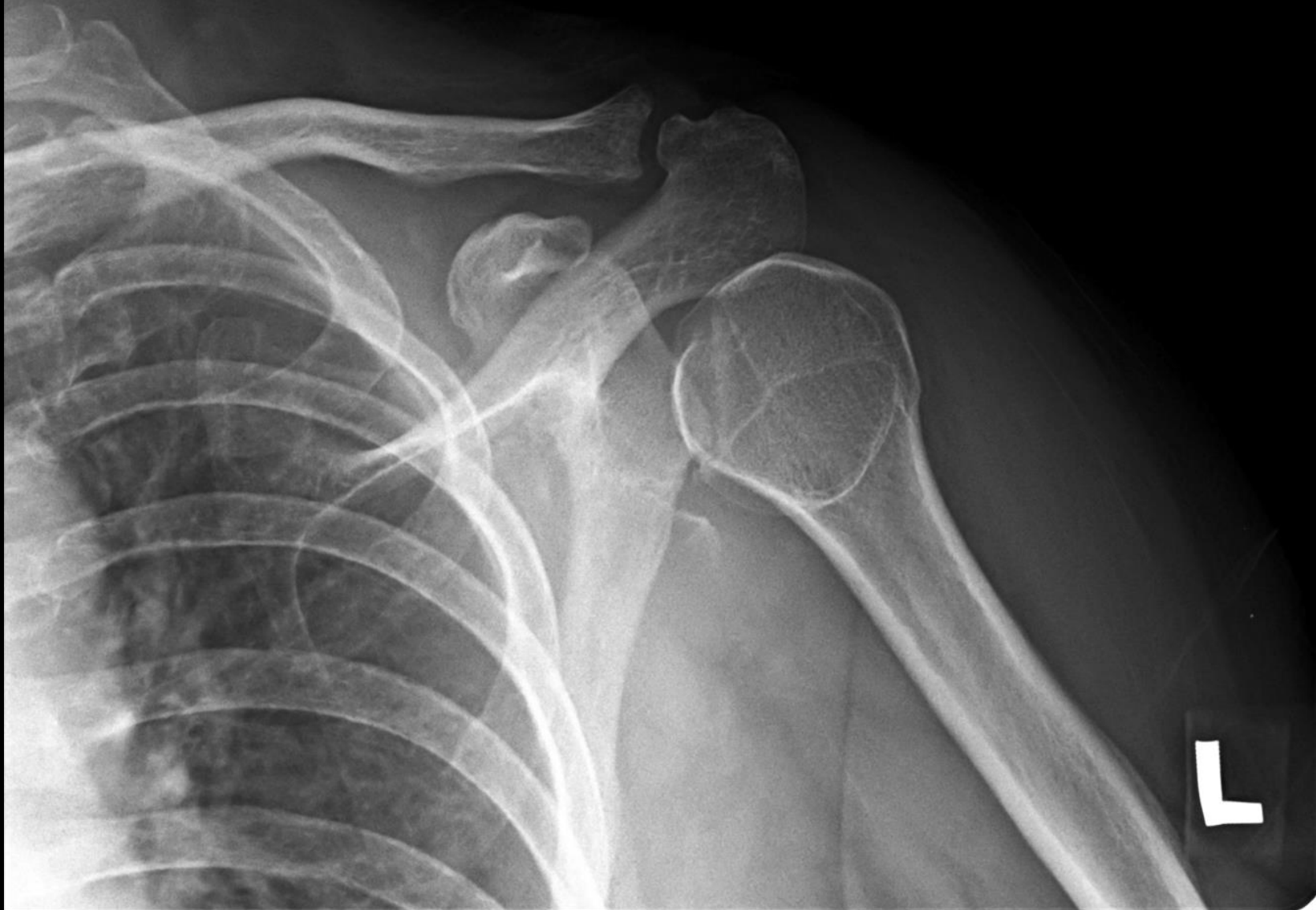


Q26-A

58 Y/O Female

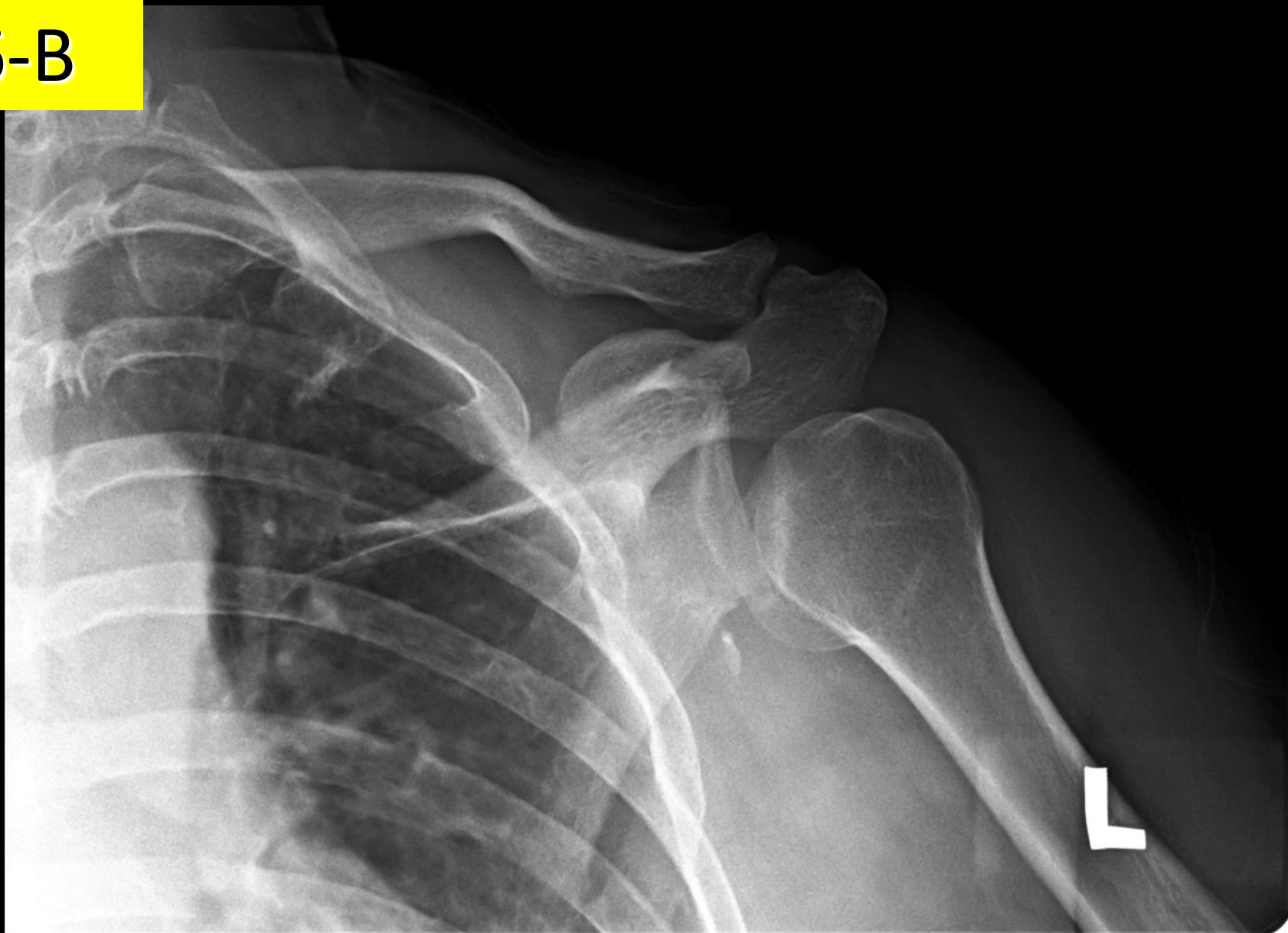Shoulder pain due to motorcycle accident

本題有二張投影片，第一張



Q26-B

本題有二張投影片，第二張



What's the proper impression ?

Posterior dislocation of shoulder joint

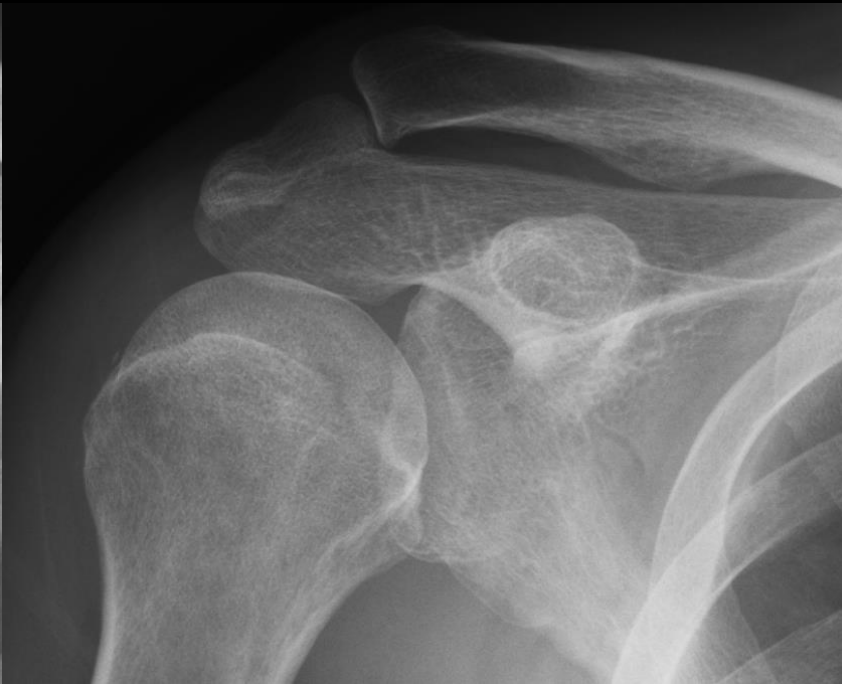
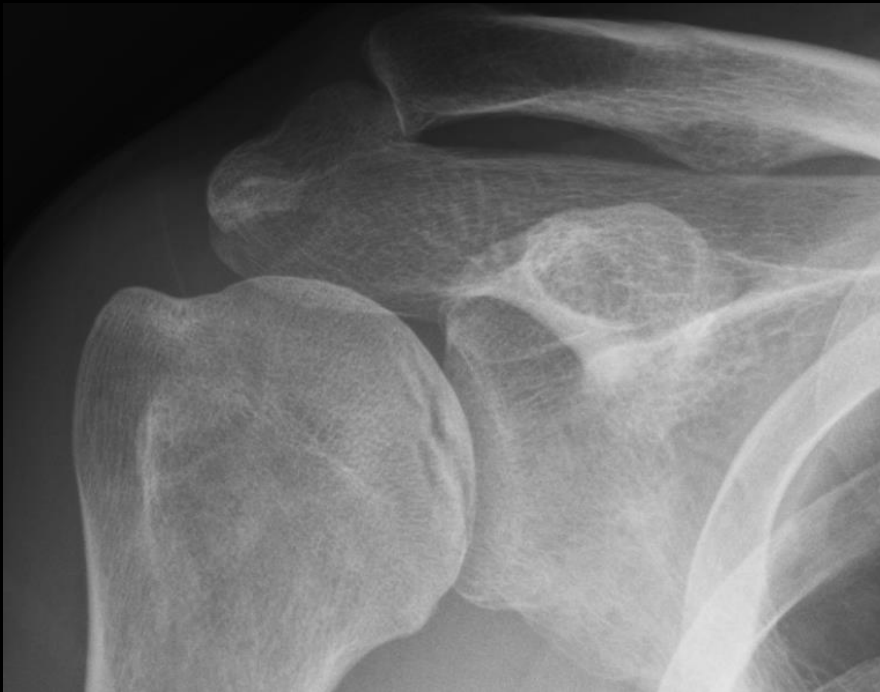Q27-A

49 Y/O Male

Known history of brain tumor post operation

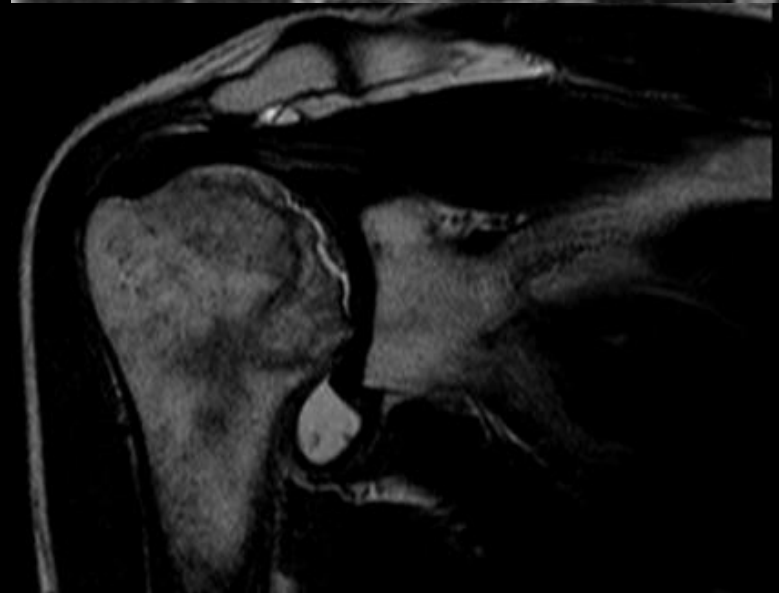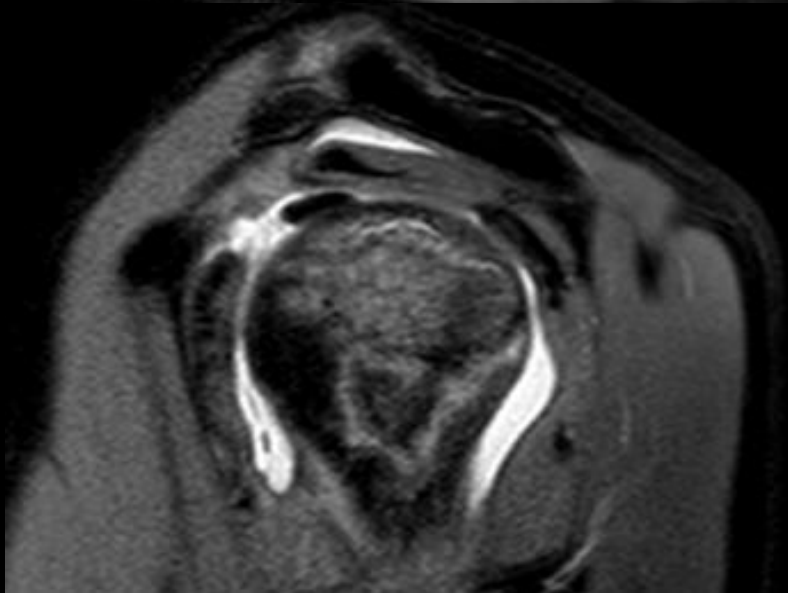
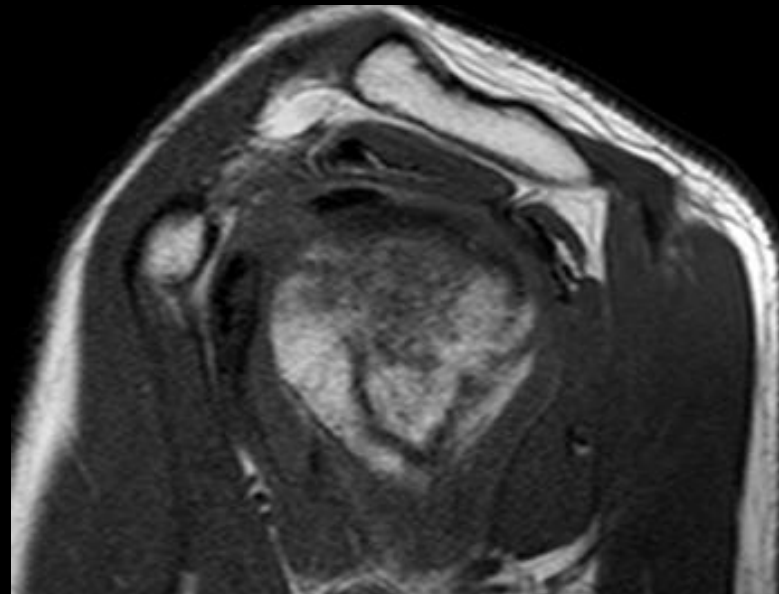
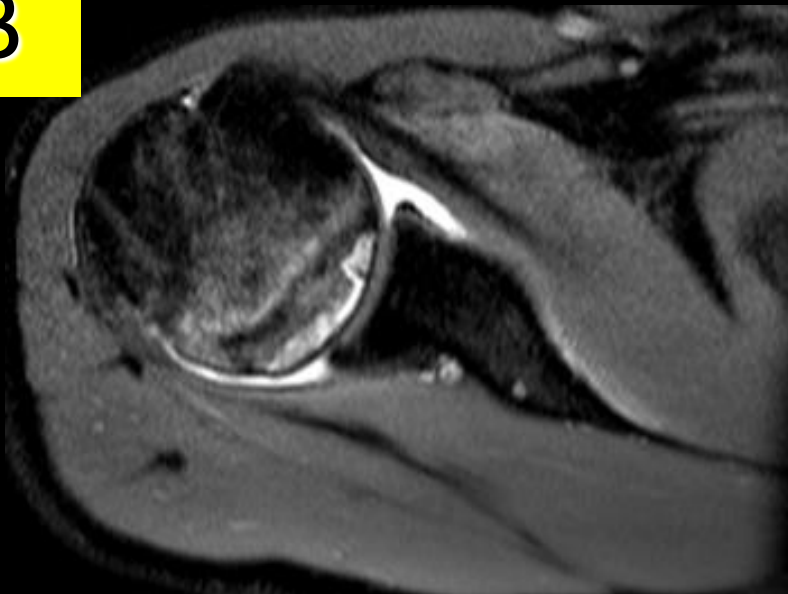
Right shoulder pain with ROM limited

本題有二張投影片，第一張



Q27-B

本題有二張投影片，第二張



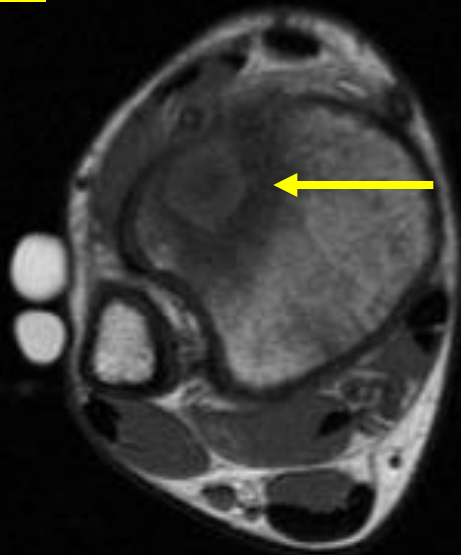
What's the proper impression ?

# **Avascular necrosis of humeral head**

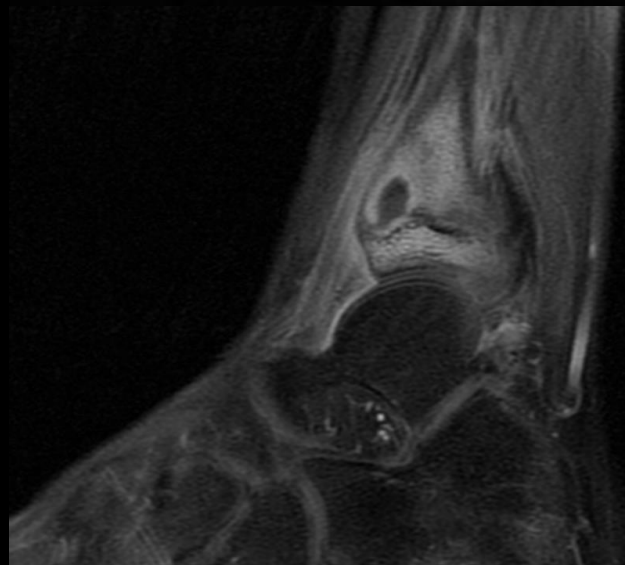
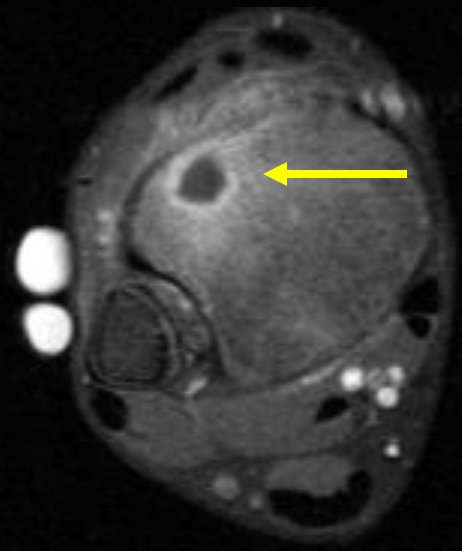
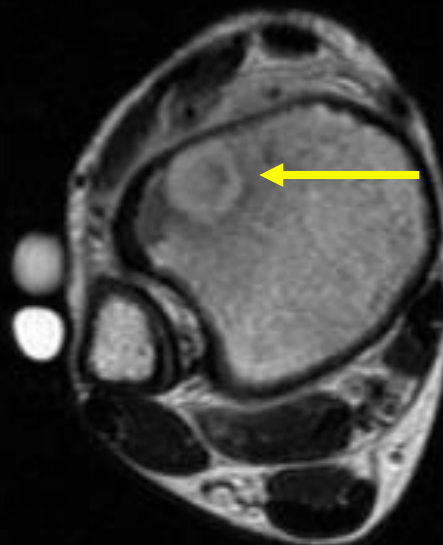


**Q28**

**9y/o F Right ankle pain with swelling for 10 days, fever up to 38+C for 2-3 days**



**T1WI**

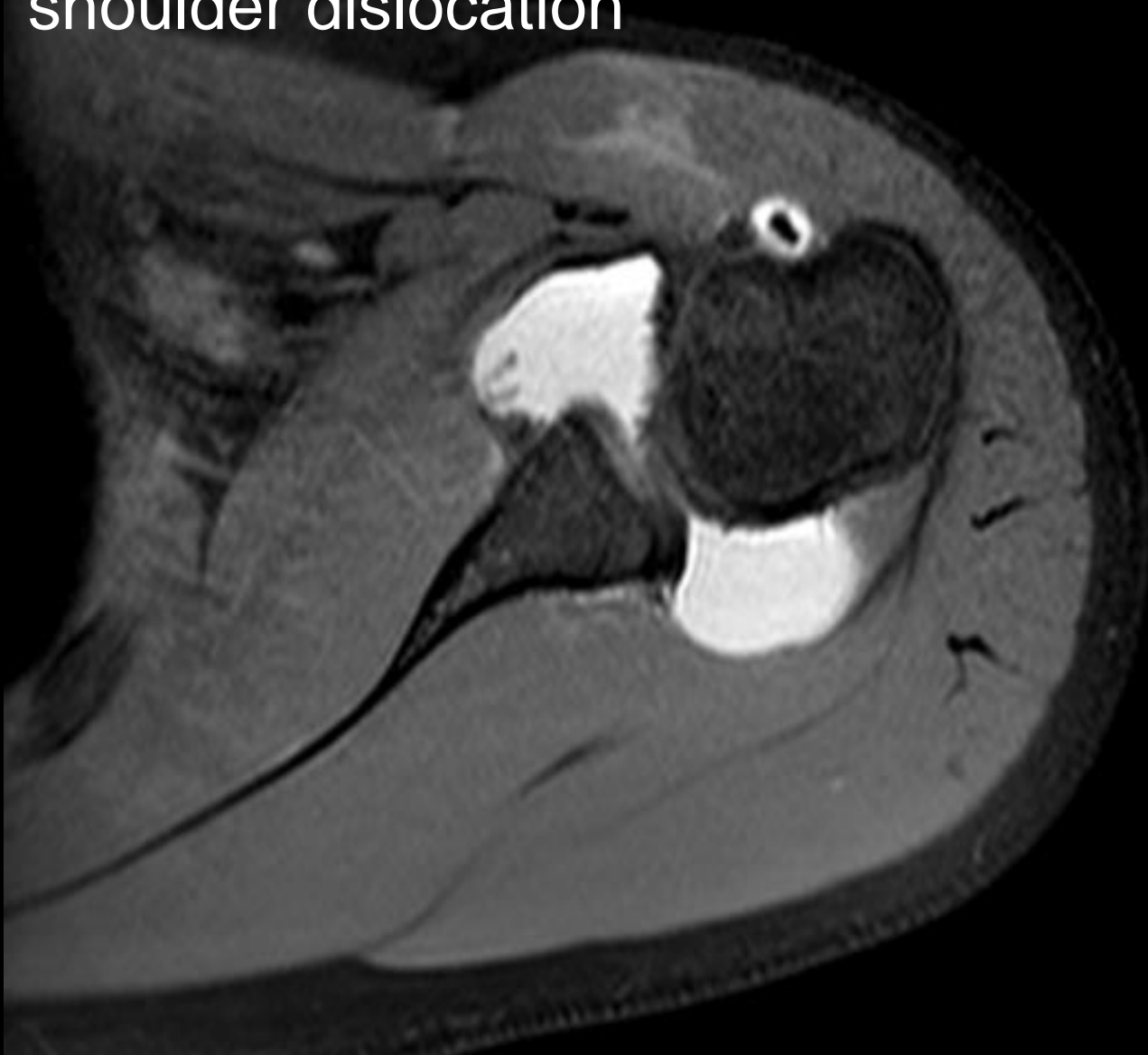

**What the yellow arrow indicate ?**

**Penumbra sign, Brodie's abscess**

**Q29**

16 Y/O Male History of recurrent  
shoulder dislocation

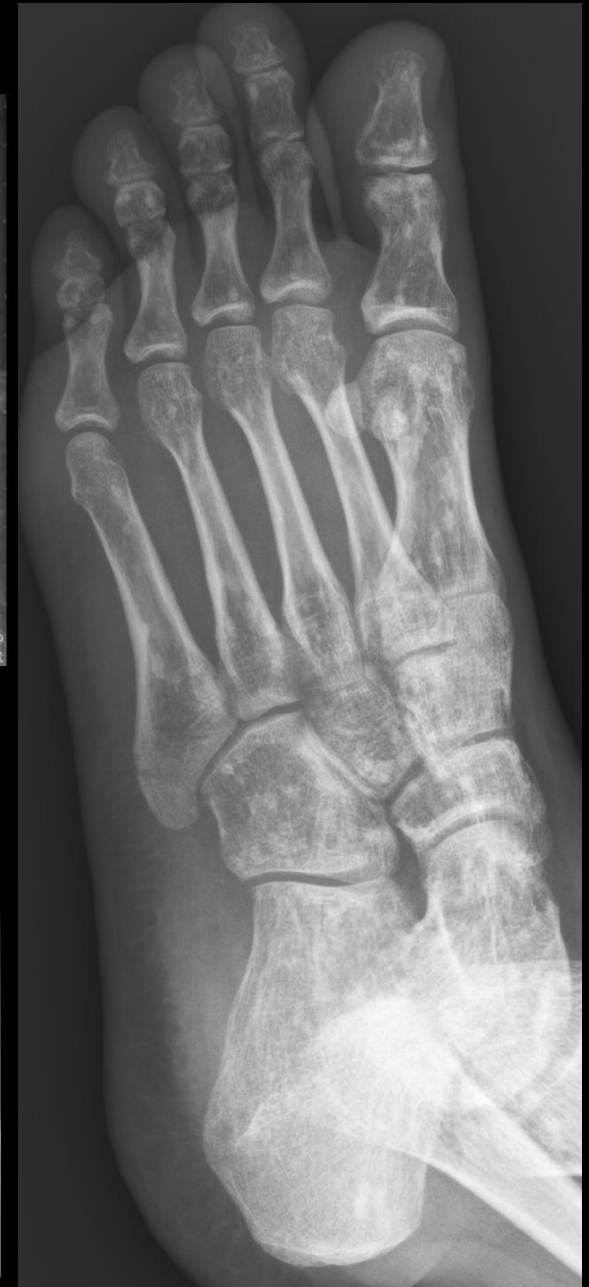
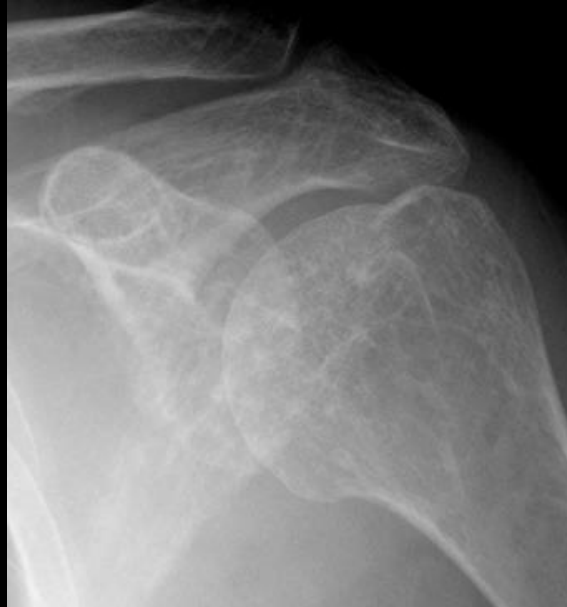
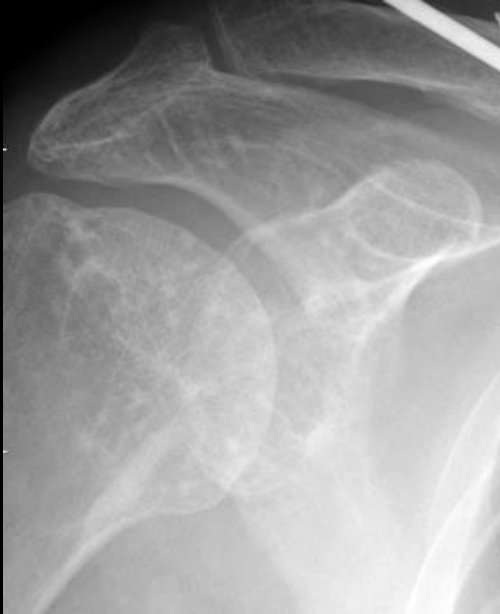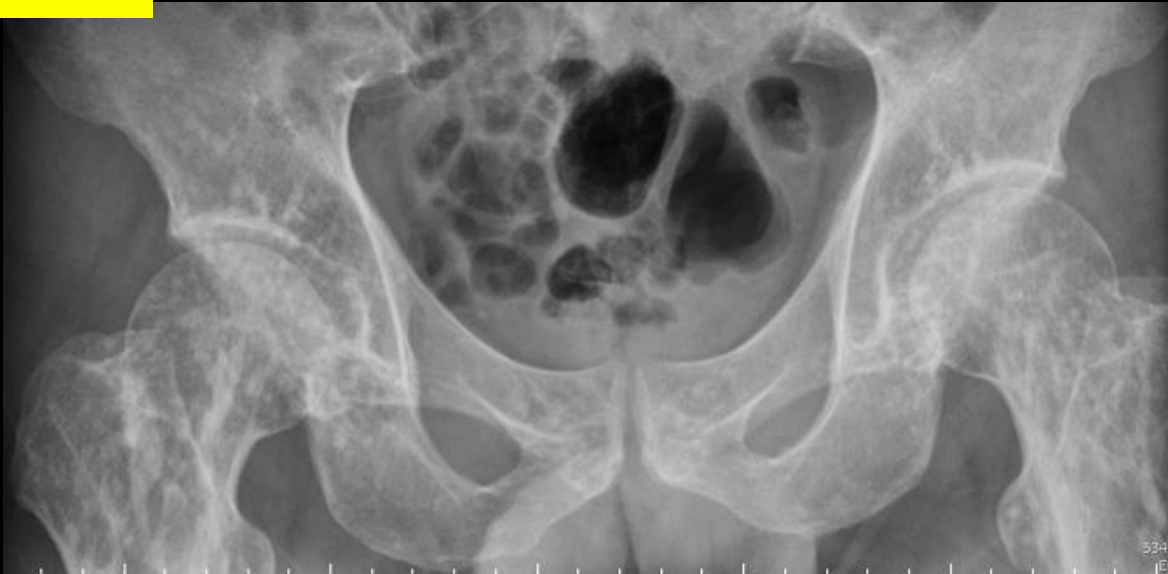**What's the proper impression ?**

ALPSA (anterior labroligamentous  
periosteal sleeve avulsion) lesion

**Q30**

42 Y/O Male



**What's the proper impression ?**

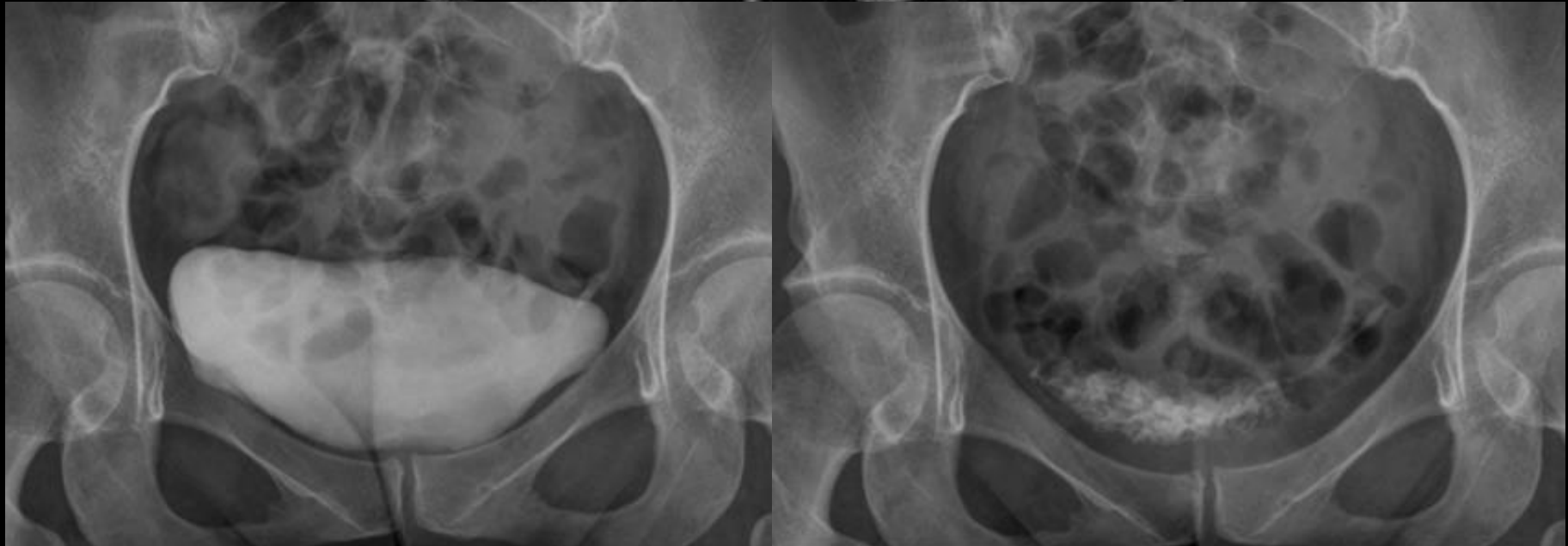
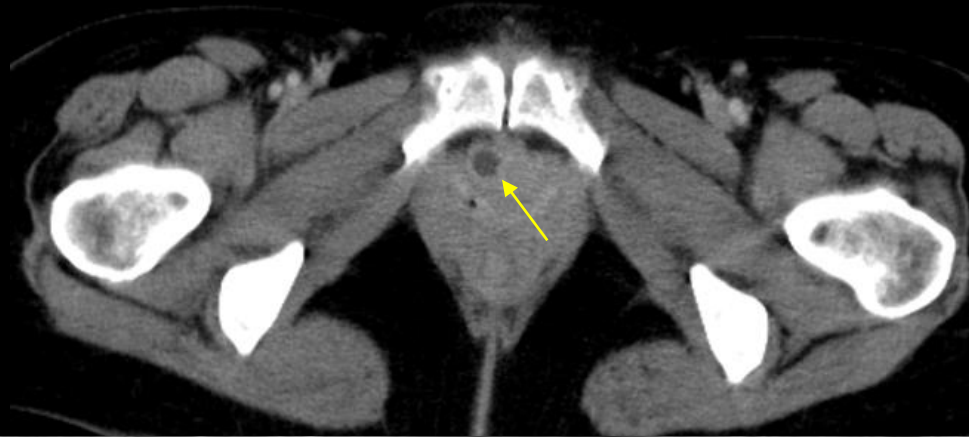# Osteopoikilosis



**Q31**

35 Y/O female

CC: Micturition pain and frequency / fever / UA-WBC+++



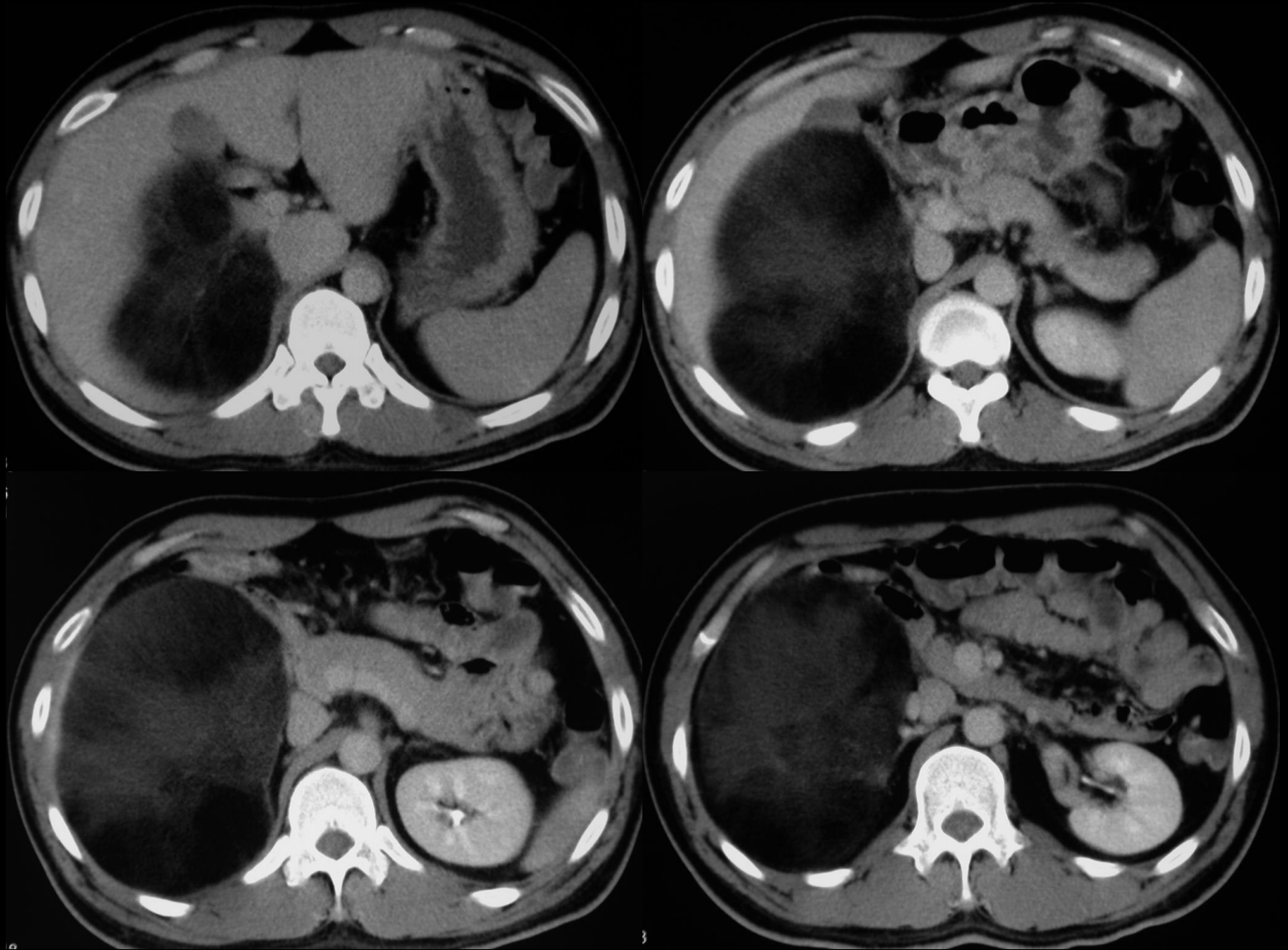
**What's the proper impression ?**

Urethral diverticulum

**Q32**

31 Y/O Male

CC: Abdominal fullness for 3 months



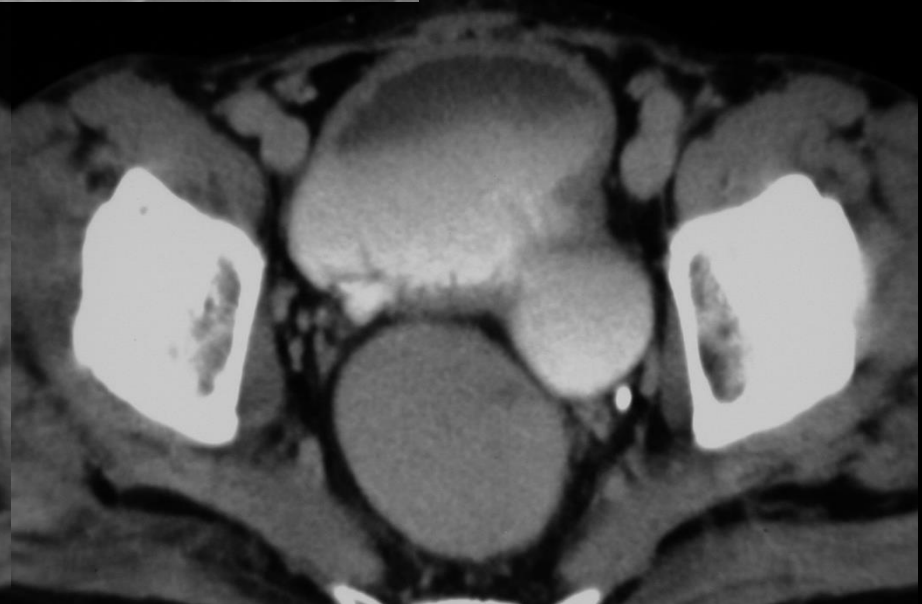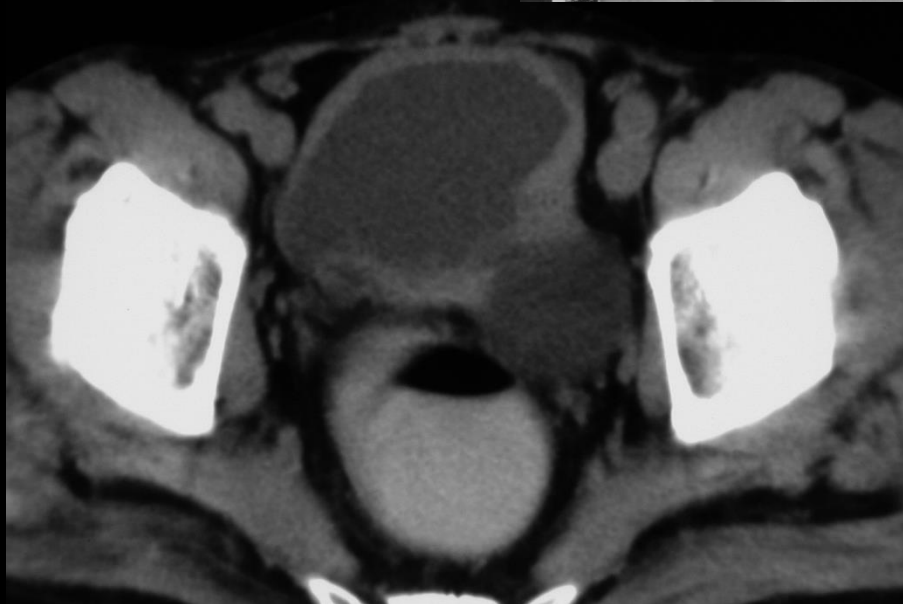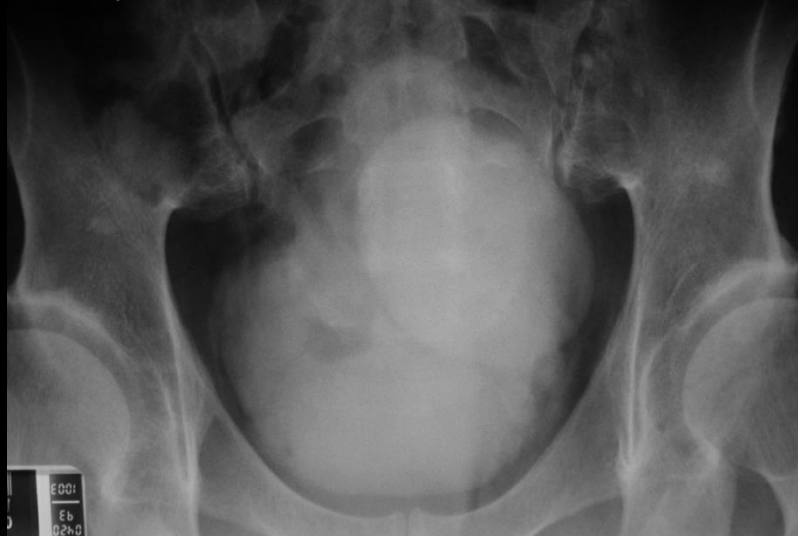**What's the proper impression ?**

Right adrenal myelolipoma

**Q33**

73 Y/O Male

CC: Dysuria with suprapubic pain for one year



**What's the proper impression ?**

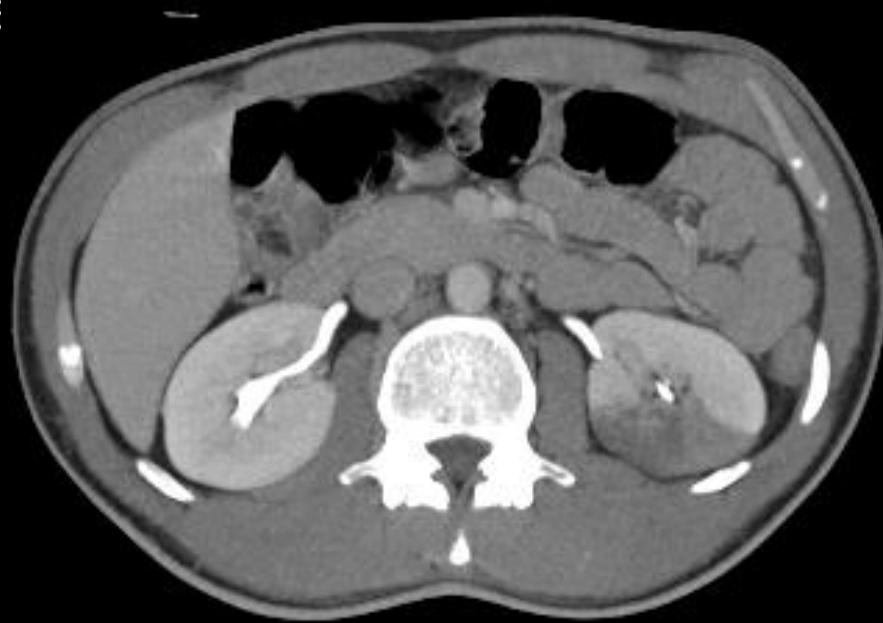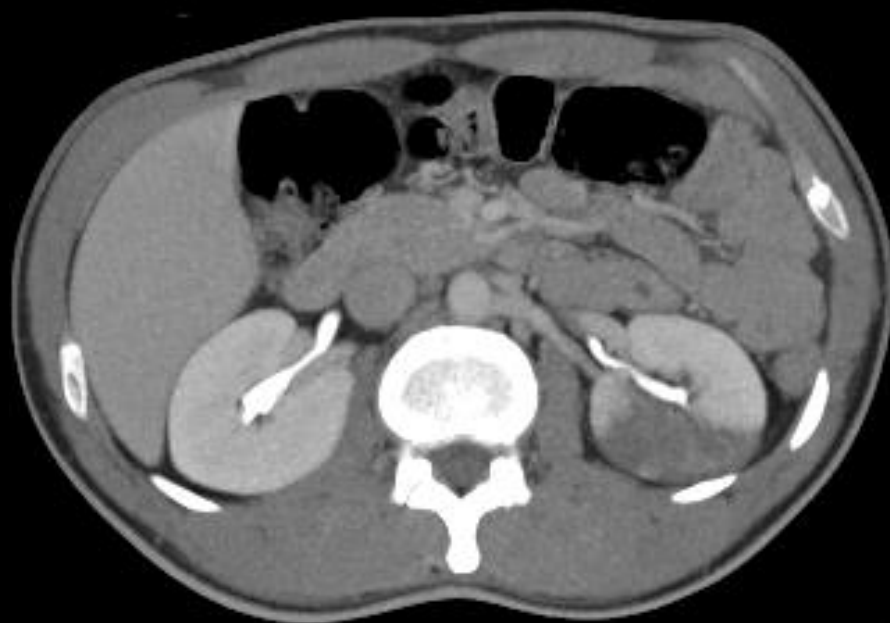
Diverticulum of urinary bladder



**Q34**

**42 Y/O Male**

**CC: Sudden onset of left flank pain this afternoon**



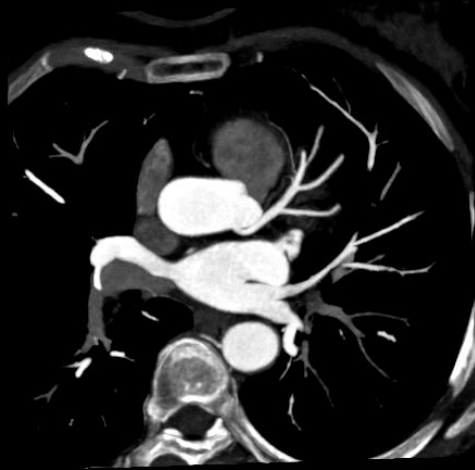**What's the proper impression ?**

Q34-ANS

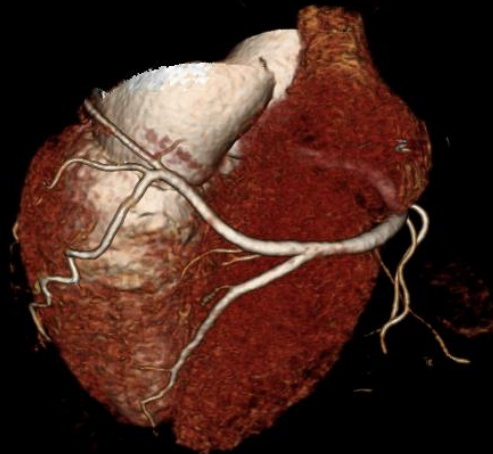
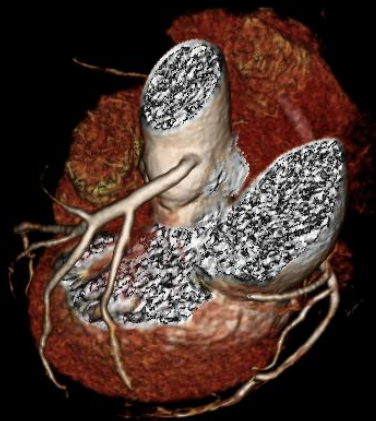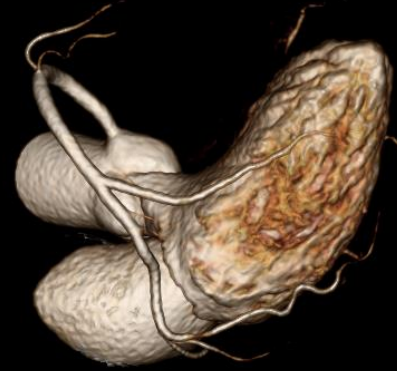
Left renal infarct

Q35

54 Y/O Male, coronary CTA for  
physical examination



TERAI

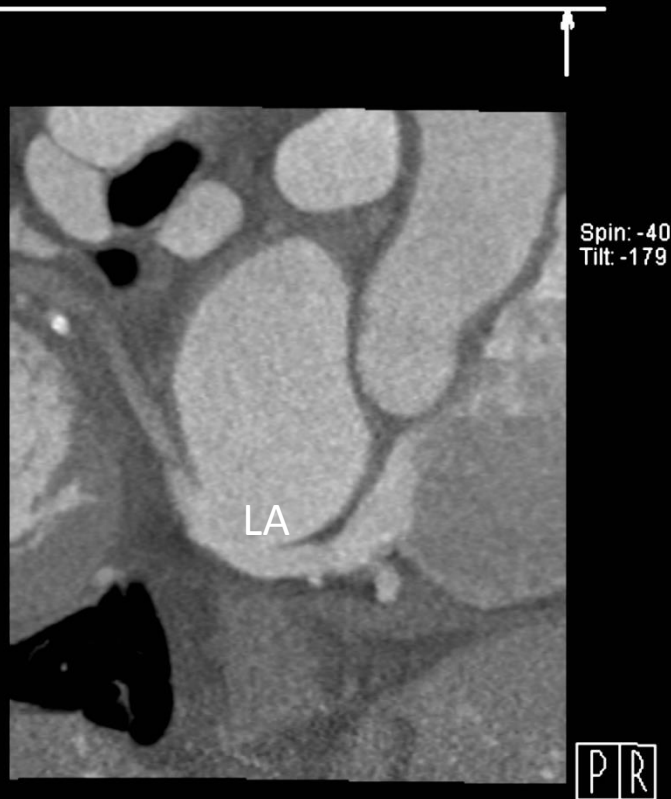

What's the proper impression ?

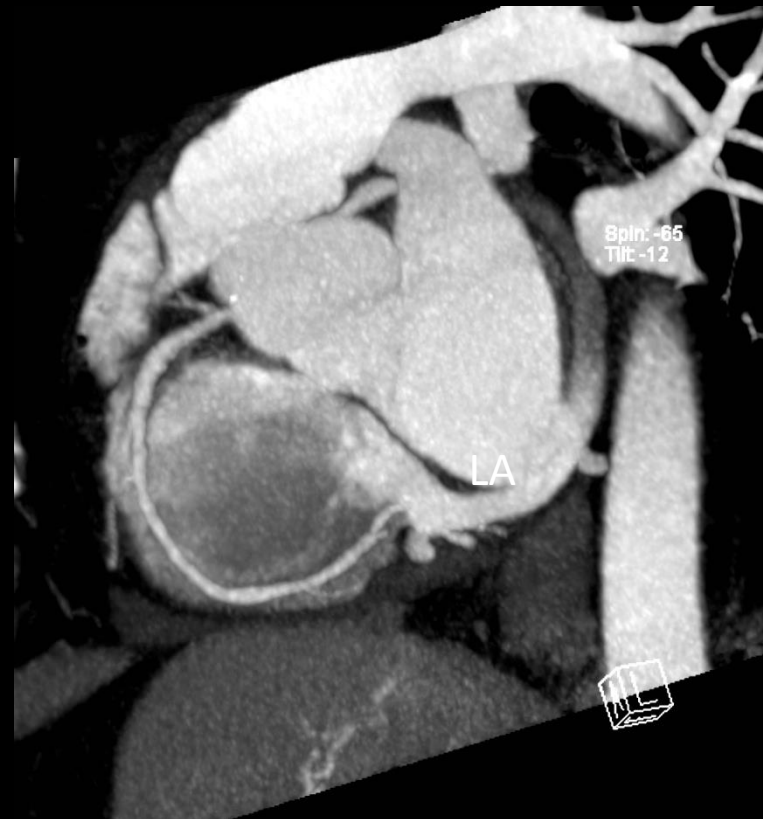
**Congenital absence of left  
circumflex artery (LCx agenesis)  
with superdominant RCA**

Q36

45 Y/O Male abnormal finding in echo



<FAR>



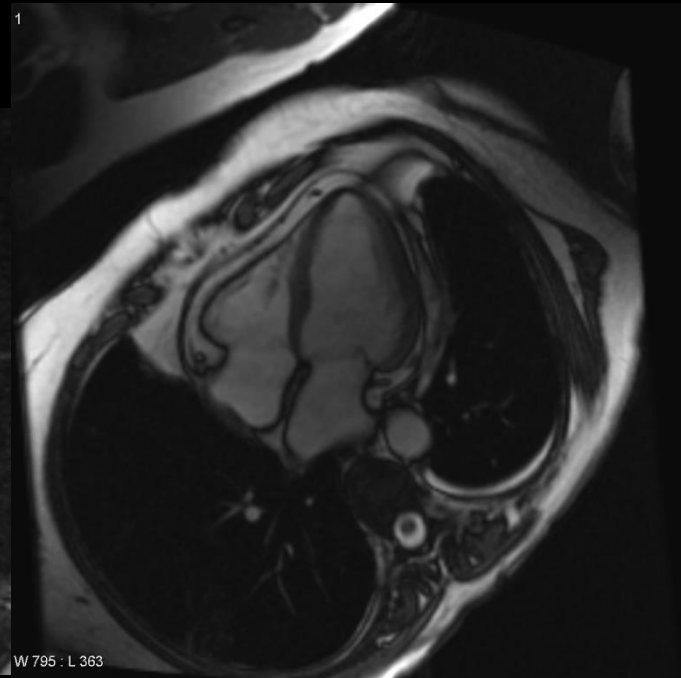
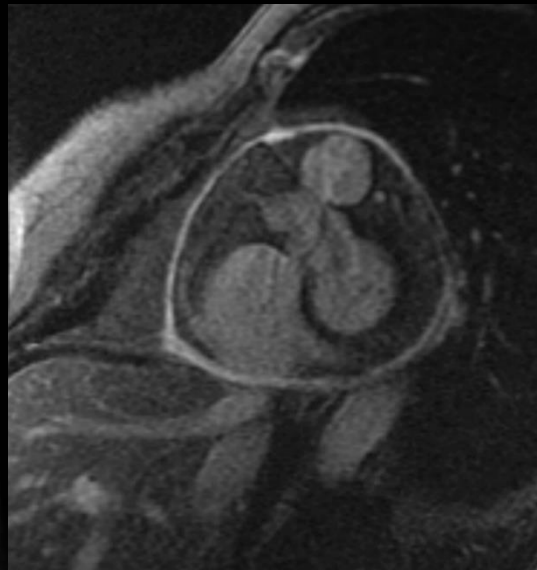
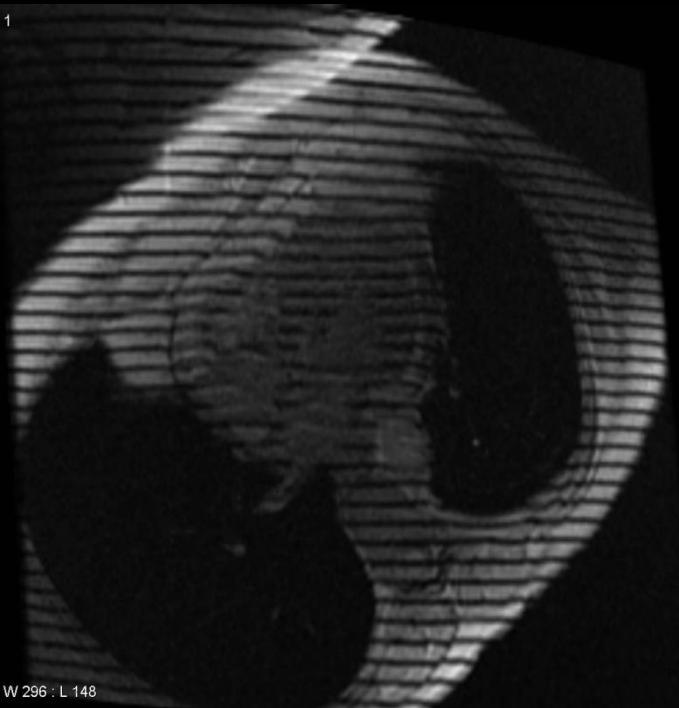
What's the proper impression ?

Unroofed coronary sinus



**Q37**

**35 Y/O Female, Dyspnea on exertion**

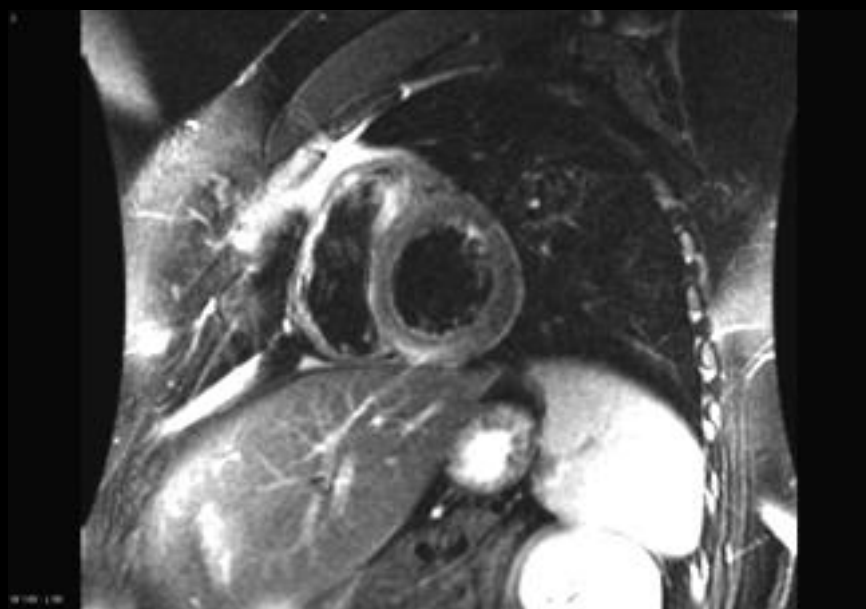
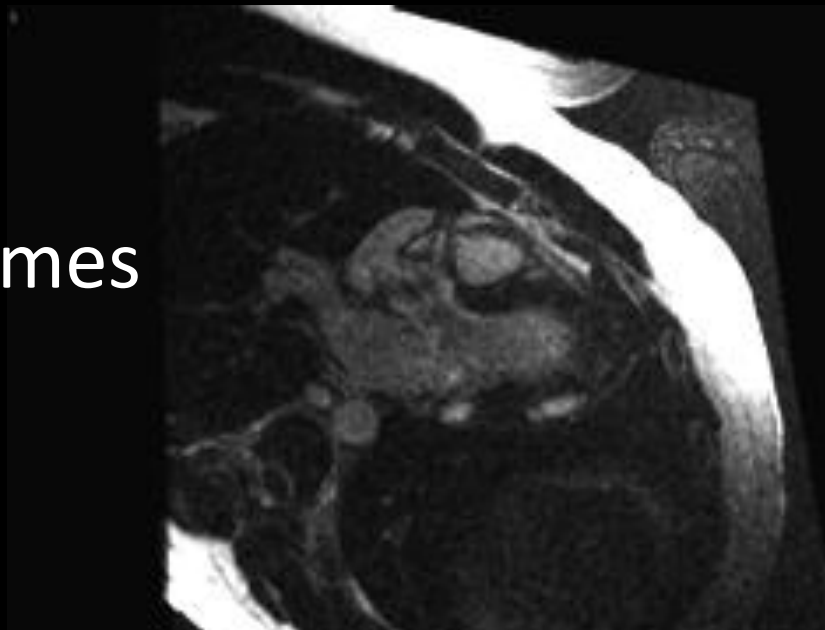


**What's the proper impression ?**

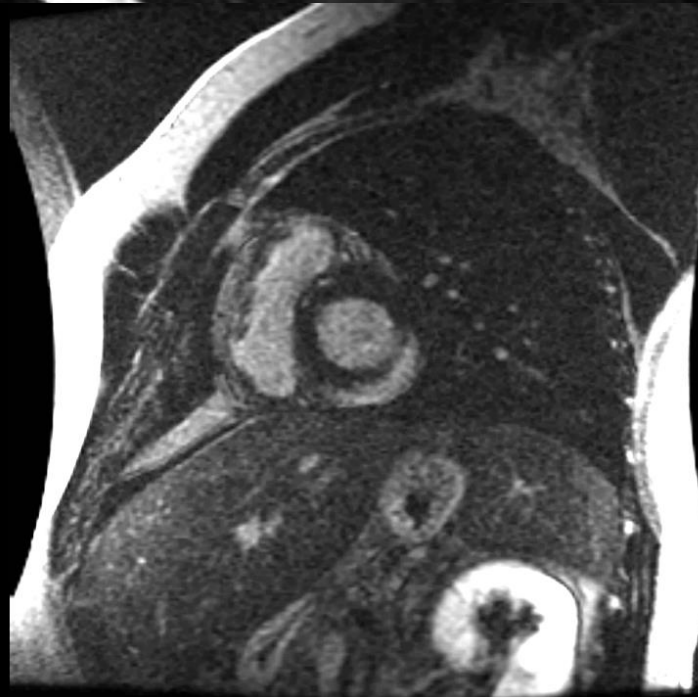# Constrictive pericarditis

**Q38**

32 Y/O Male, with  
abnormal cardiac enzymes  
and ECG changes



**T2WI**



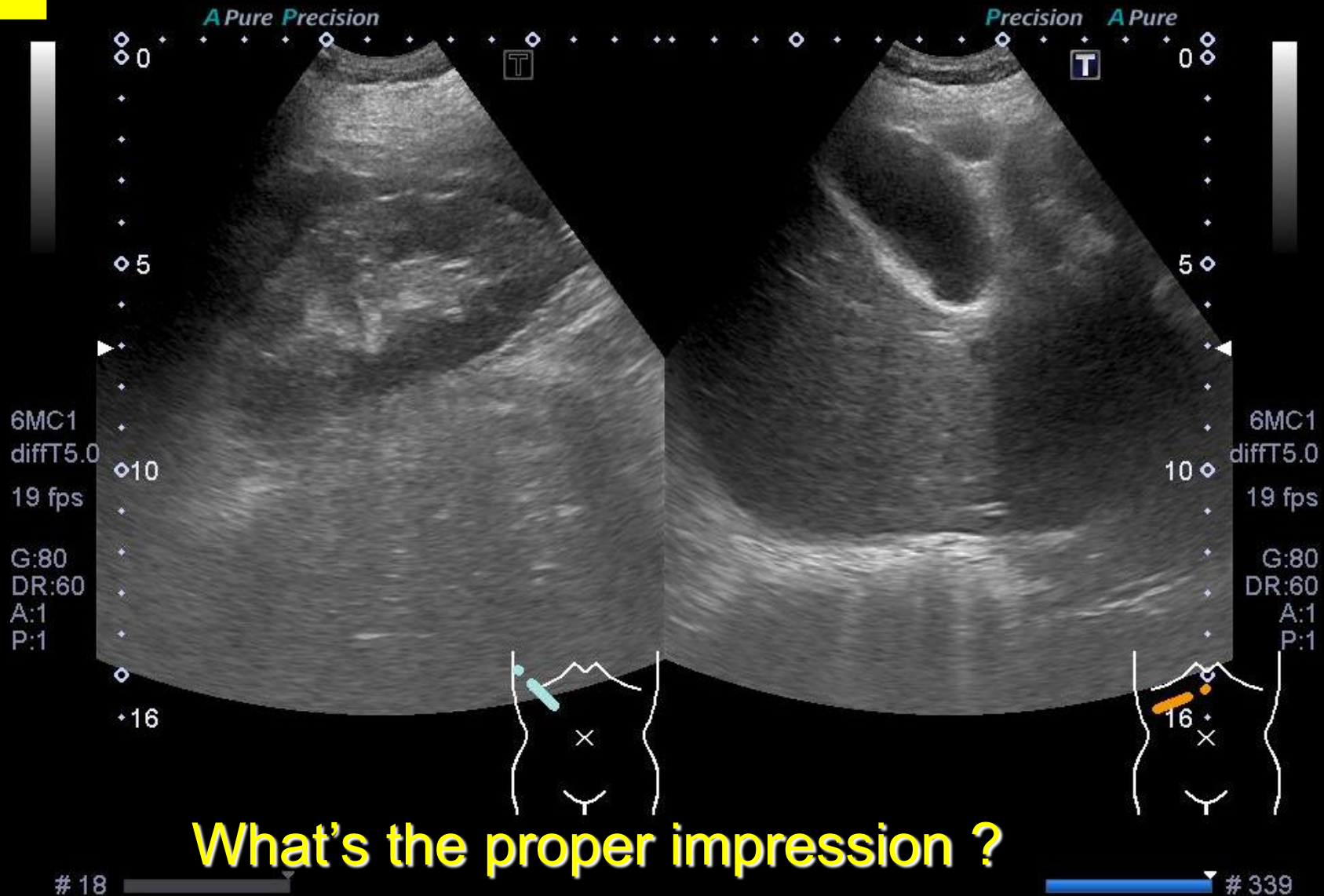
W 49 : L 26

**What's the proper impression ?**

Acute myocarditis

Q39

79 Y/O female Mild abdominal pain for six months



Adenomyomatosis of gall bladder

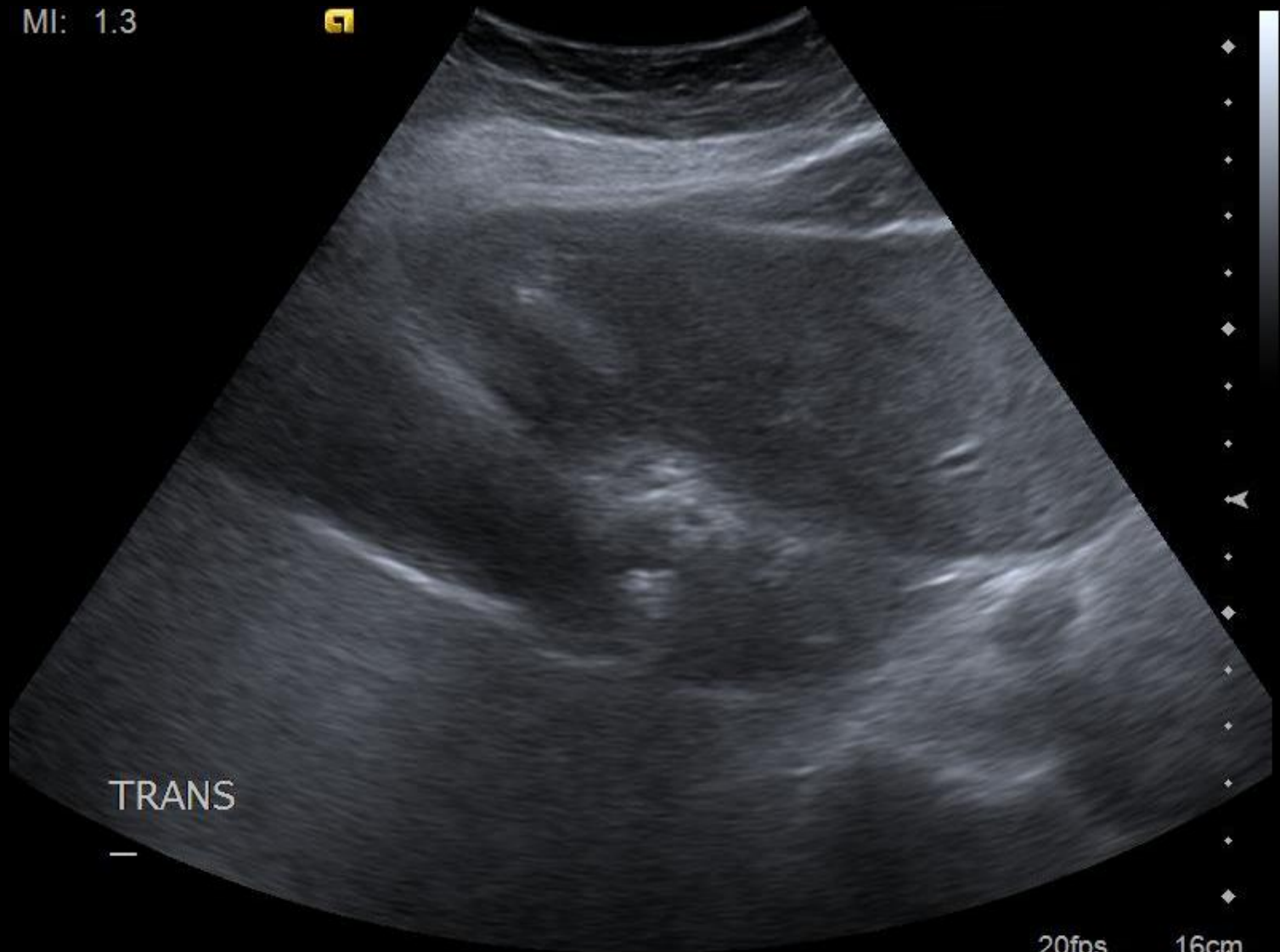


Q40

81 Y/O female

RUQ pain, nausea, and vomiting for three day

MI: 1.3



**What's the proper impression ?**

20fps

16cm

100%



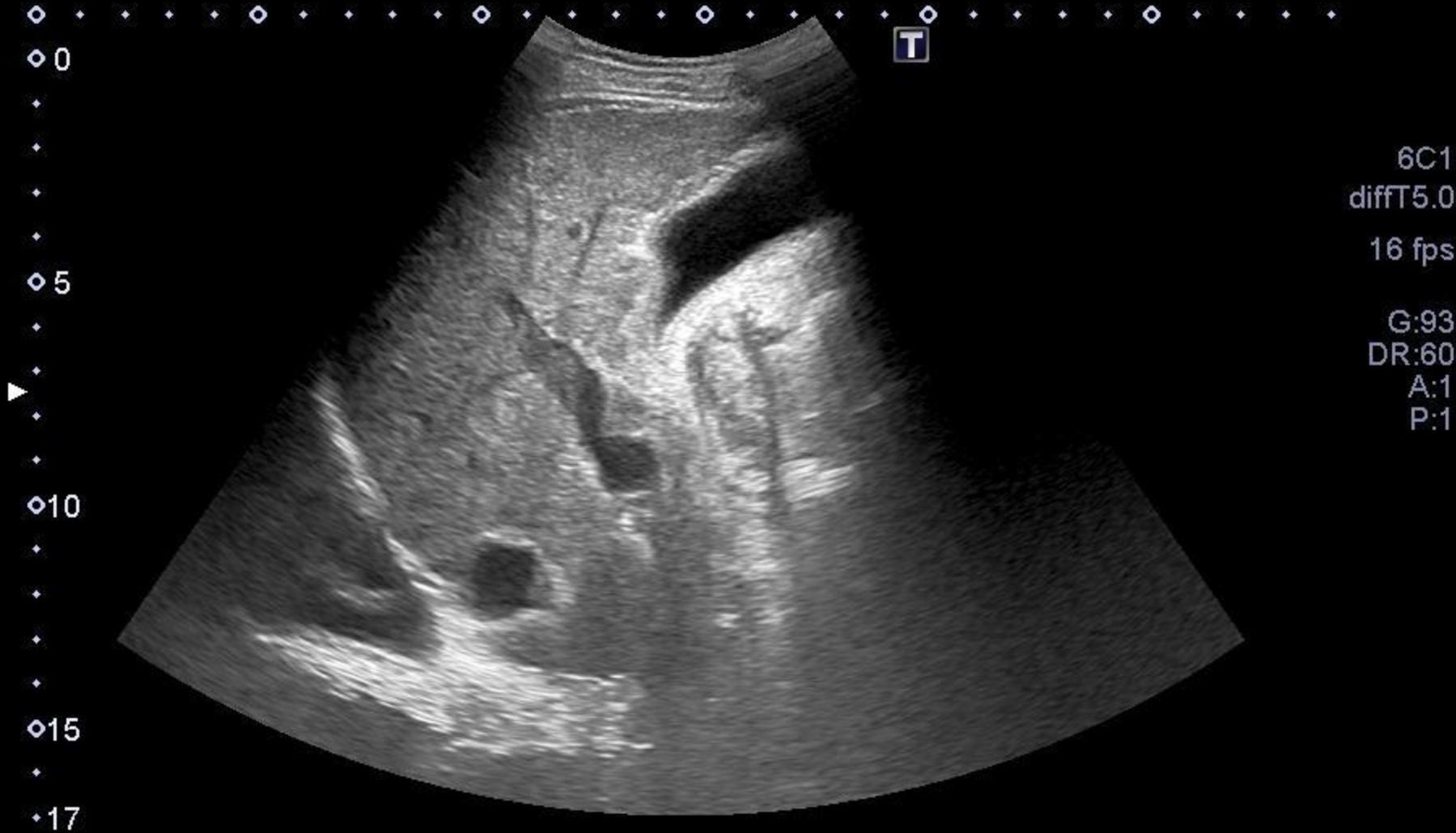Fr629

Cystic duct stone

**Q41**

58 Y/O Male

Alcoholic liver disease with jaundice and esophageal varices



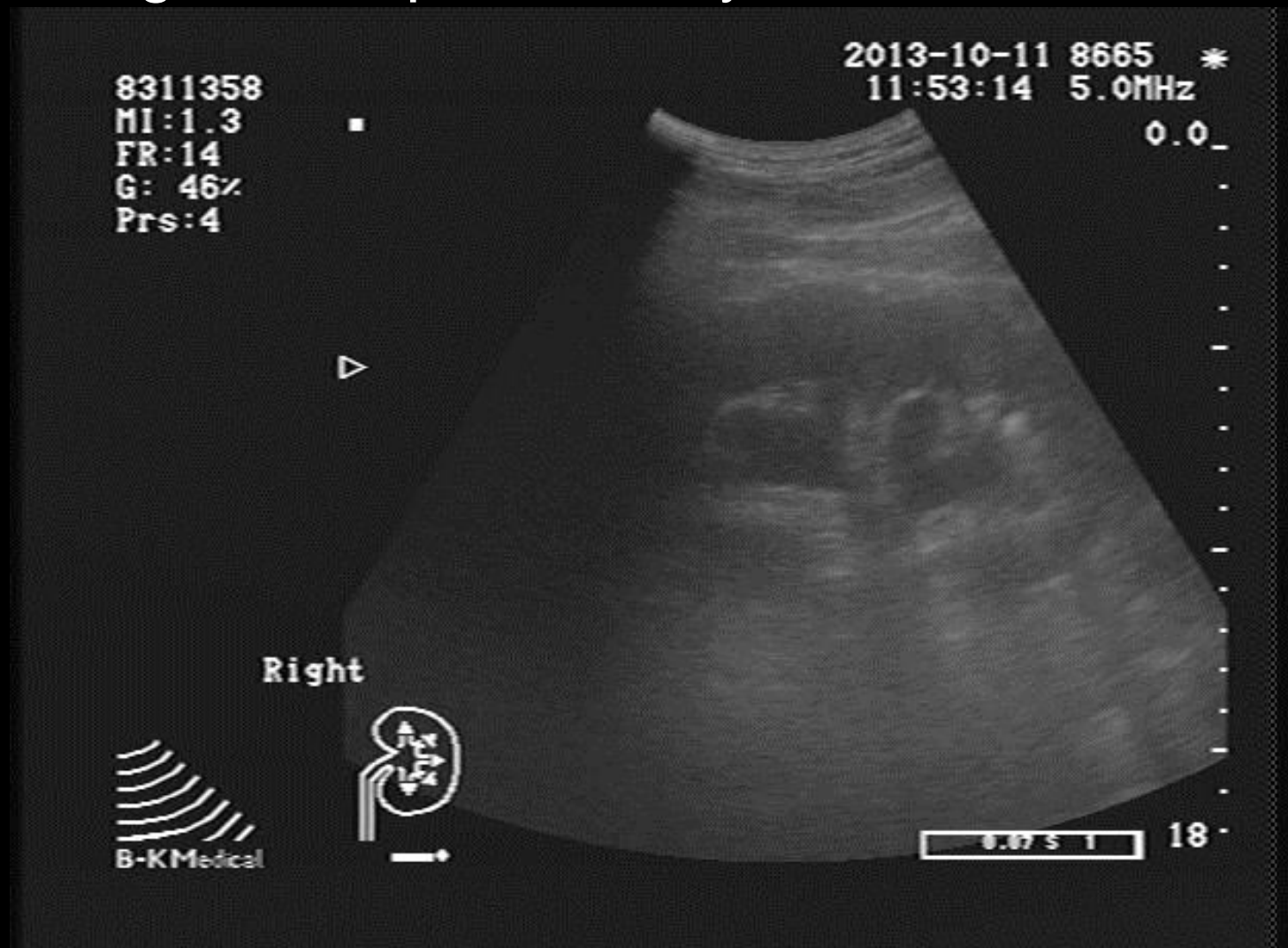**What's the proper impression ?**

Q41-ANS

Portal vein thrombus

Q42

56 Y/O male  
Right flank pain for days



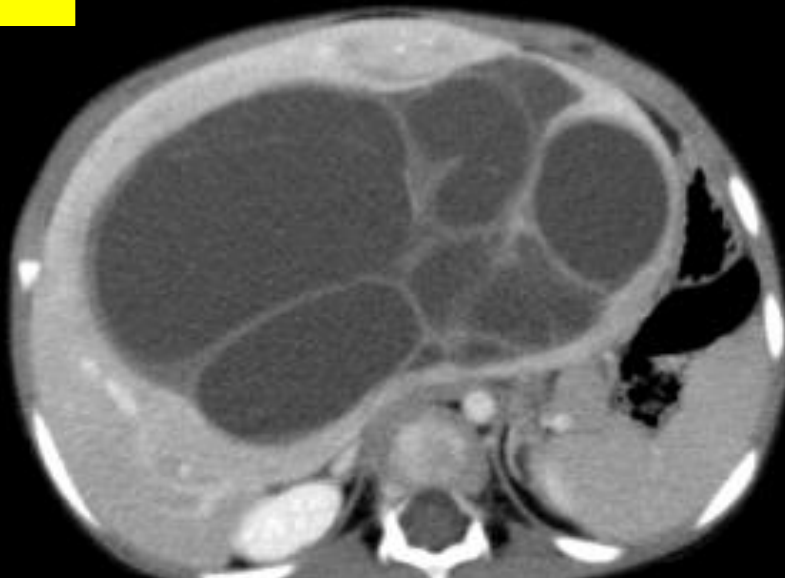What's the proper impression ?

Right renal stone and hydronephrosis

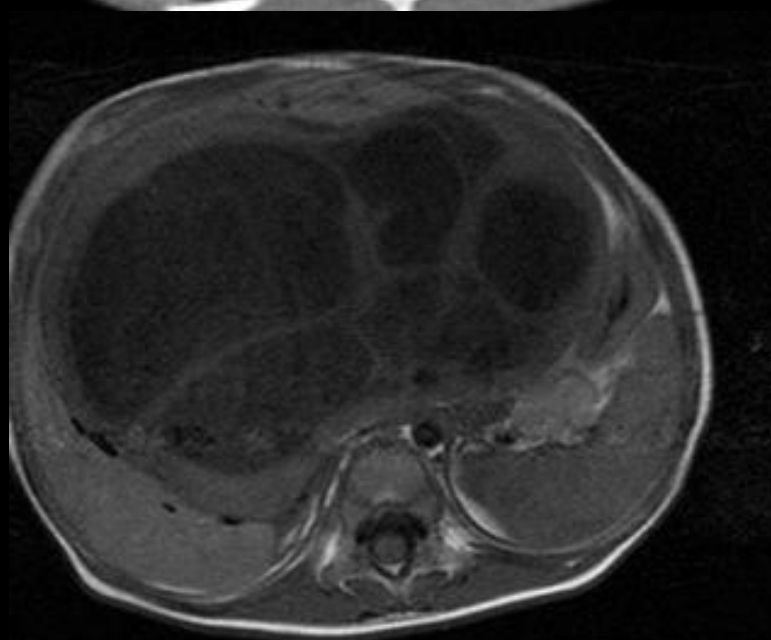
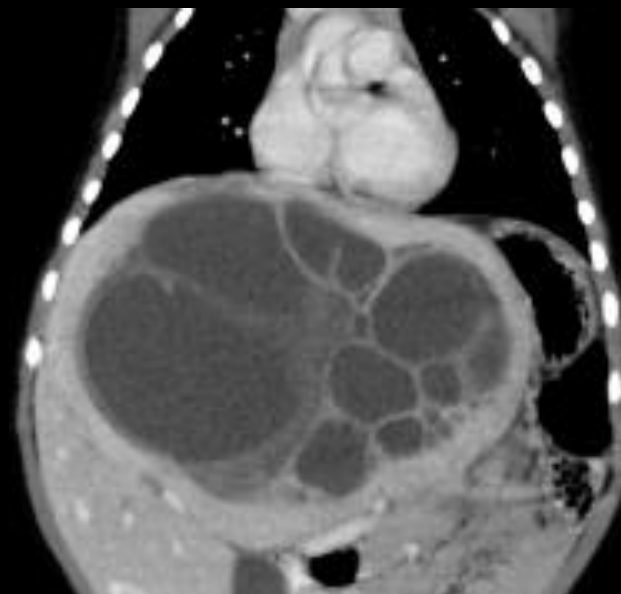


Q43

4-year-old boy



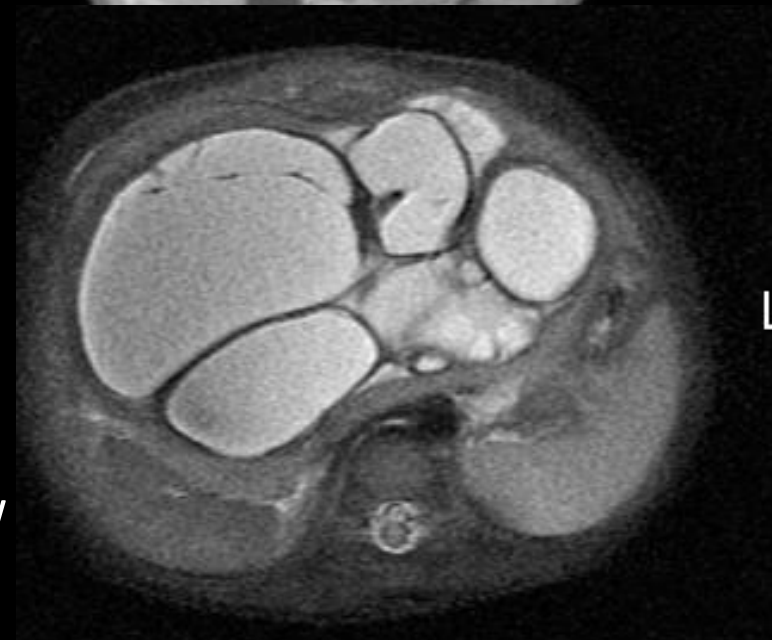L



T1W

L

T2W



L

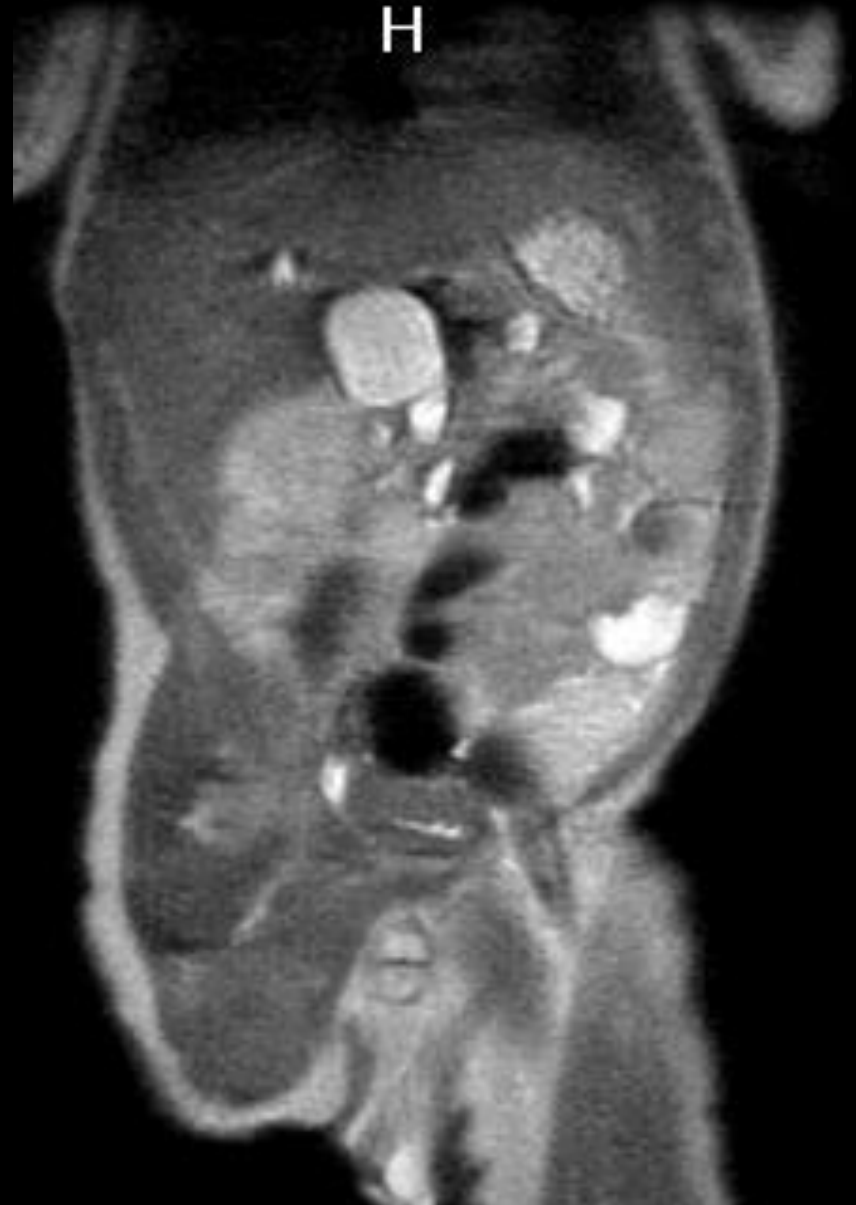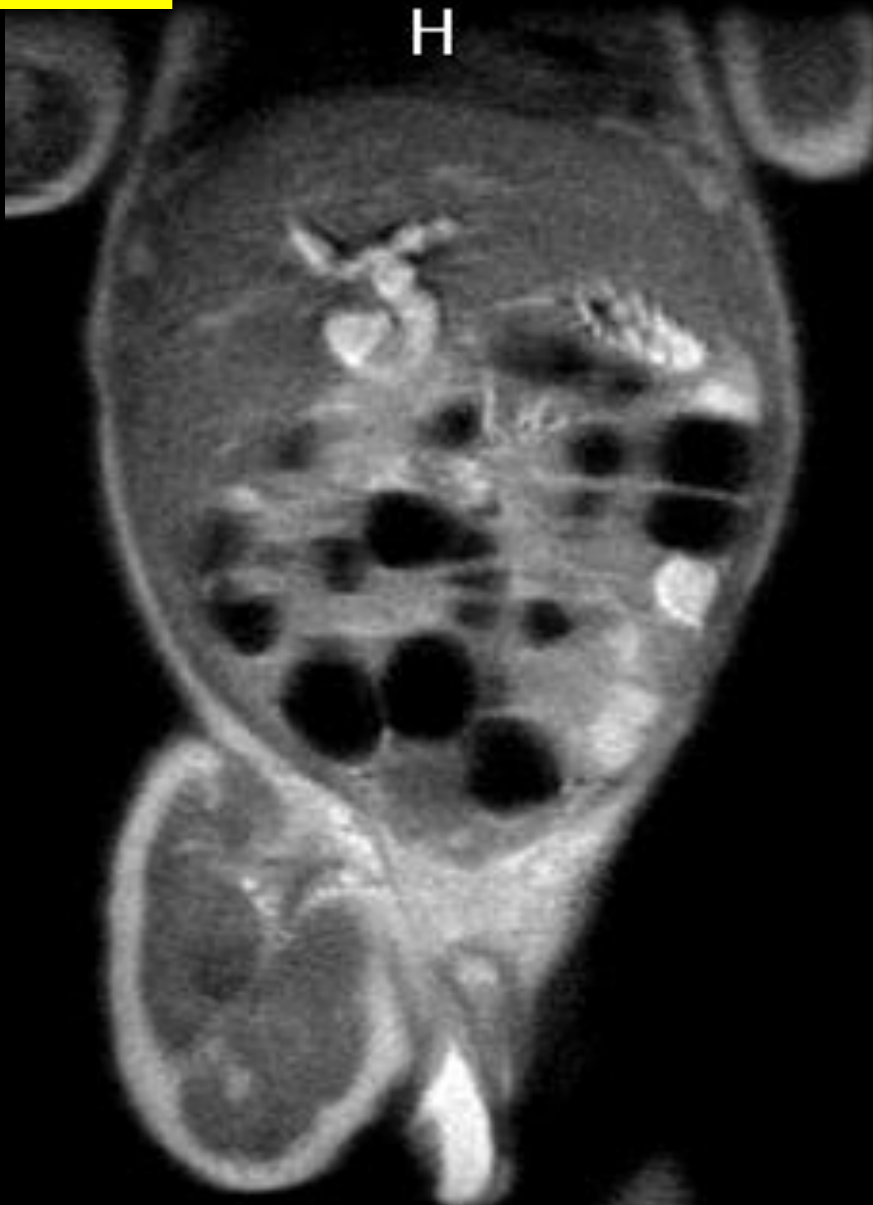
What's the proper impression ?

Q43-ANS

Mesenchymal hamartoma

Q44

1-month-old infant



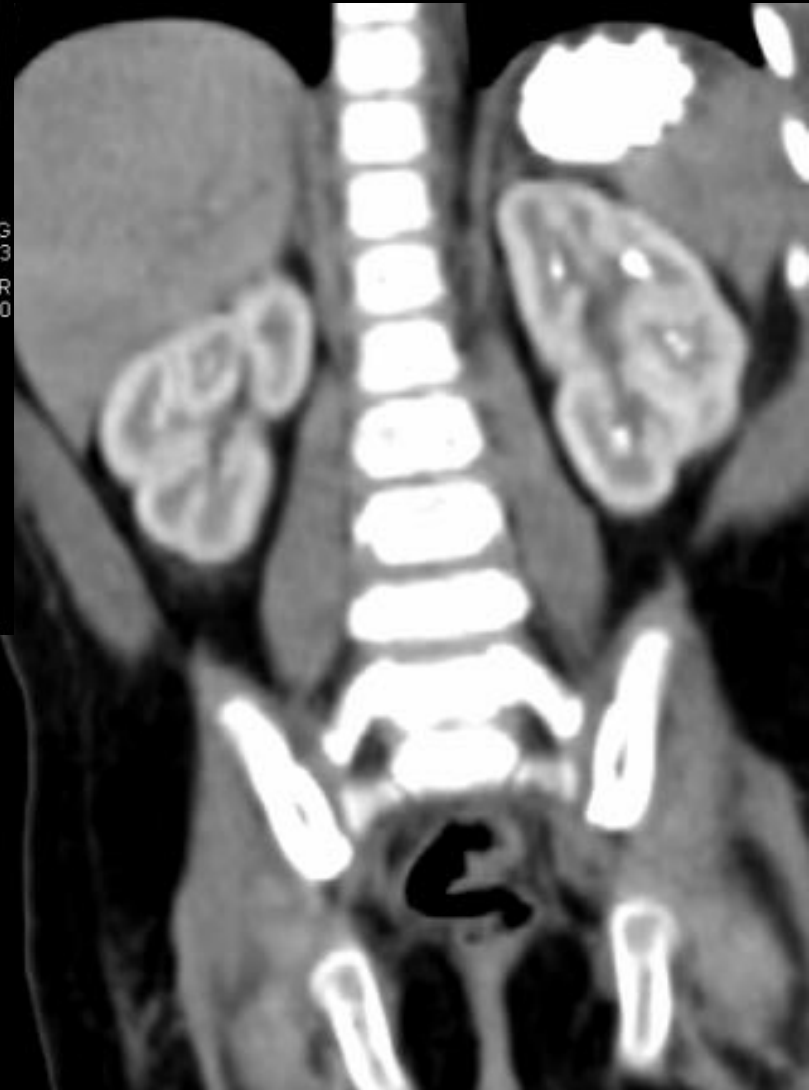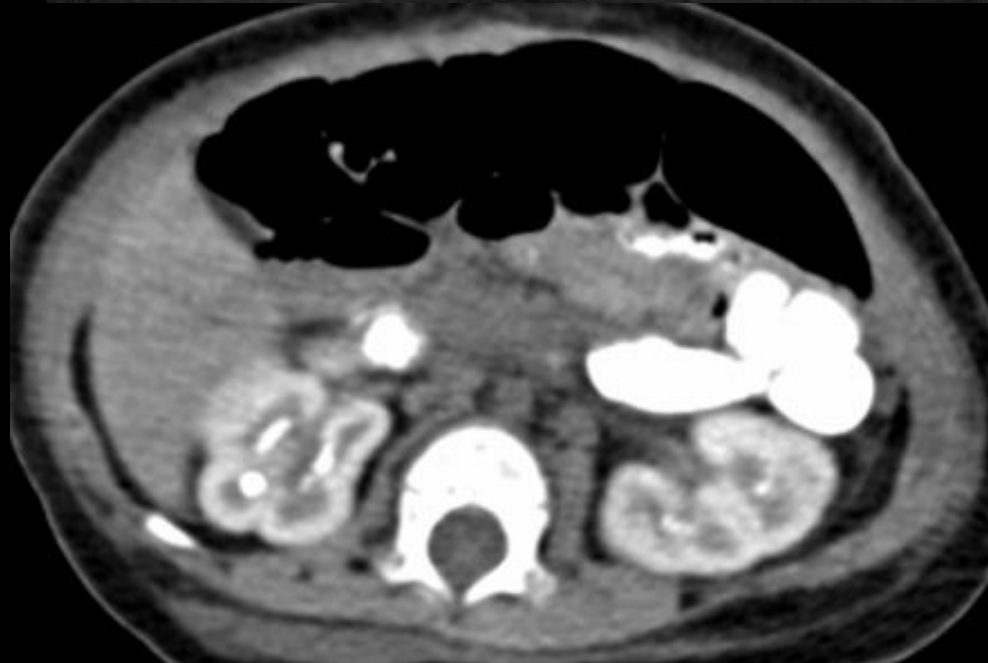
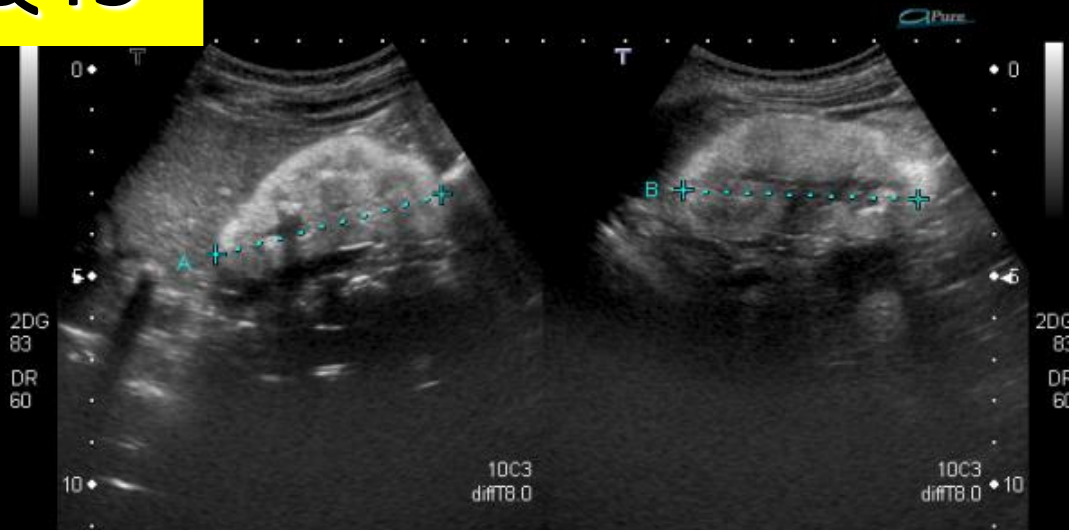
What's the proper impression ?

Q44-ANS

Choledochal cyst

Q45

6-month-old girl

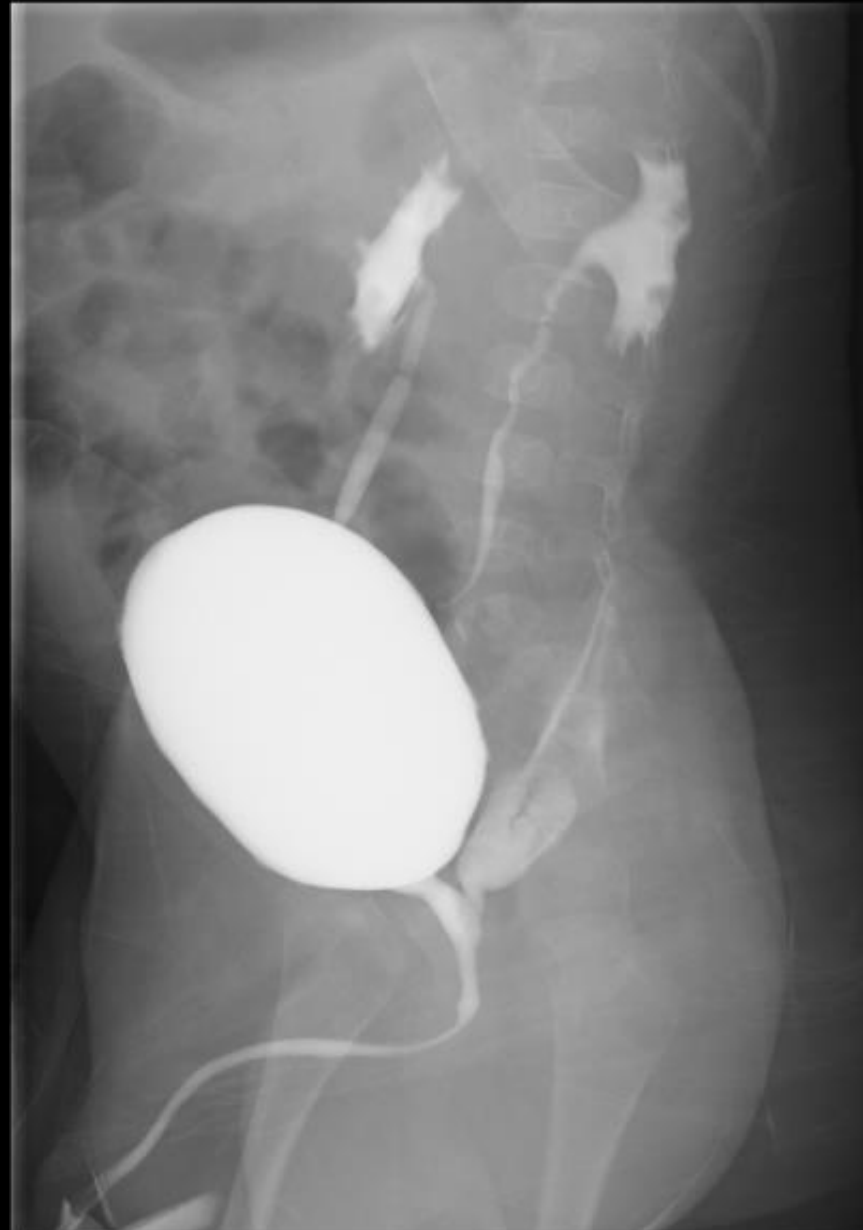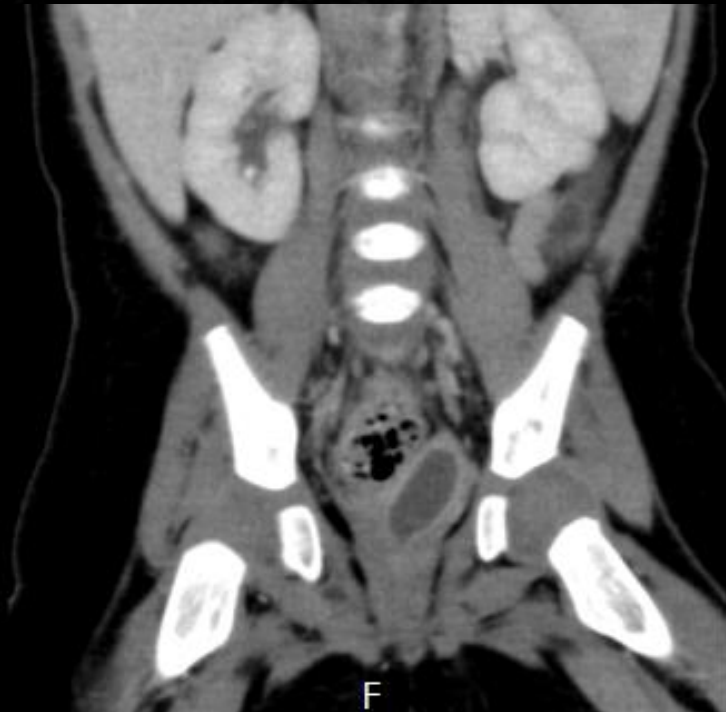
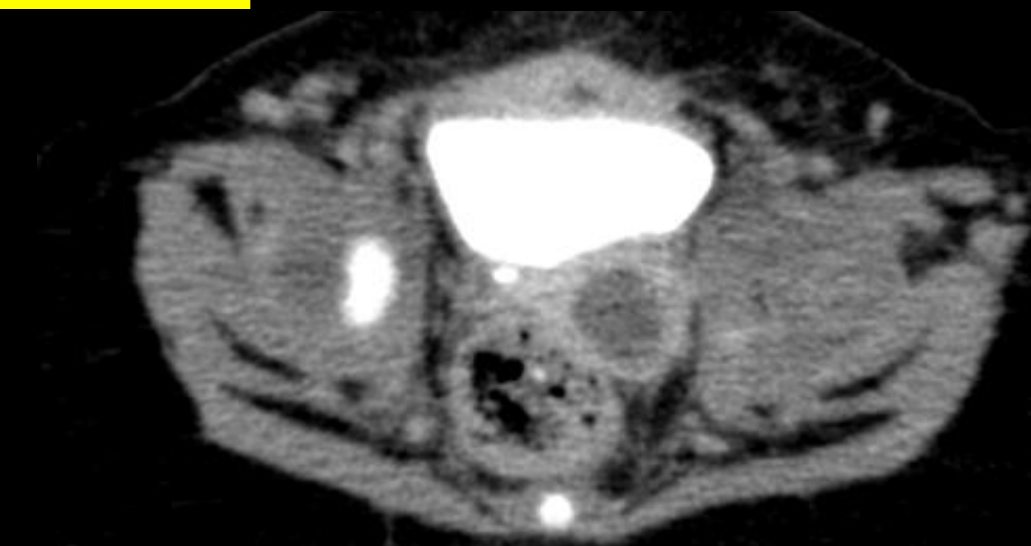


What's the proper impression ?

## Nephrocalcinosis



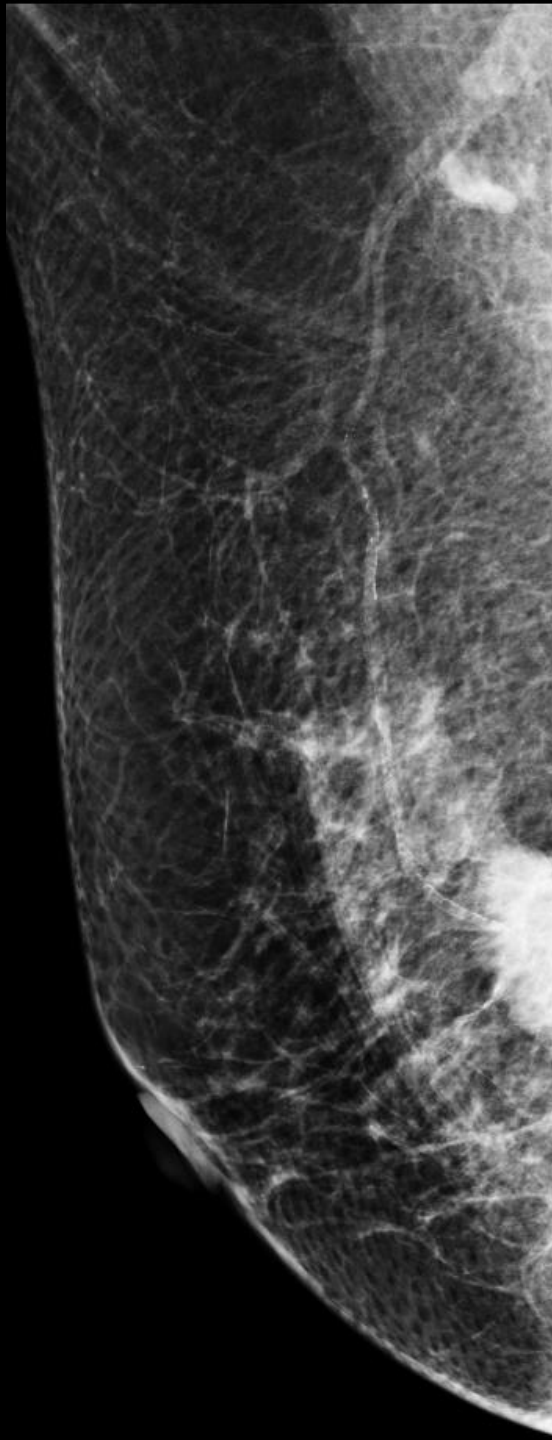
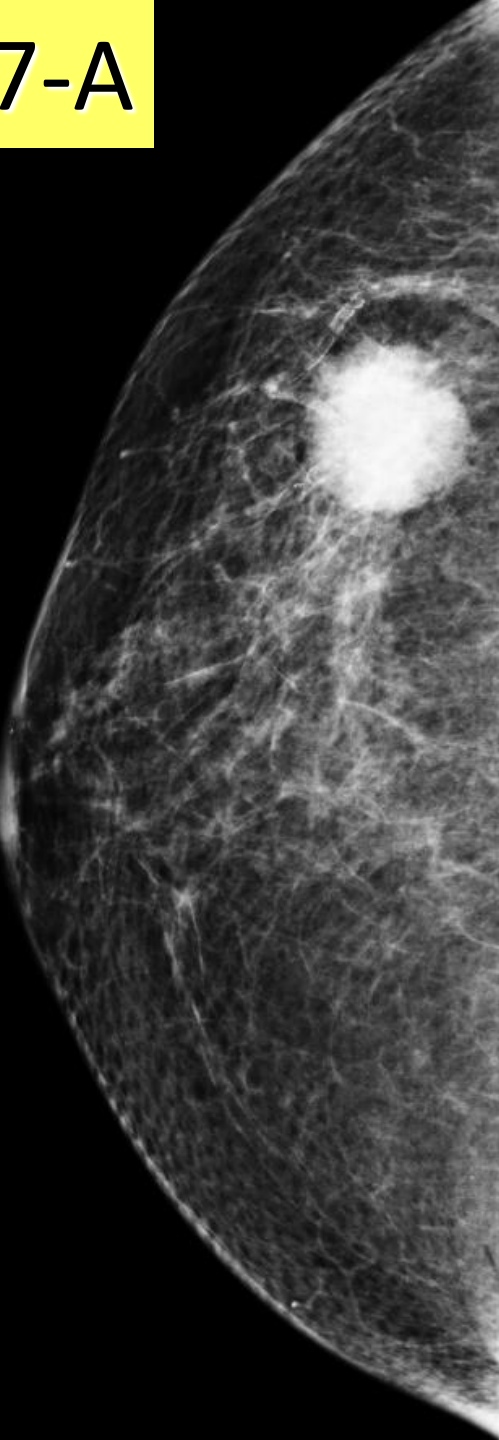
**Q46** 3-month-old boy, recurrent UTI. Findings except VUR



Prostatic utricle cyst

Q47-A

本題有二張投影片，第一張

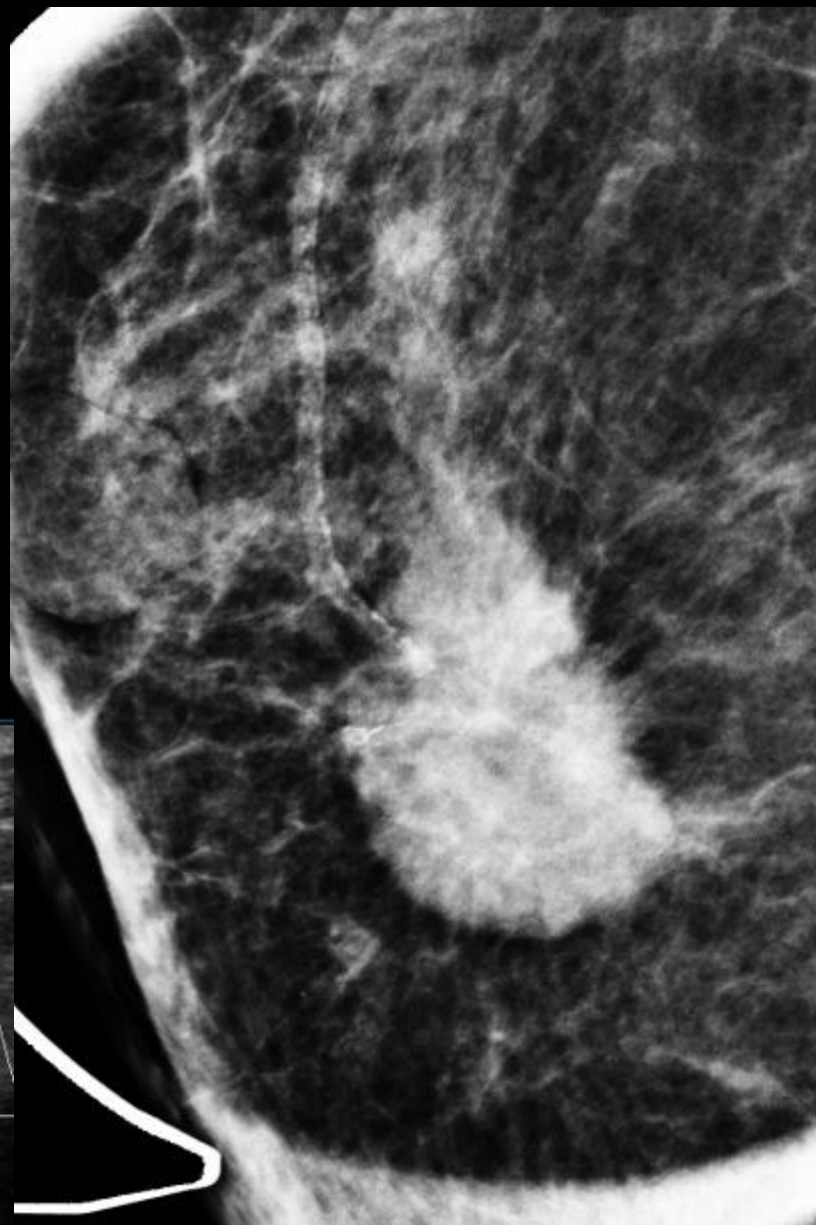
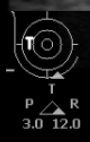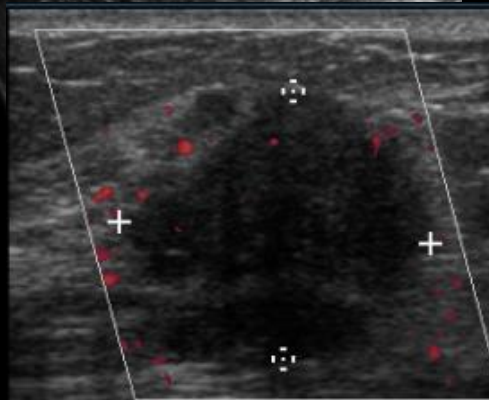
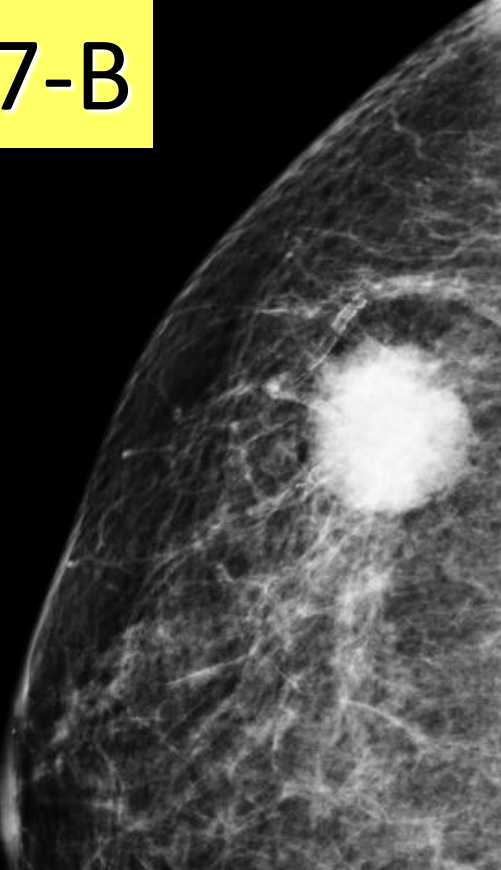


72 Y/O  
Female  
R't breast  
lump

請寫出診  
斷 &  
BI-RADS  
category ?

Q47-B

本題有二張投影片，第二張



72 Y/O  
Female  
R't breast  
lump

請寫出診斷 &  
BI-RADS  
category ?

- Breast cancer
- BI-RADS category 4 or 5

(Path) Invasive ductal carcinoma




Q48-A

51 y/o F Screening mammogram  
請寫出診斷 & BI-RADS category ?

本題有二張投影片，第一張

R CC 2009



R CC 2012



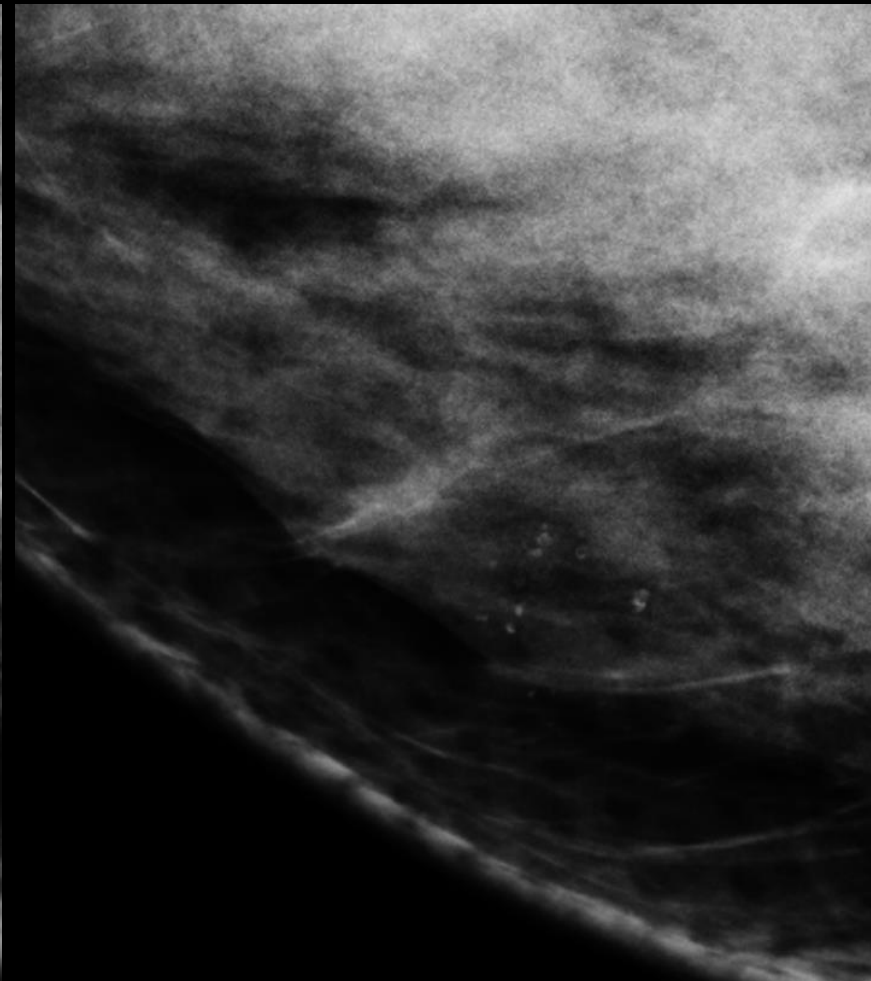
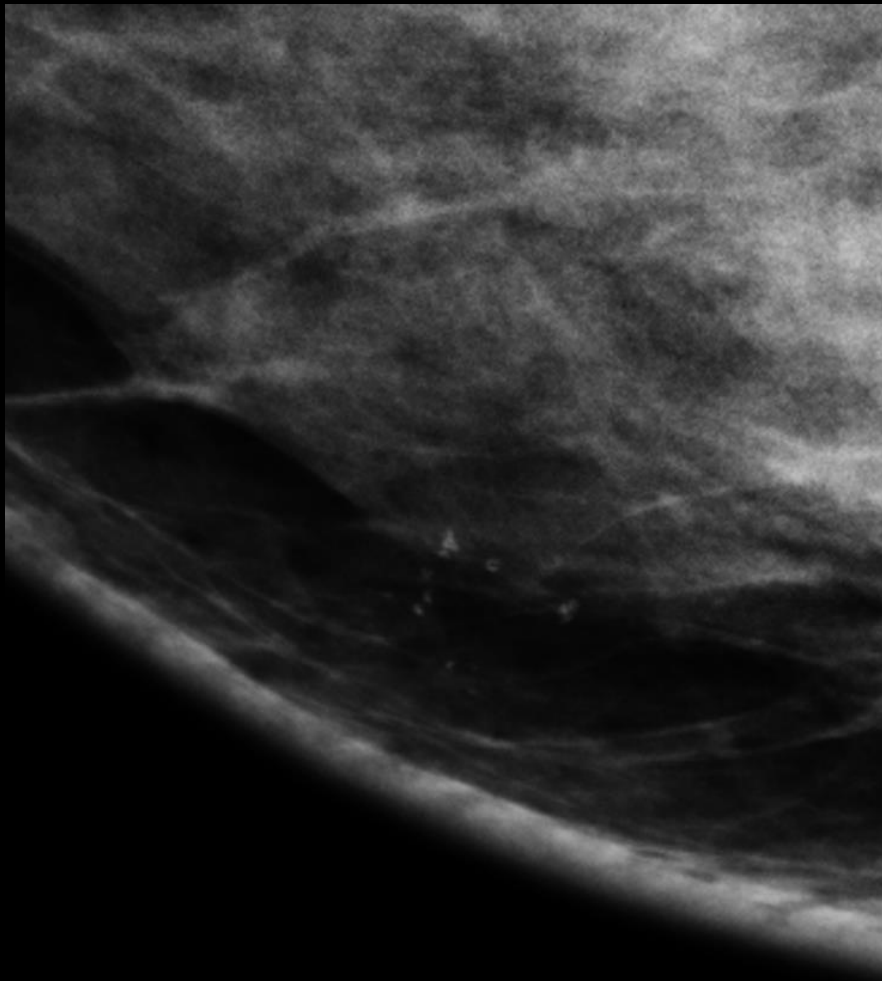


Q48-B

51 Y/O F Screening mammogram  
請寫出診斷 & BI-RADS category ?

R MLO (lower) 2009

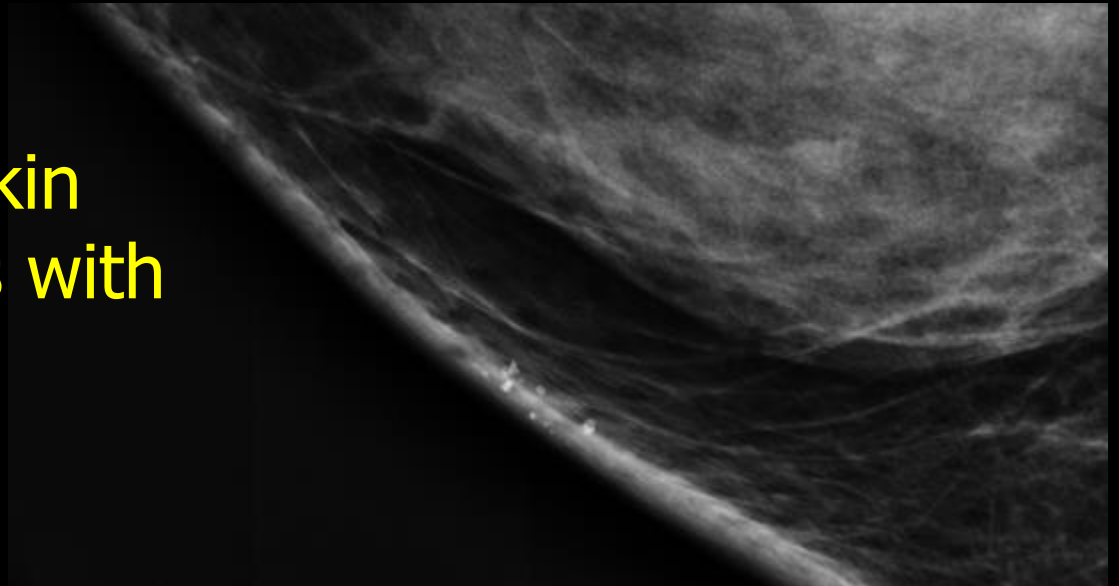
R MLO (lower) 2012



本題有二張投影片，第二張

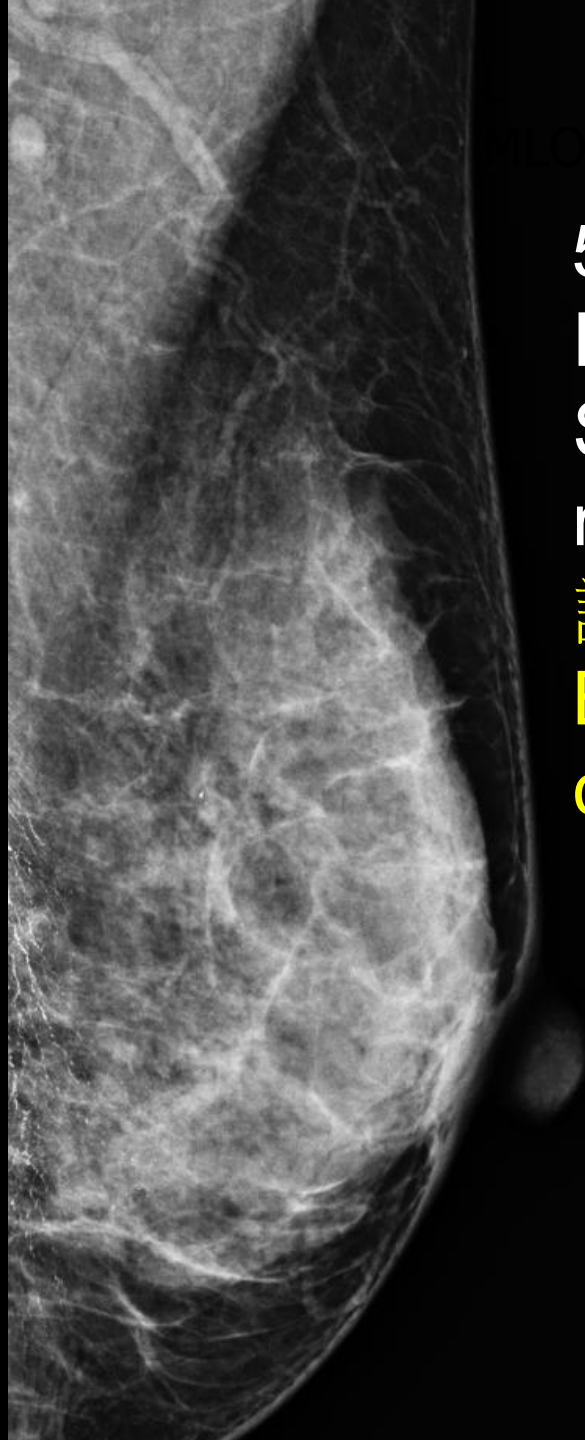
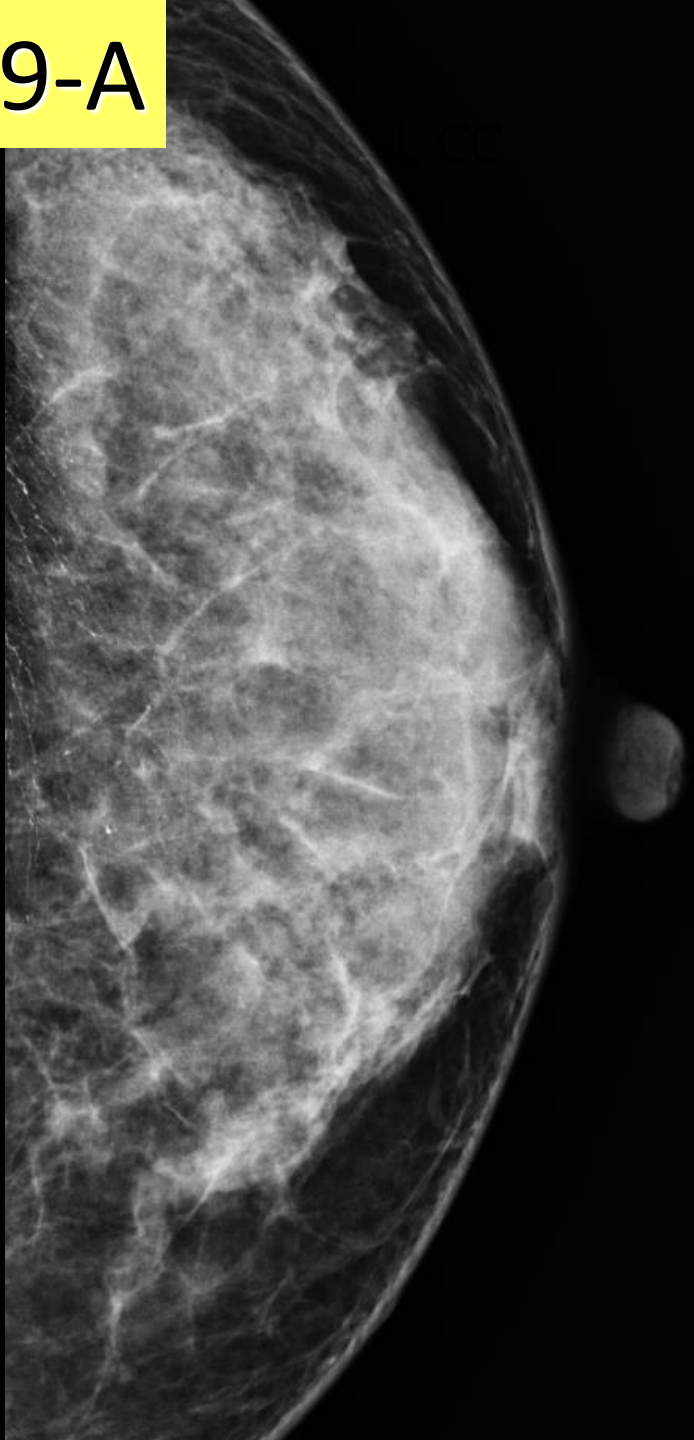
- Benign calcifications  
(or benign skin/dermal calcifications)
- BI-RADS category 2

This case: Skin  
calcifications with  
tattoo sign



Q49-A

本題有二張投影片，第一張

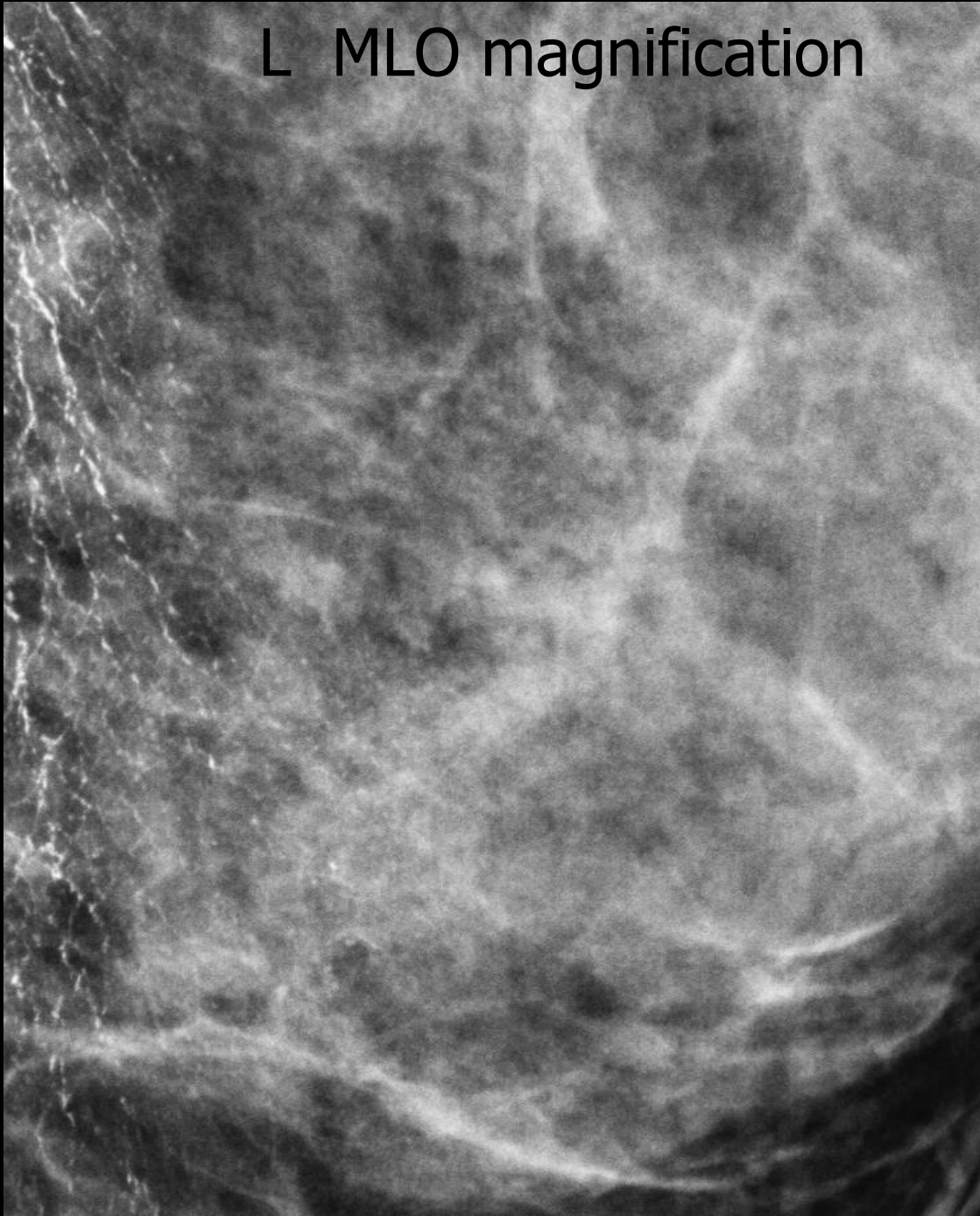


58 Y/O  
Female  
Screening  
mammogram  
請寫出診斷 &  
BI-RADS  
category ?

Q49-B

本題有二張投影片，第二張

L MLO magnification



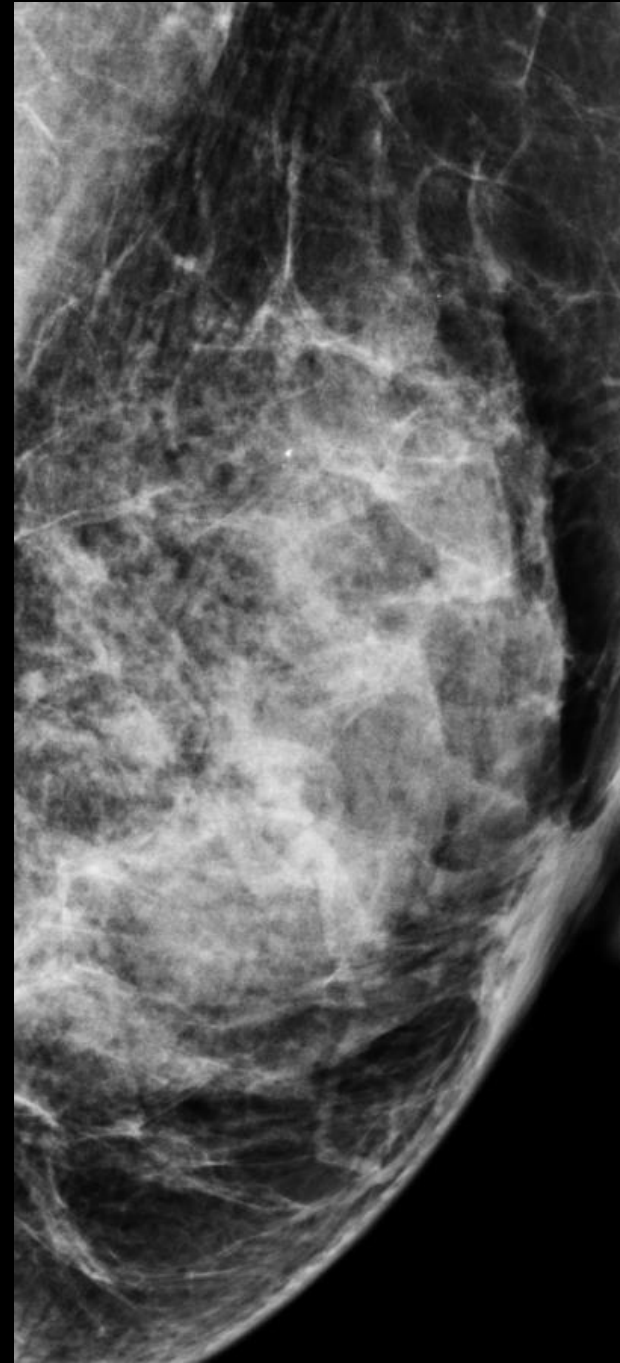
58 Y/O  
Female  
Screening  
Mammogram

請寫出診斷 &  
BI-RADS  
category ?



- Benign skin / dermal calcifications or Artifacts
- BI-RADS category 0 or 2

This case: Artifacts  
due to antiperspirant  
(Repeated  
mammogram:  
Disappearance of the  
artifacts)



Q50-A

R MLO

本題有二張投影片，第一張

L  
MLO

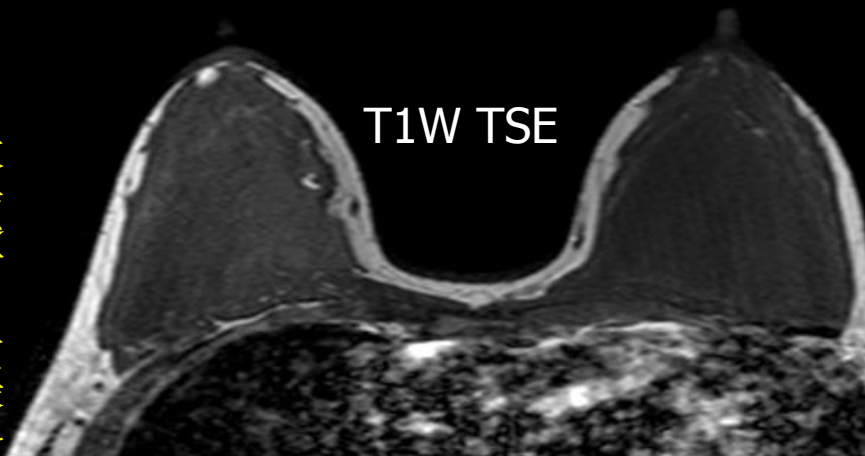
30 Y/O Female  
Bilateral breast  
lumps  
(previous  
injection  
mammoplasty in  
Mainland China  
9 years ago)

請寫出 **injected  
material**

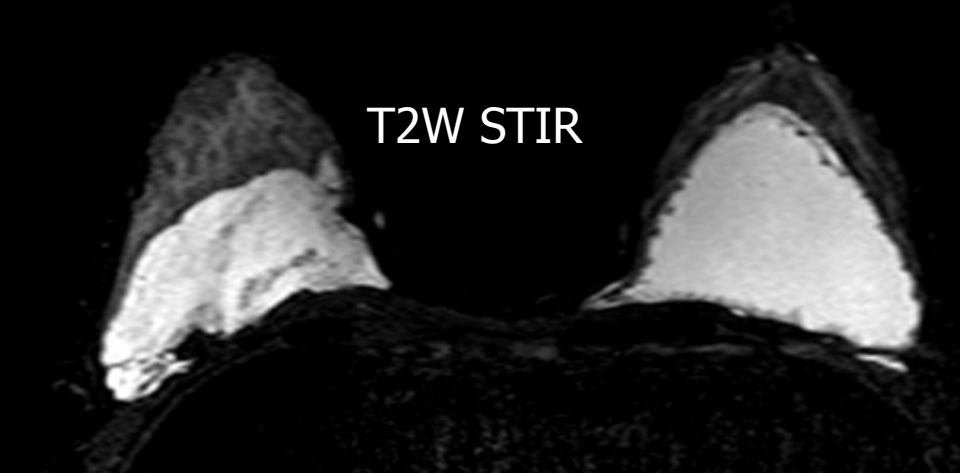
Q50-B

30 Y/O Female Bilateral breast lumps (previous  
injection mammoplasty in Mainland China 9 years ago)  
請寫出 **injected material**

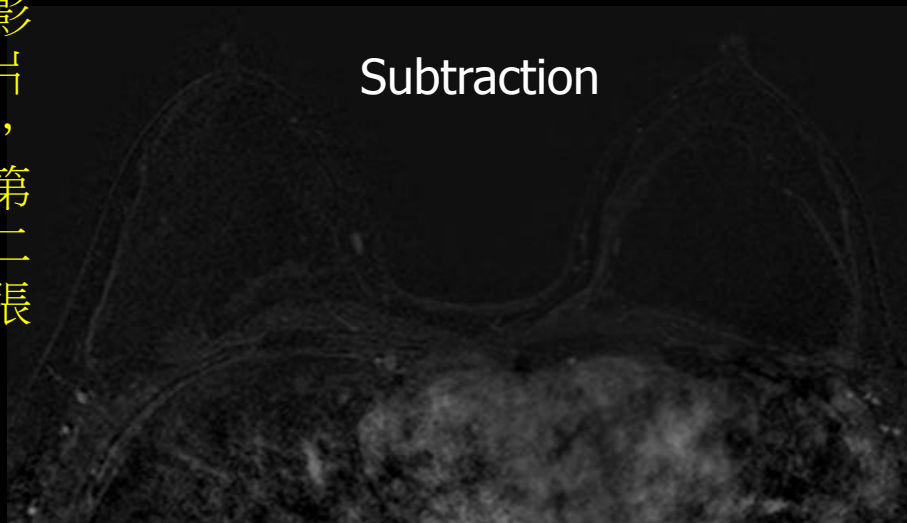
T1W TSE



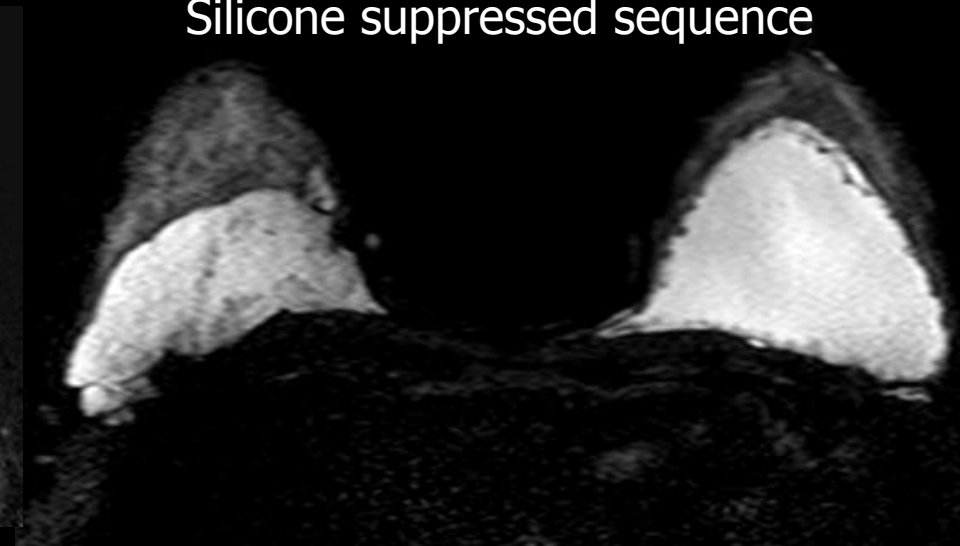
T2W STIR



Subtraction



Silicone suppressed sequence



本題有二張投影片，第二張

R



- Polyacrylamide gel (PAAG)  
(又稱奧美定 or 人造脂肪)