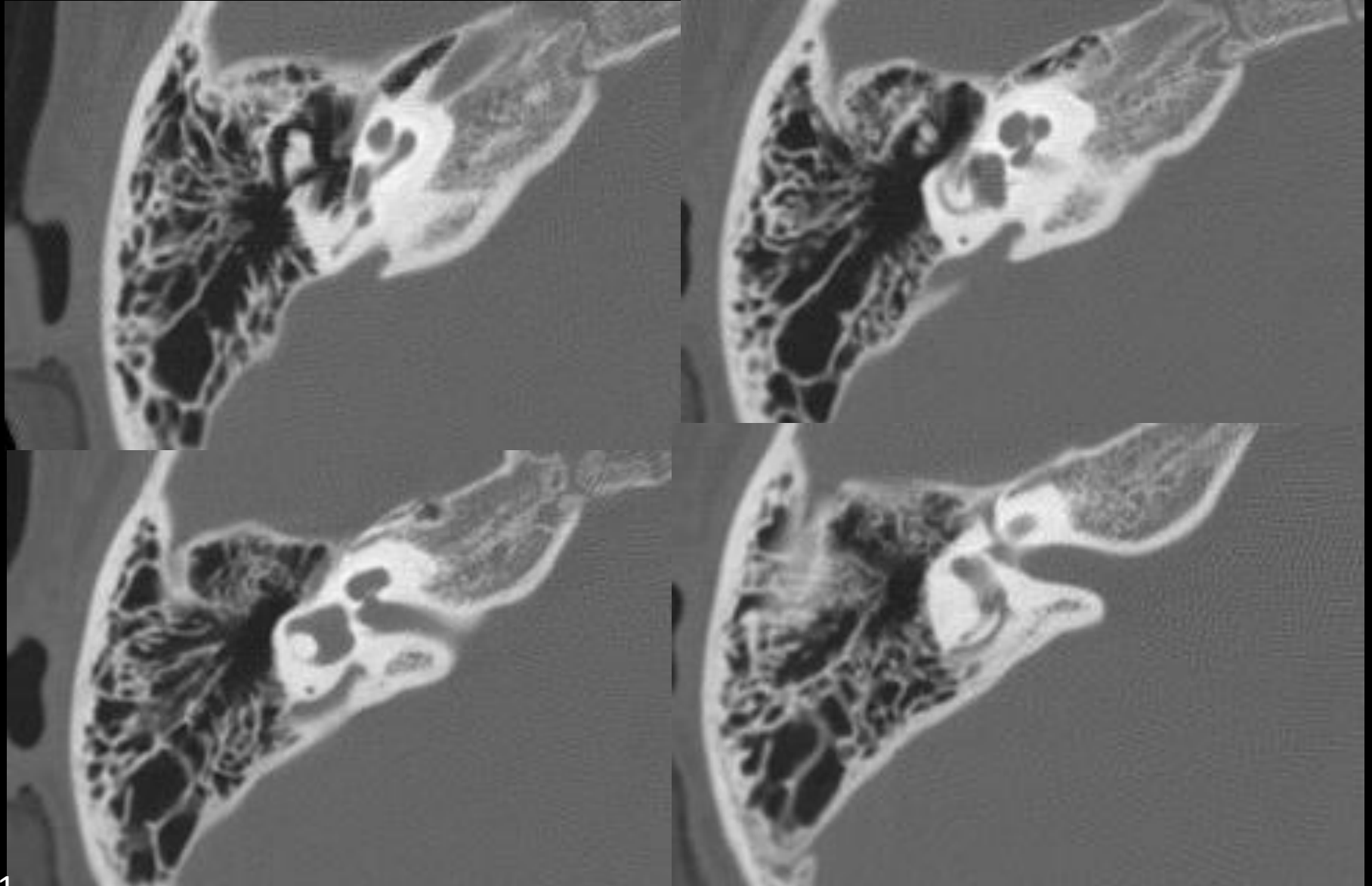
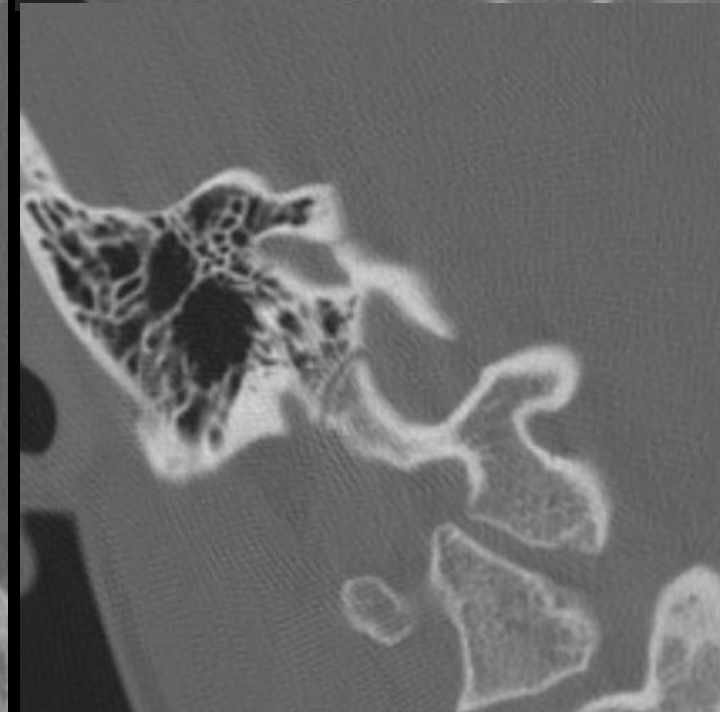
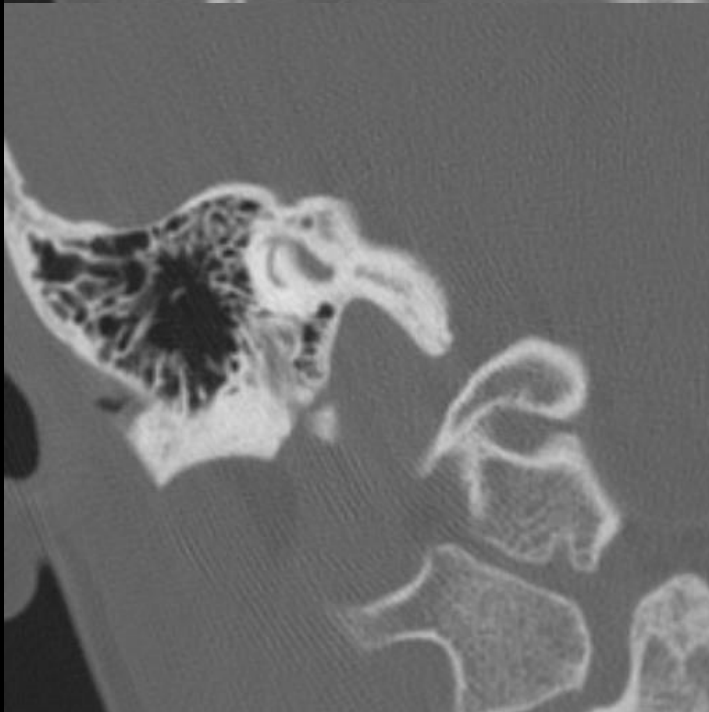
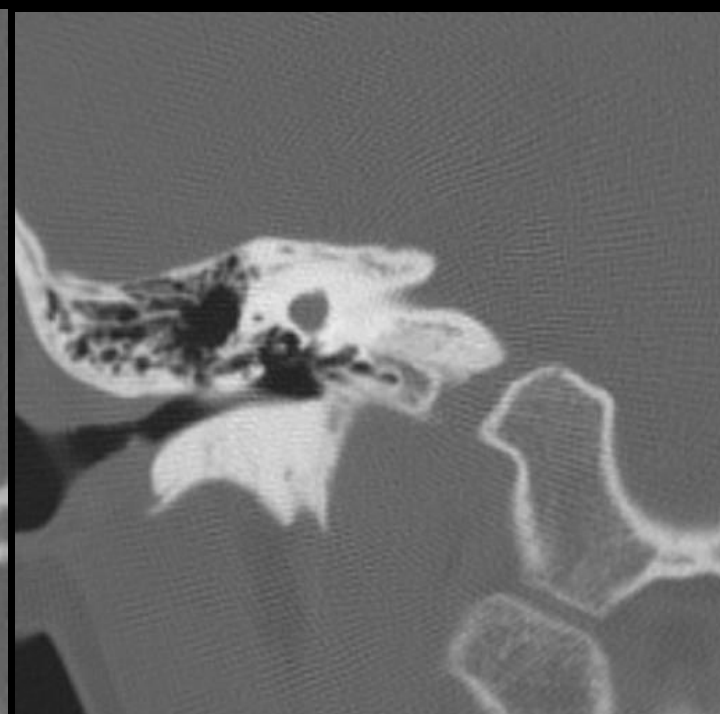
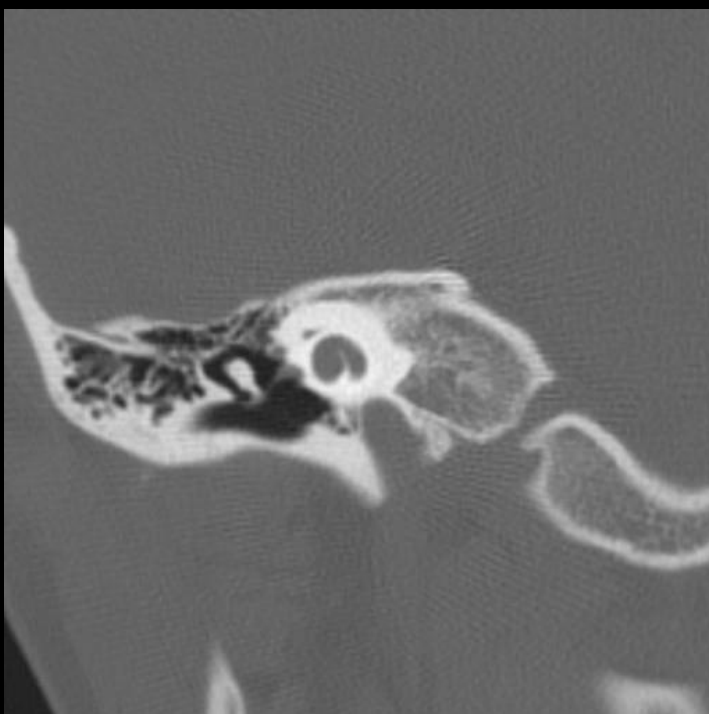

2015年11月20日
中華民國放射線醫學會
住院醫師閱片測驗-答案

出題醫院：
台北市立萬芳醫院影像醫學部

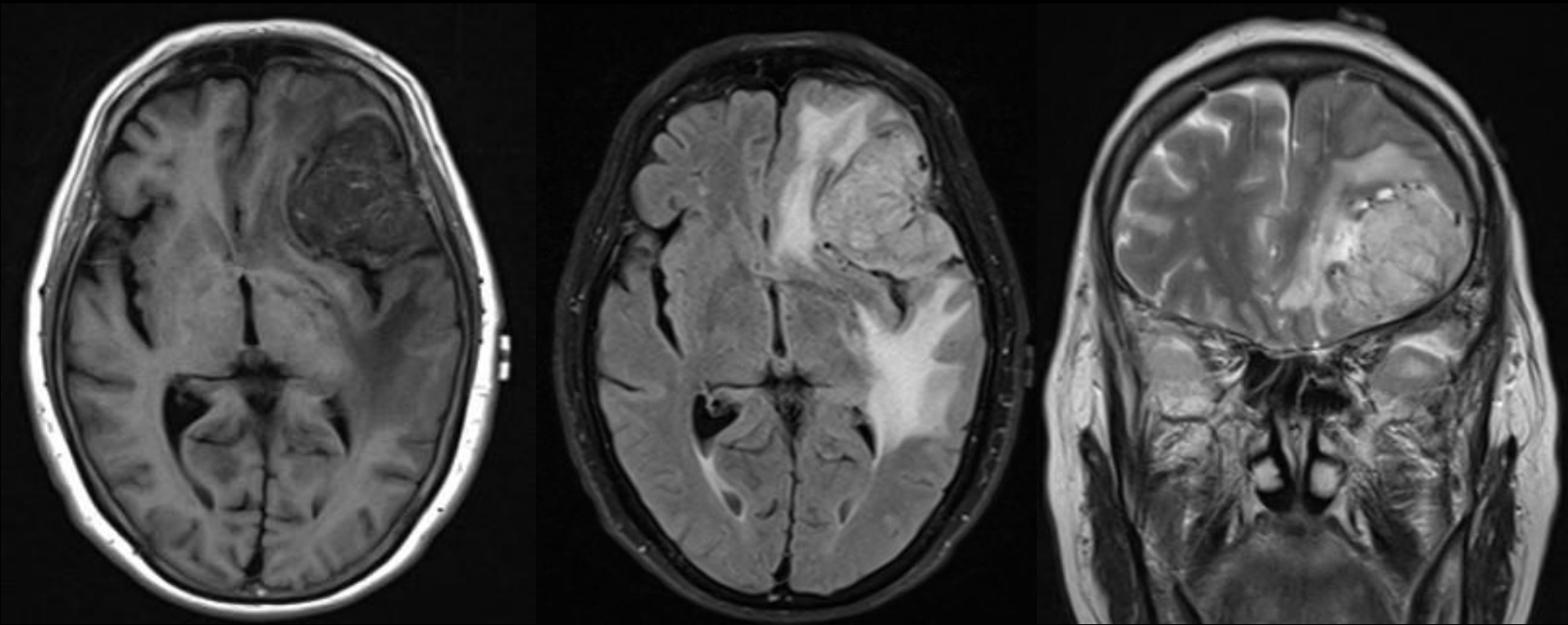
Q01 11 y/o Female, right stuffy ear with hearing loss,
What is your Diagnosis?

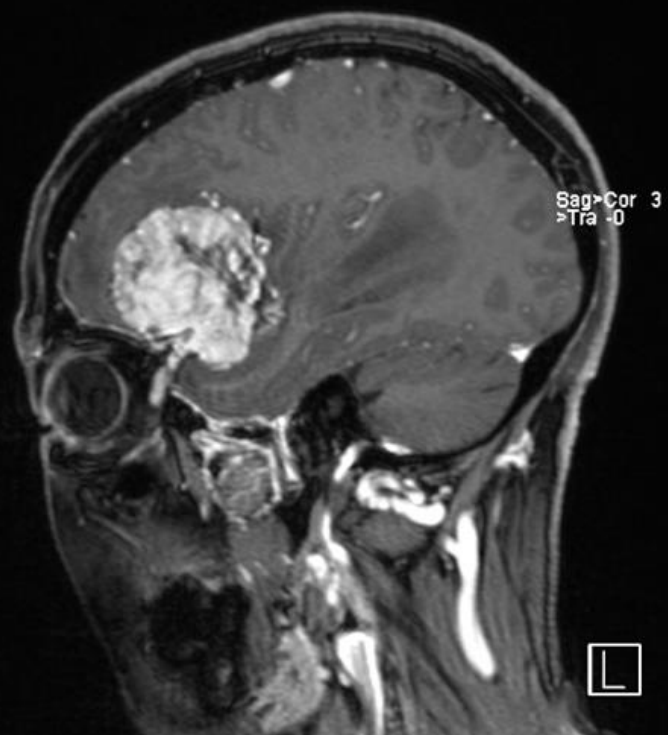
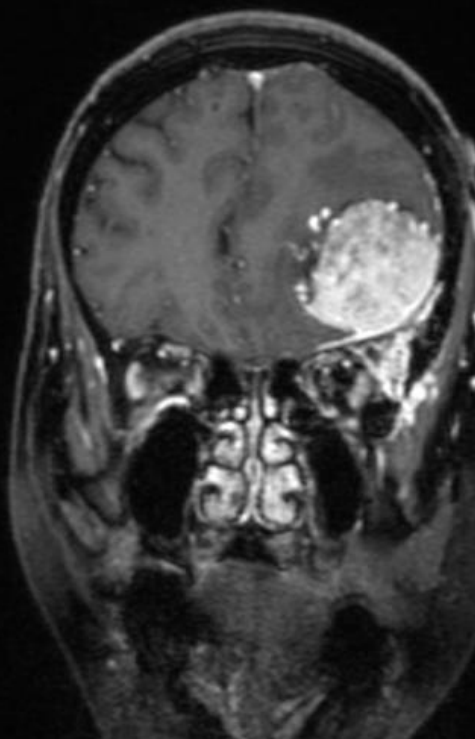
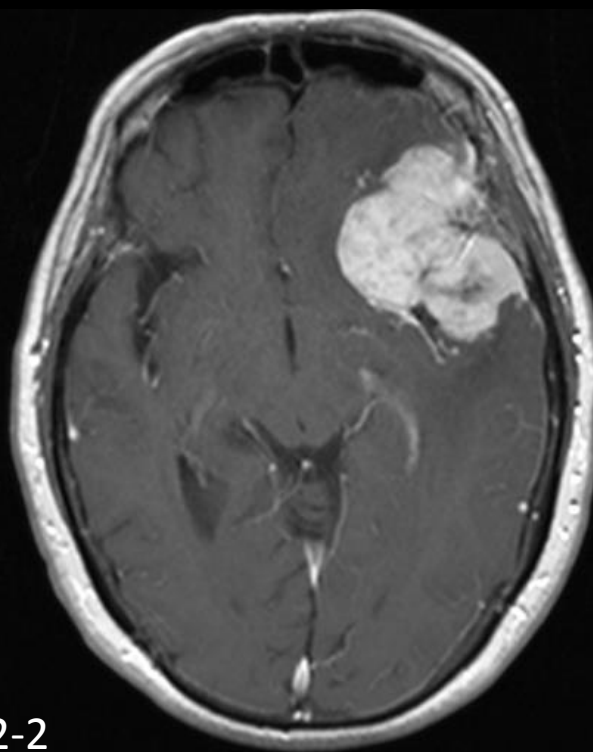
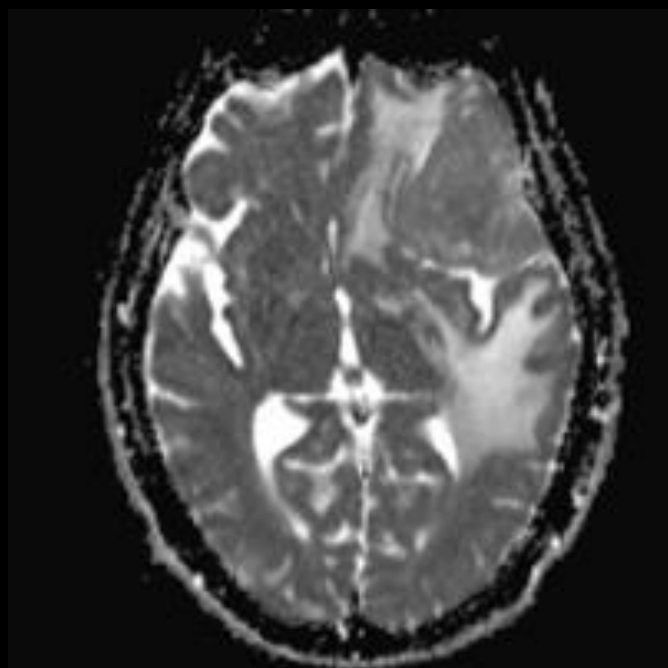
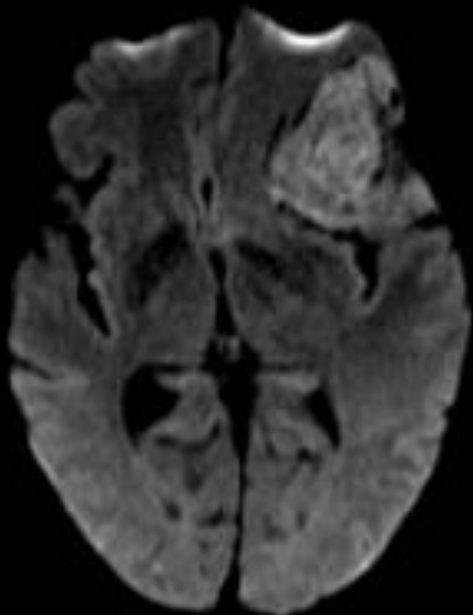




Answer:
Mondini malformation

Q02 63 y/o Female, seizure attack, What is your Diagnosis?

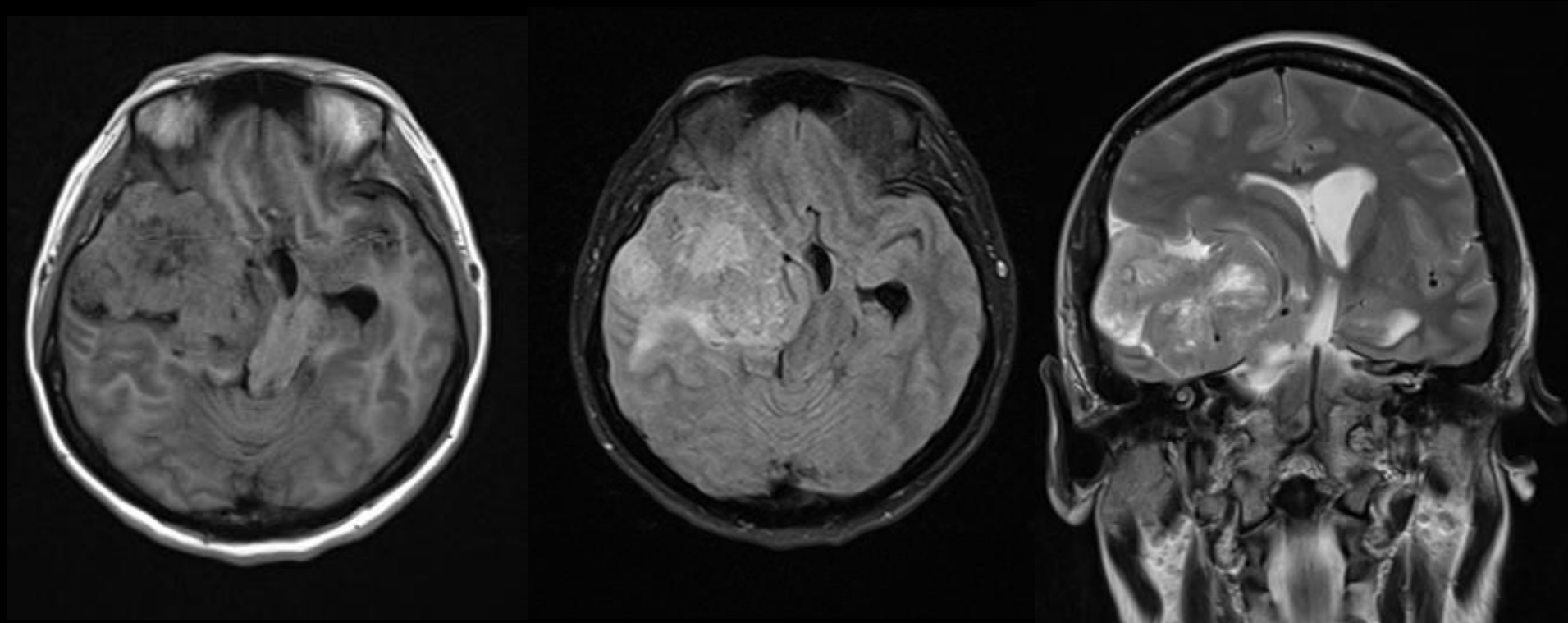


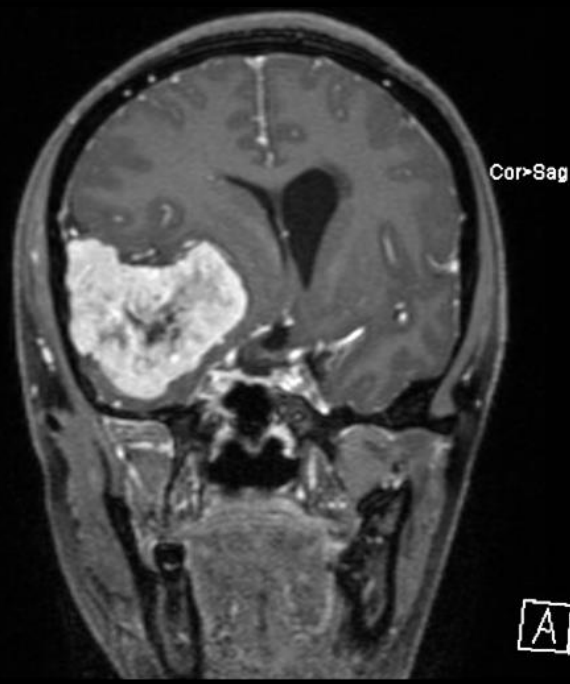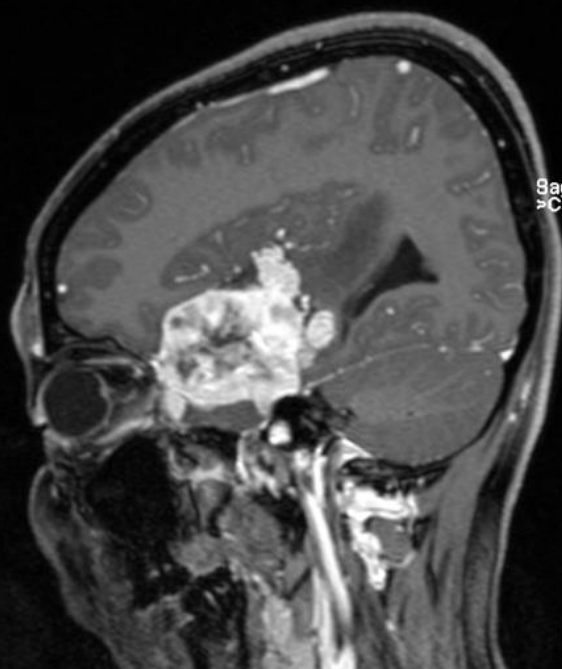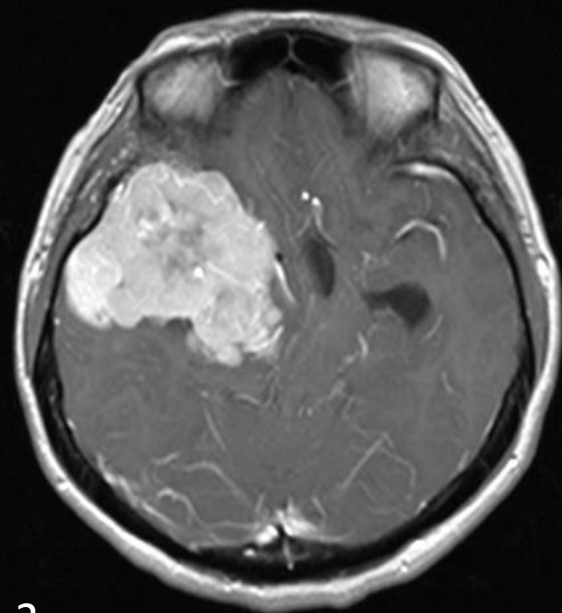
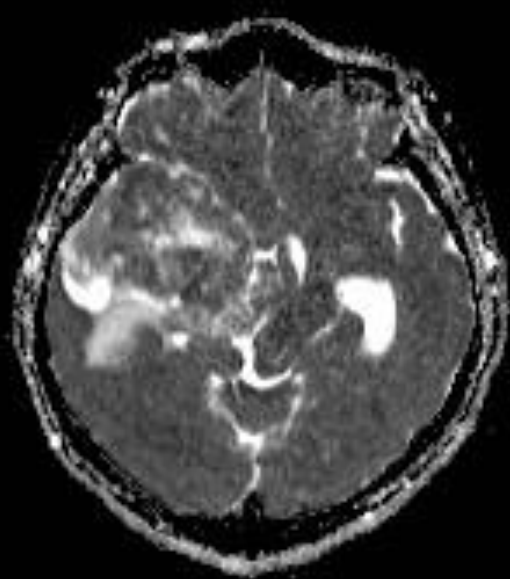
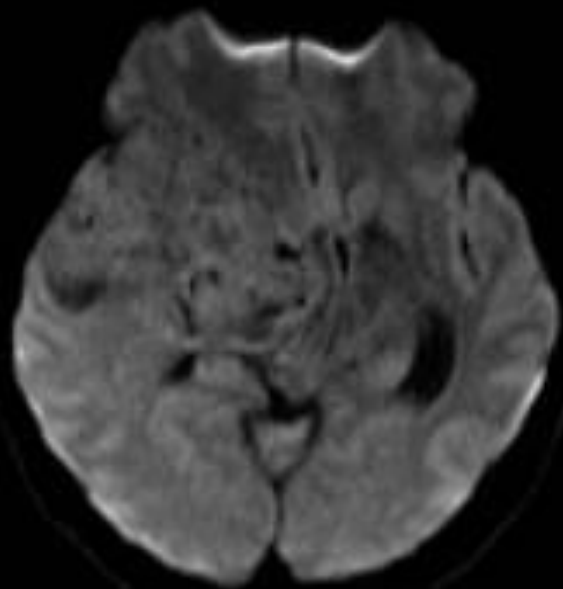


Answer:

Meningioma (microcystic type)

Q03 41 y/o Female, headache & dizziness, What is your Diagnosis?

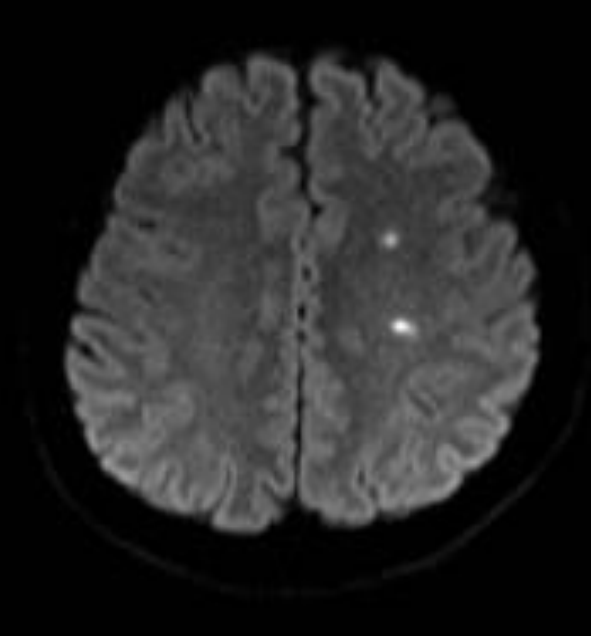
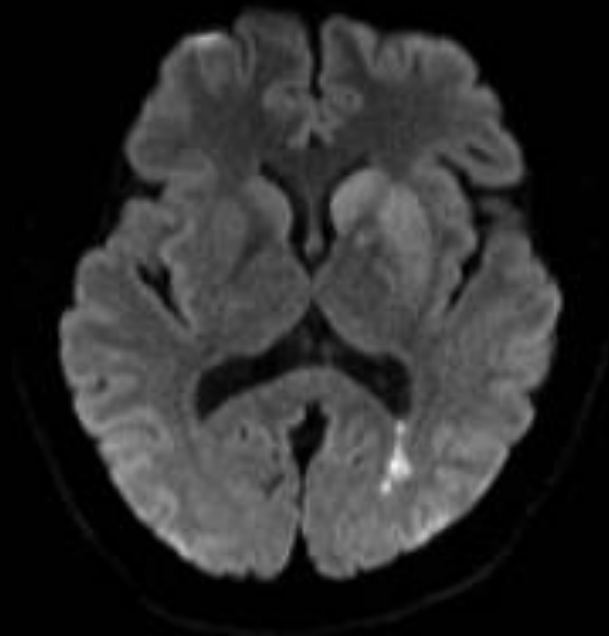
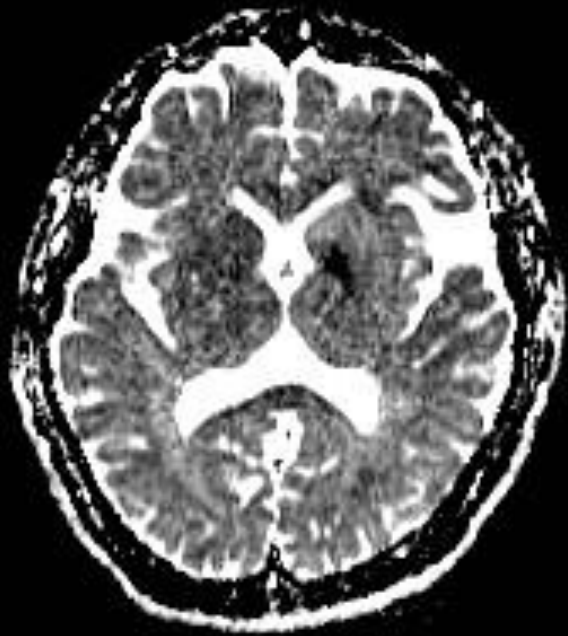

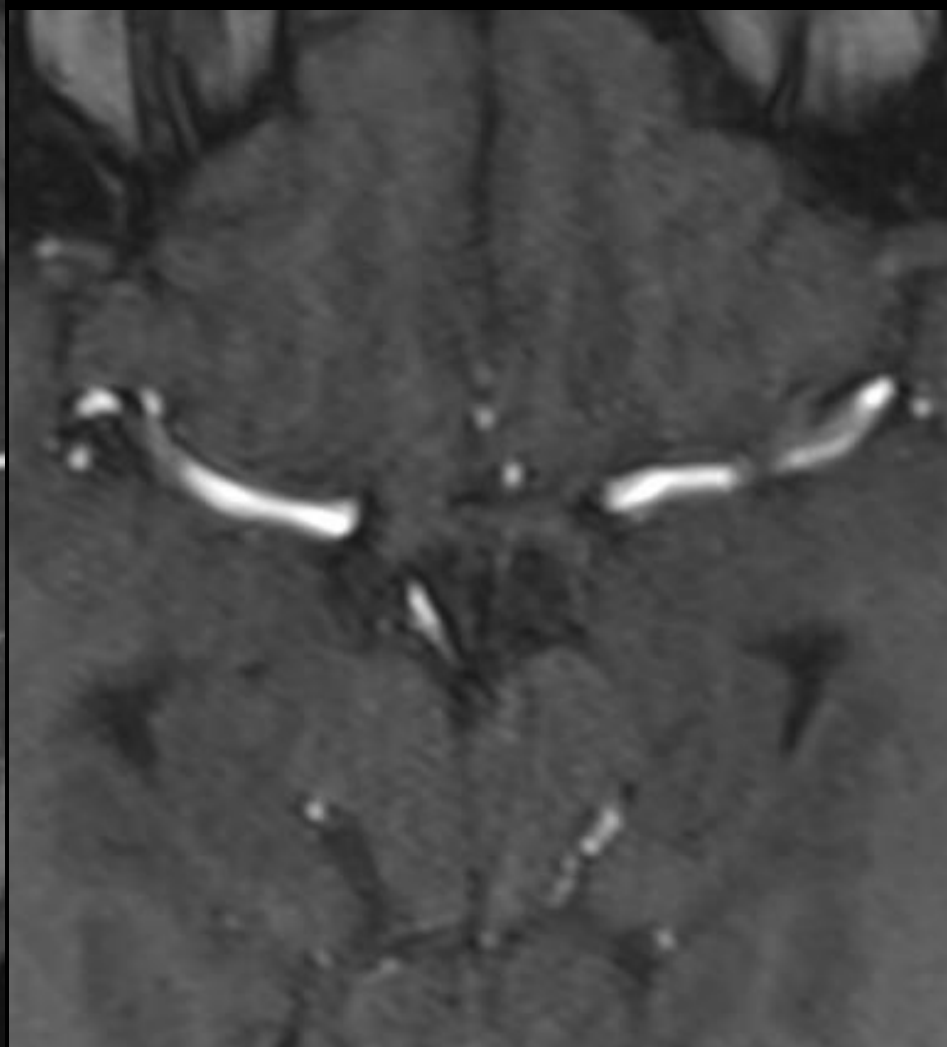

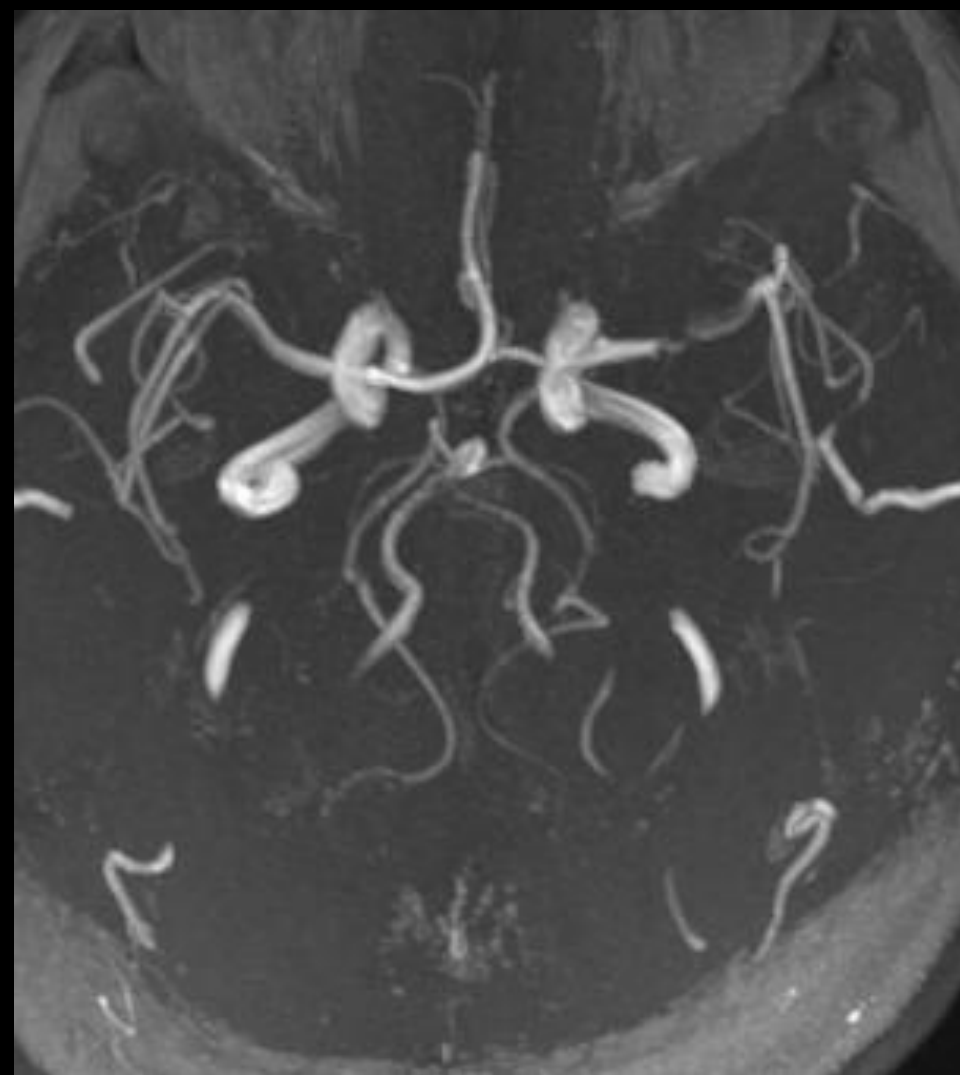
A03

Answer:
hemangiopericytoma

Q04 37 y/o male, sudden right limb weakness for 10 mins, What is your Diagnosis?

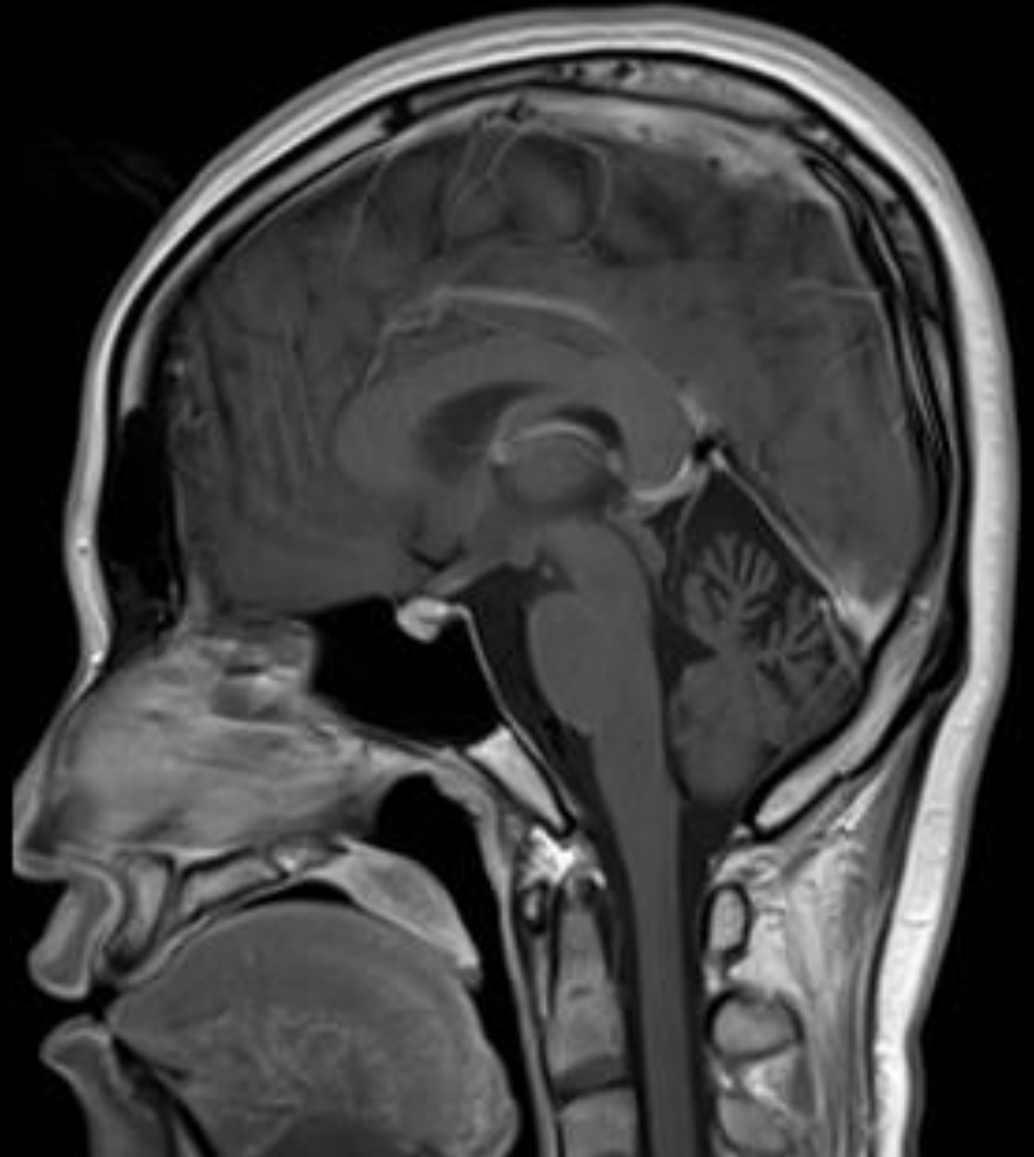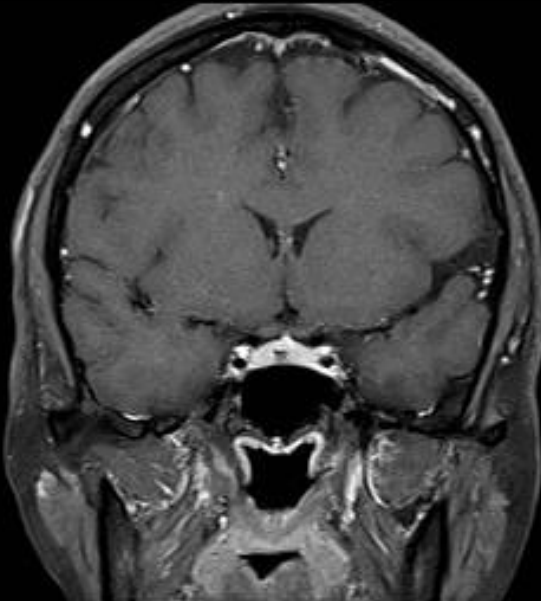
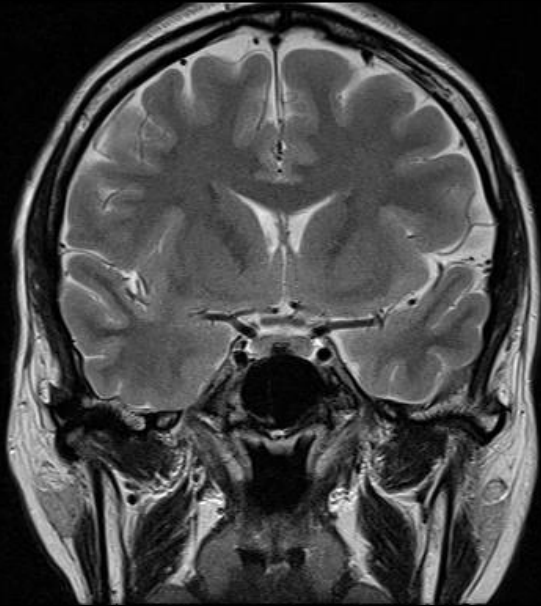


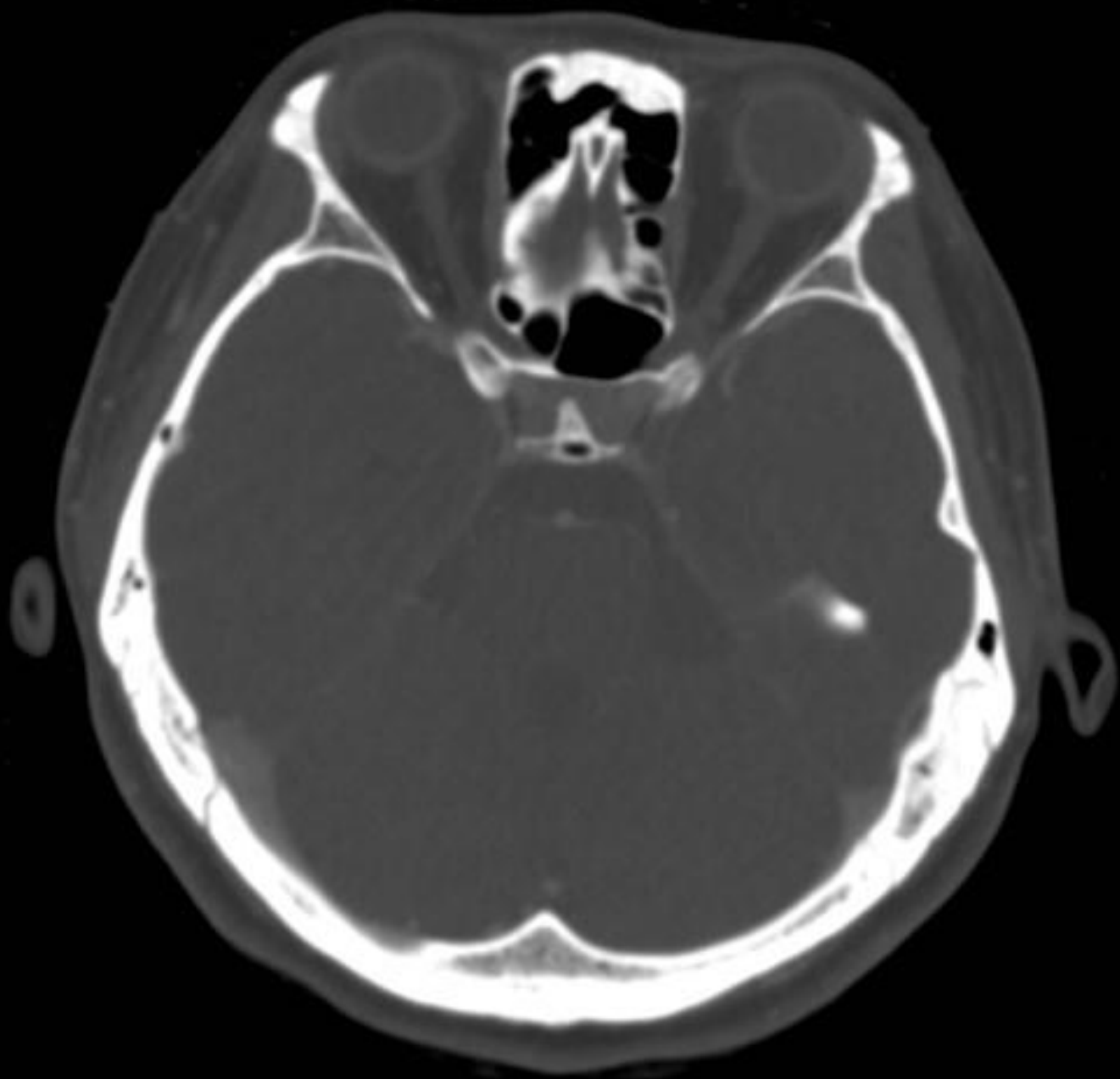


Answer:

Left MCA dissection and brain infarct

Q05 32 y/o Female, incidental finding, What is your Diagnosis?

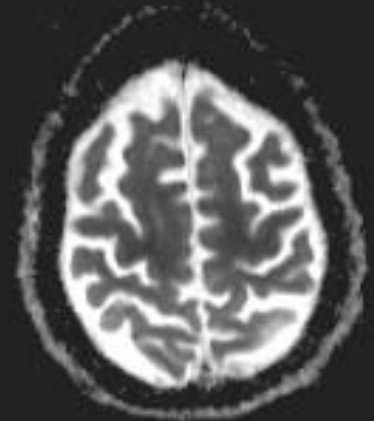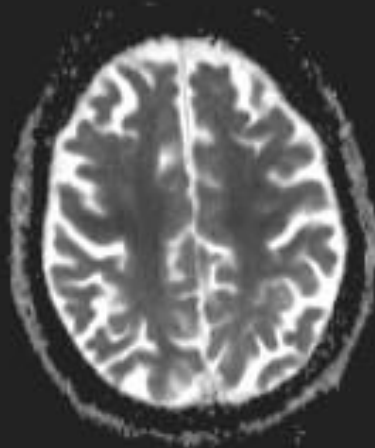
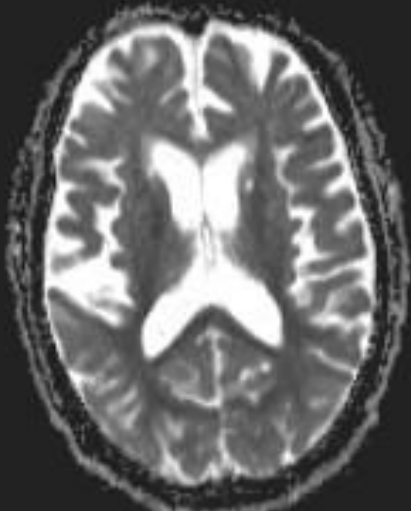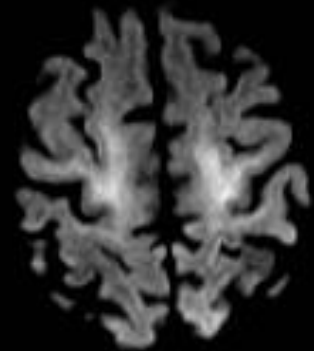
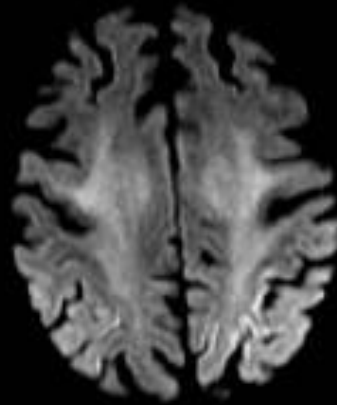
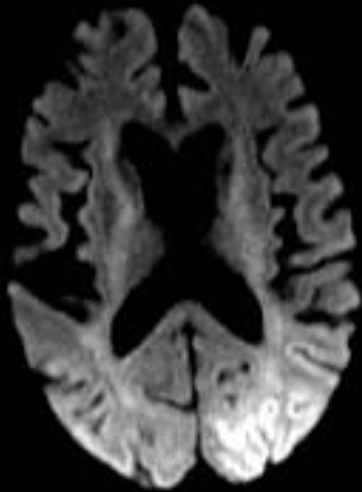




A05

Answer:
Sellar spine

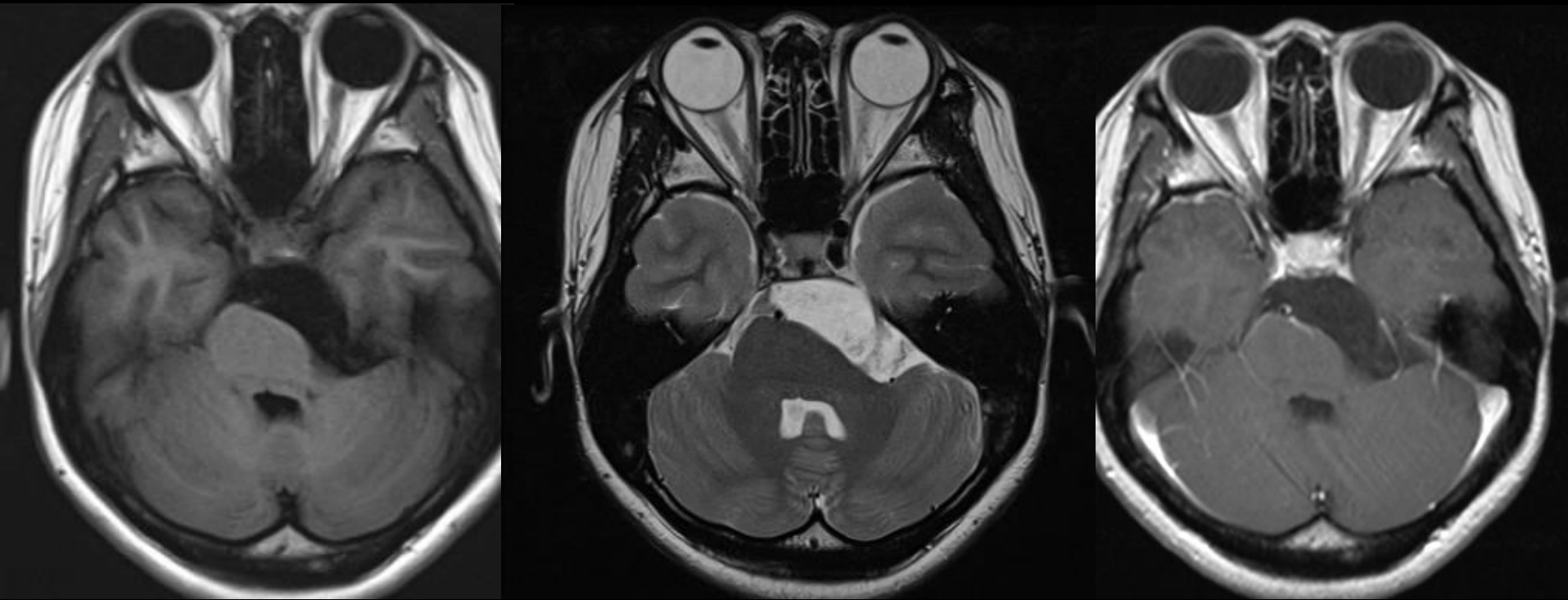
Q06 87 y/o Female, conscious change, past history of metabolic disorder, What is your Diagnosis?

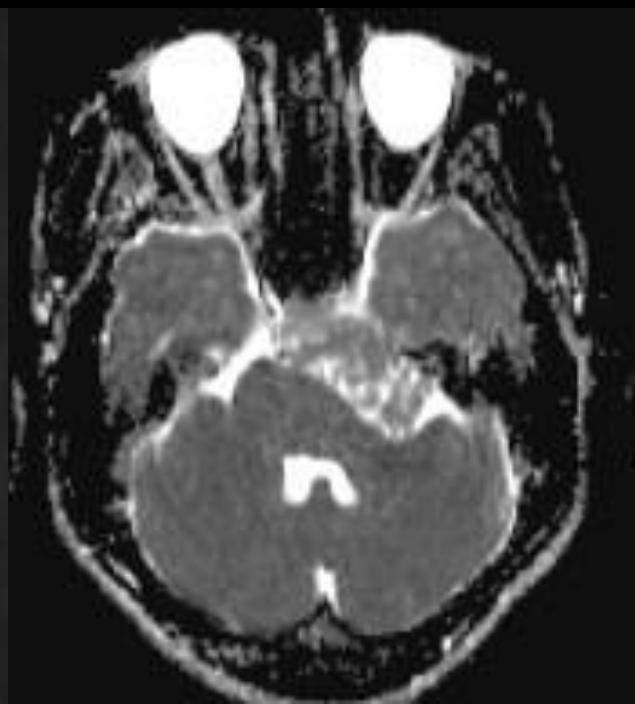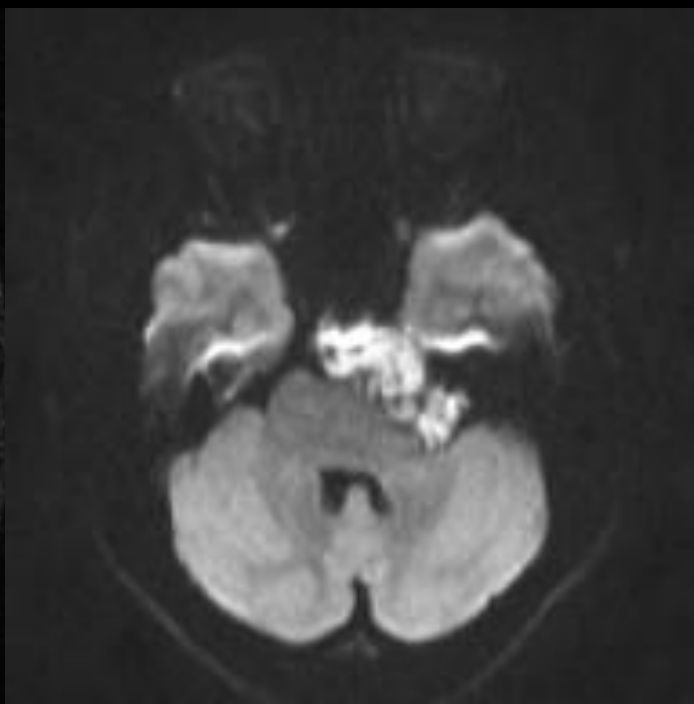
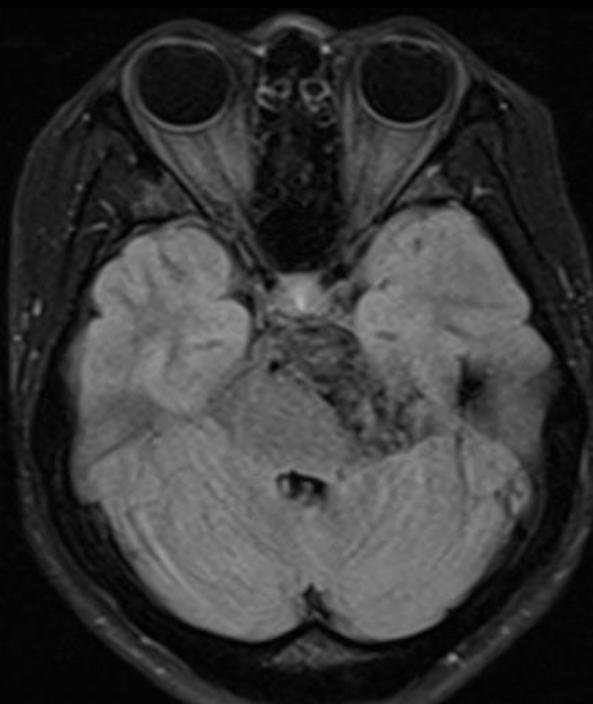


Answer:

Hypoglycemic encephalopathy

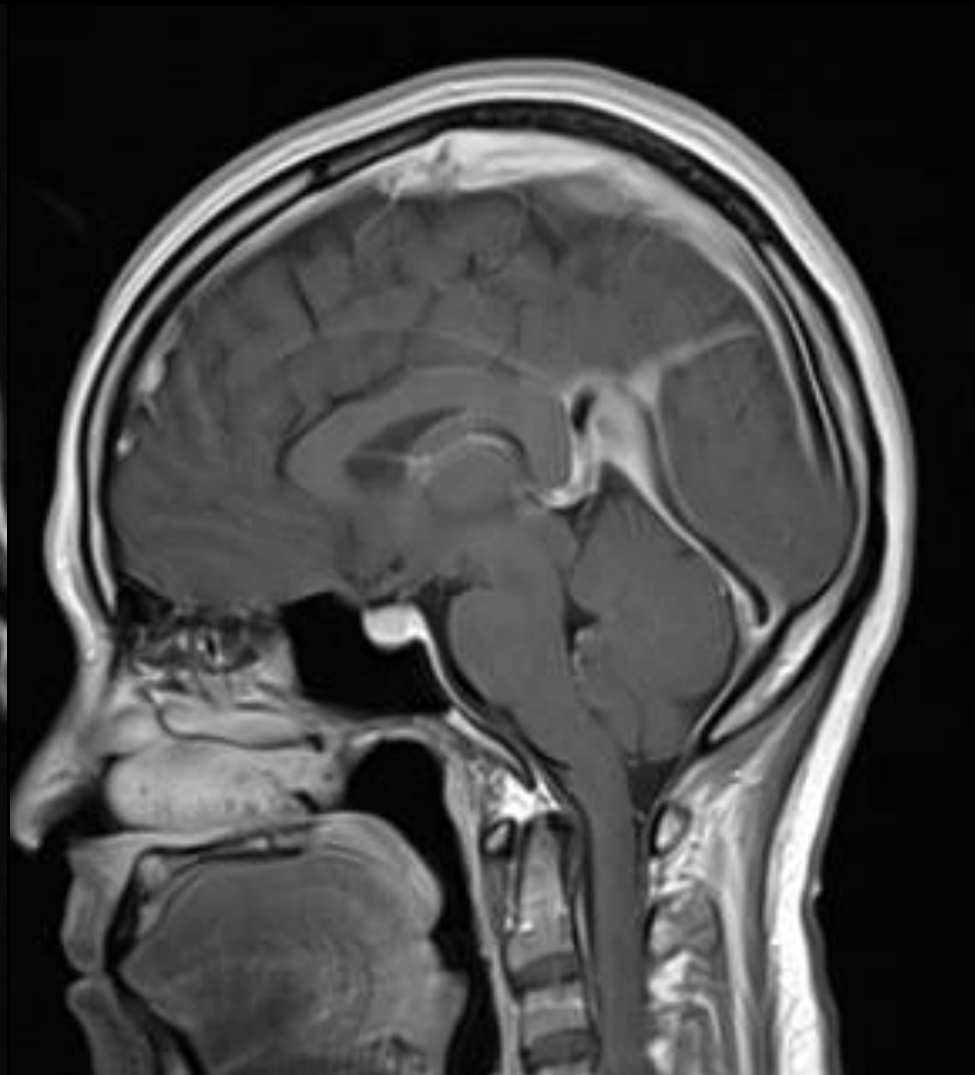
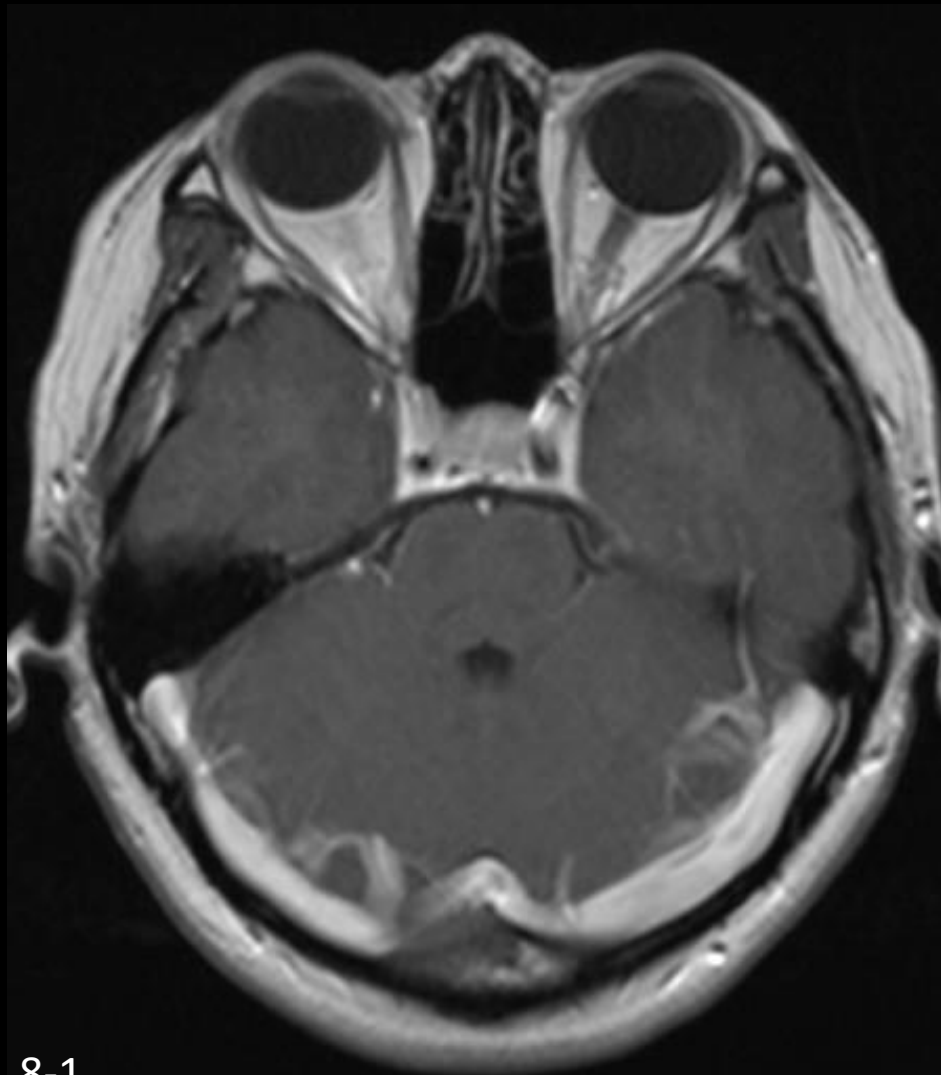
Q07 27 y/o Female, left trigeminal neuralgia, What is your Diagnosis?

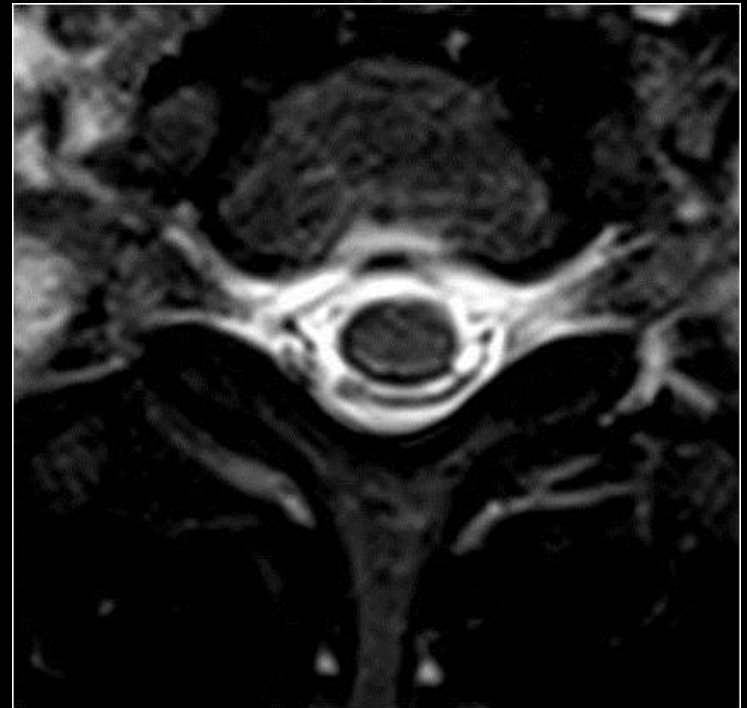
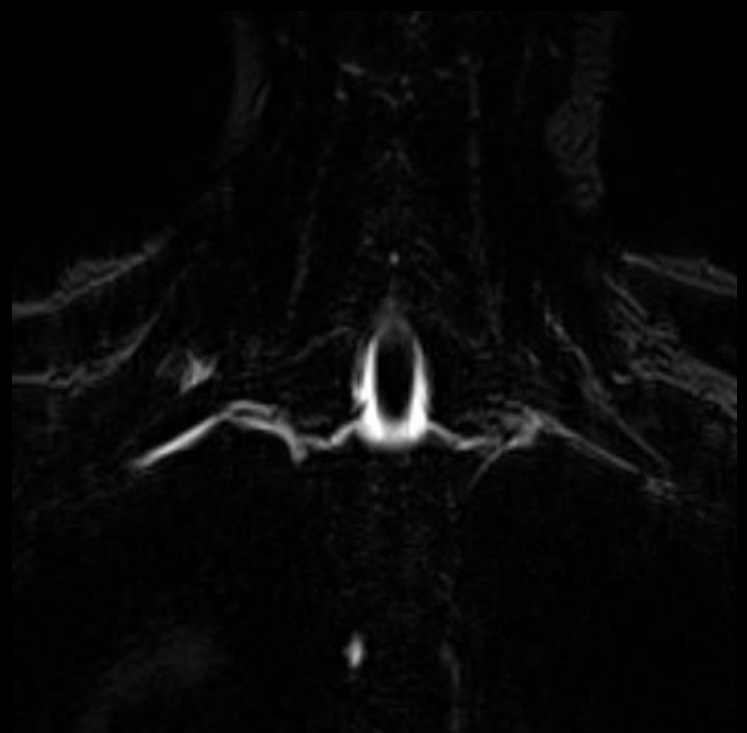
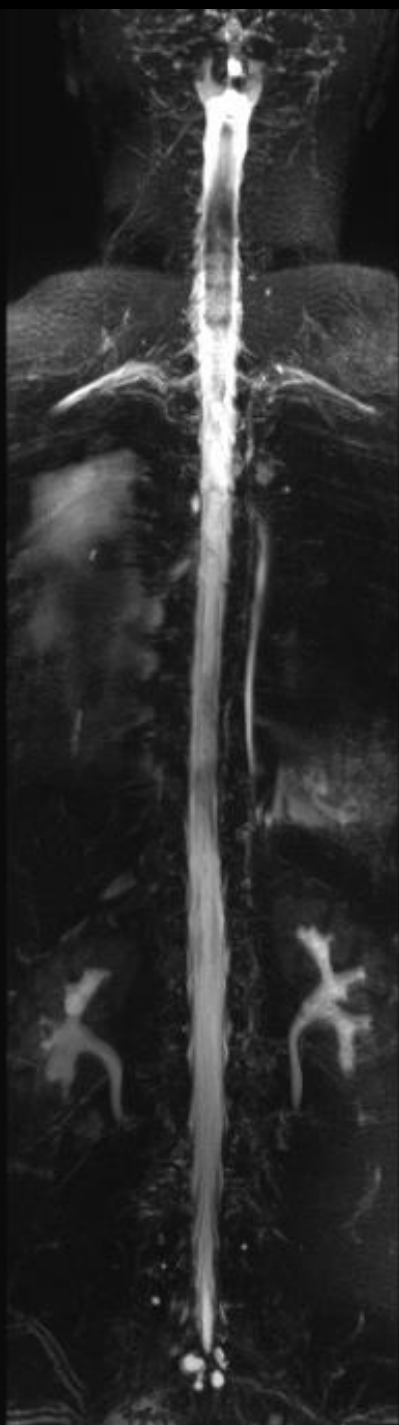


Answer:
Epidermoid cyst

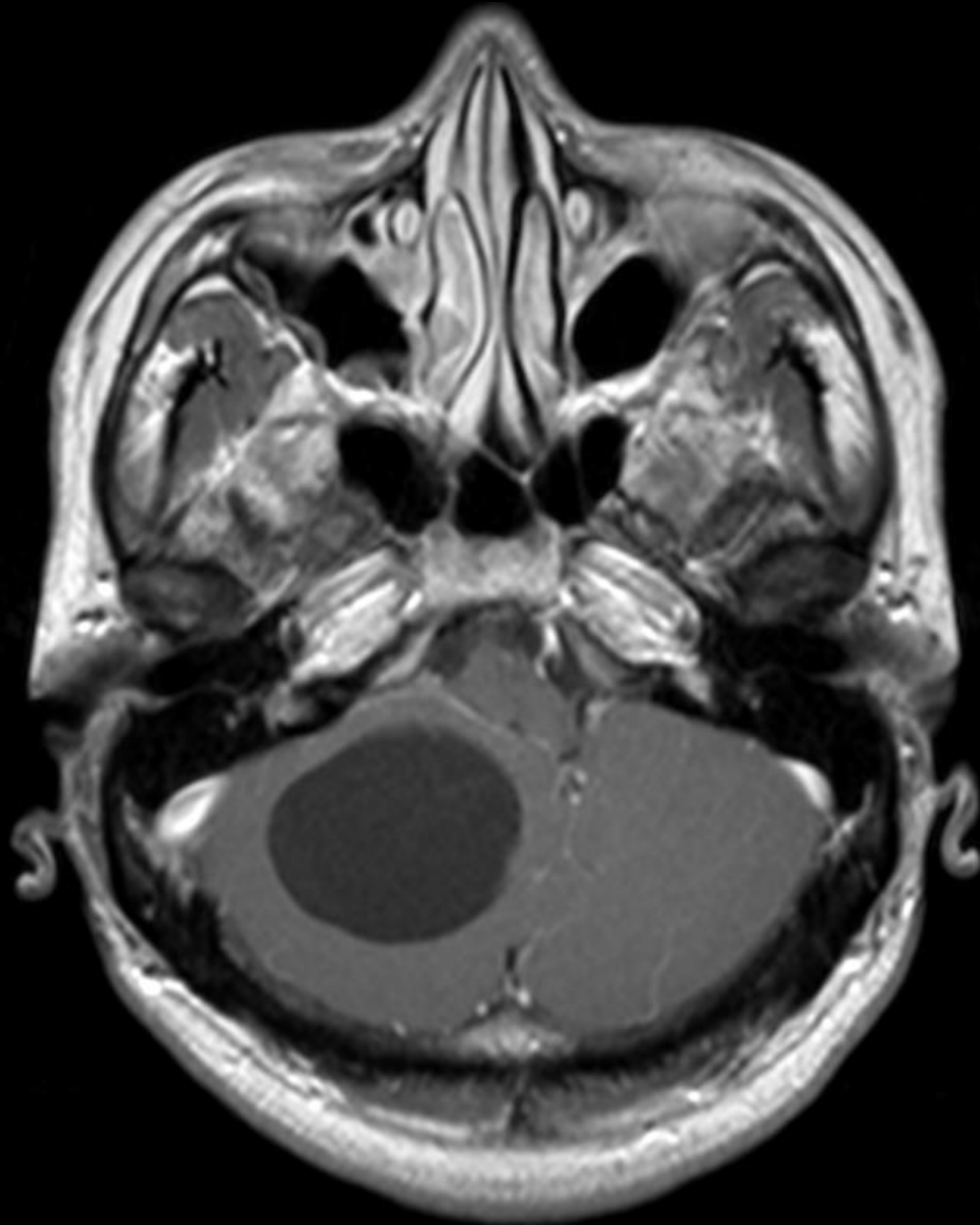
Q08 37 y/o Female, headache, What is your
Diagnosis?

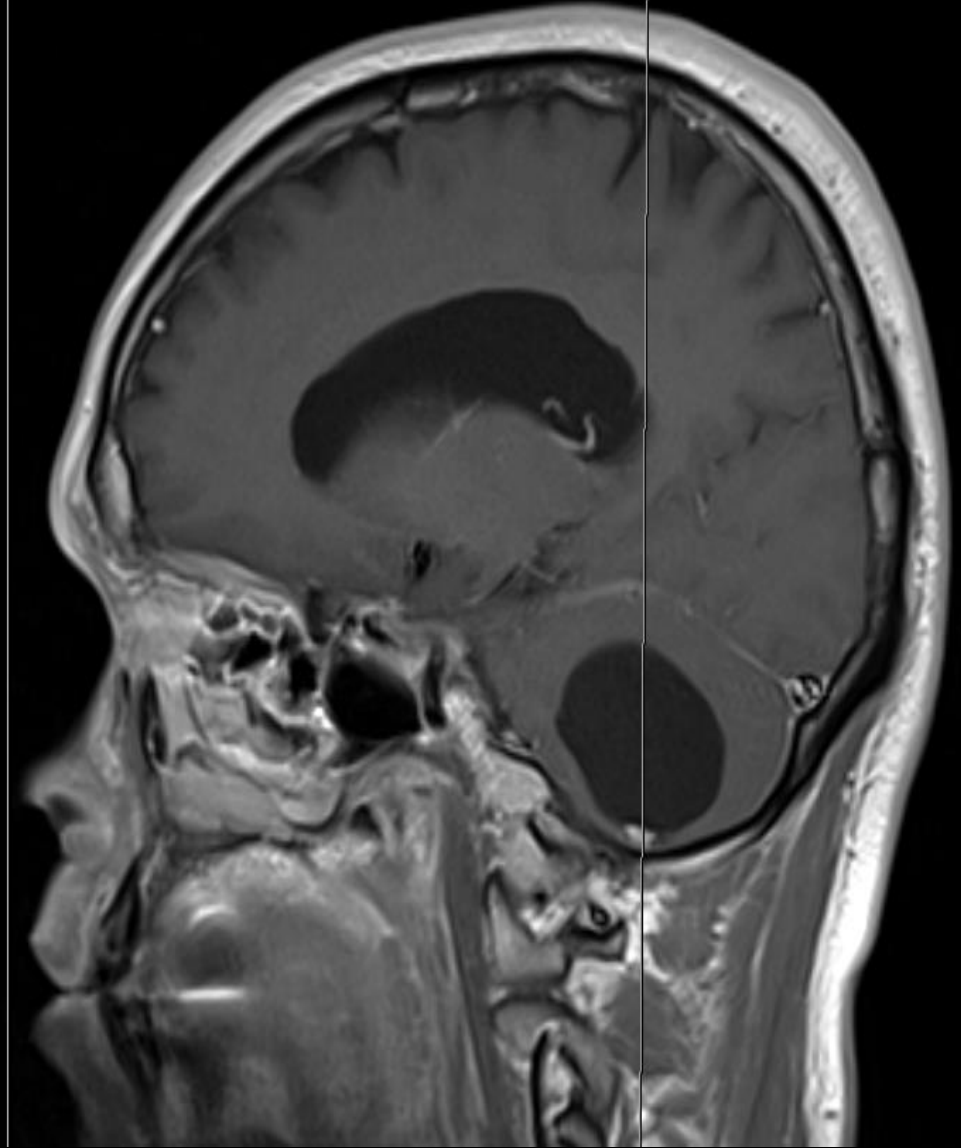
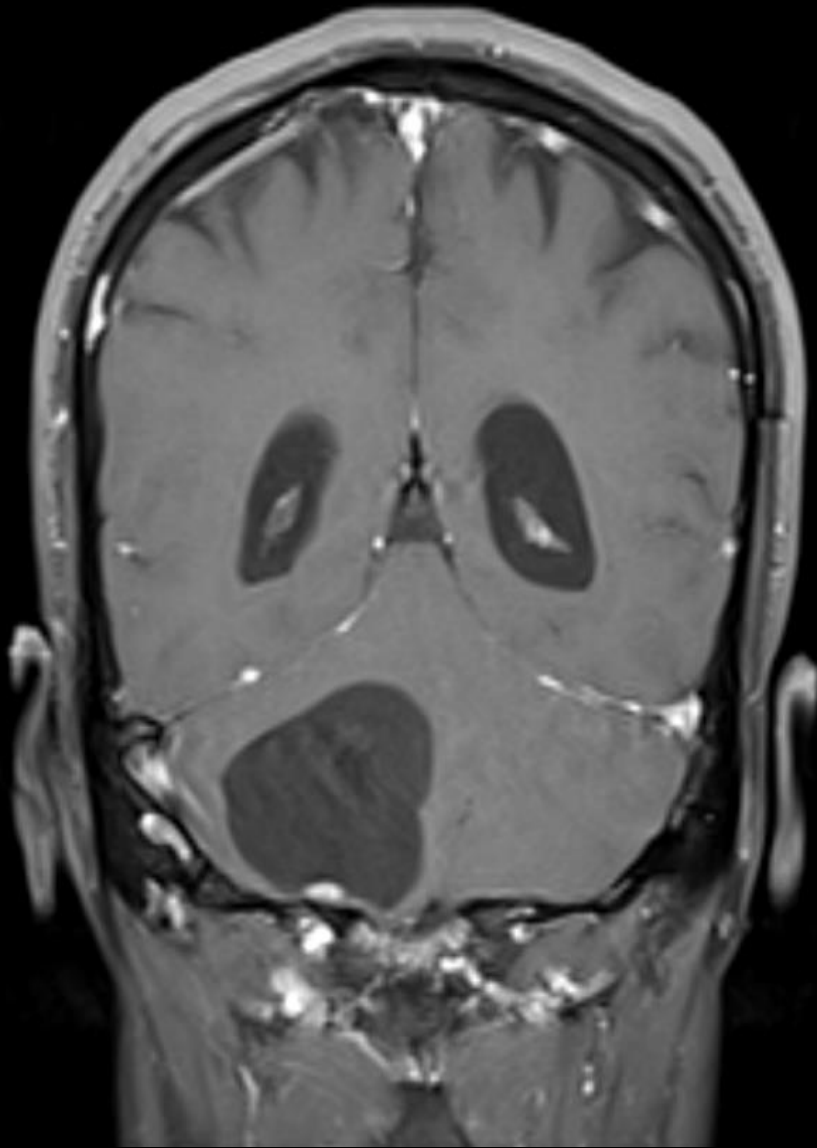




Answer:
CSF leakage

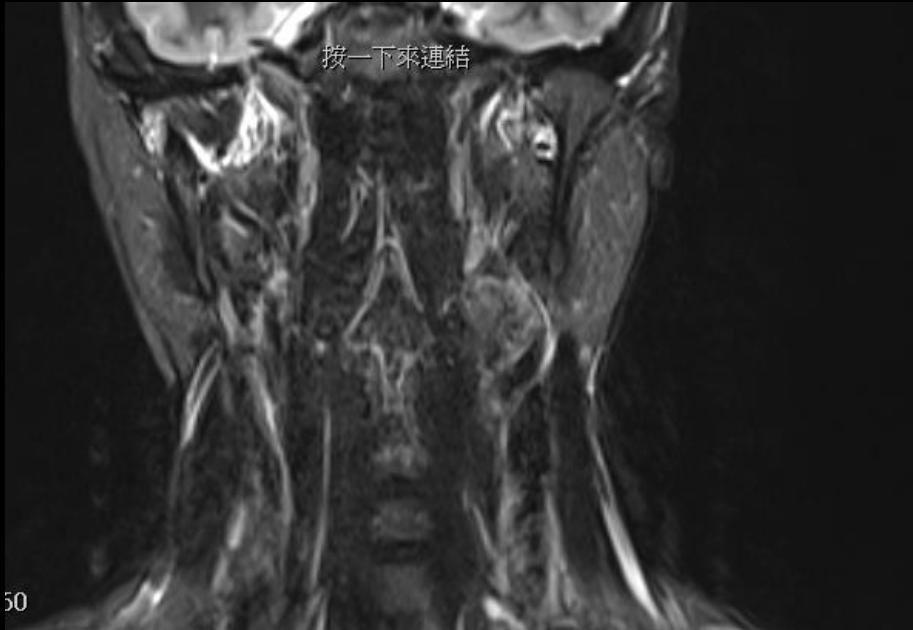
Q09 Dizziness and giddiness, What is your Diagnosis?



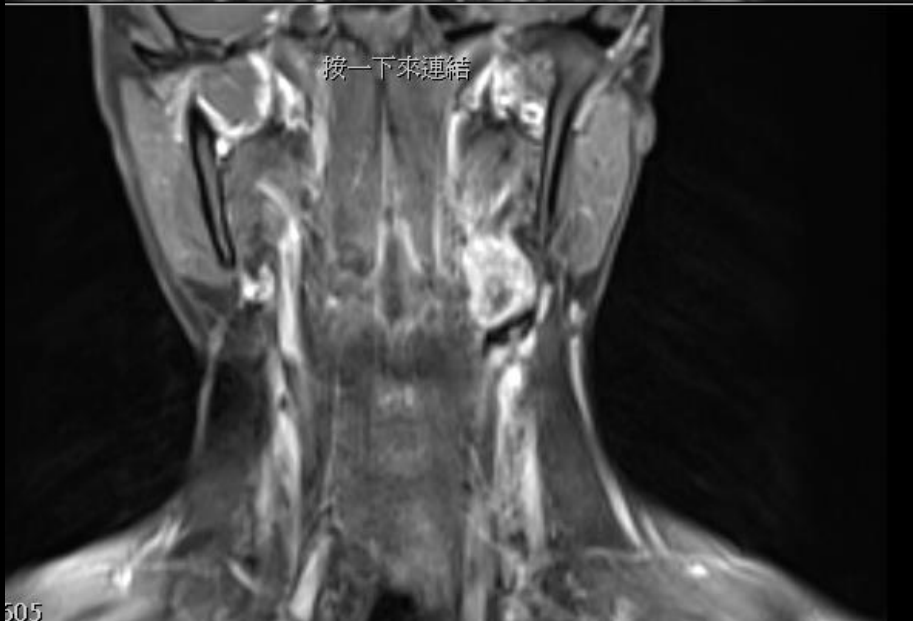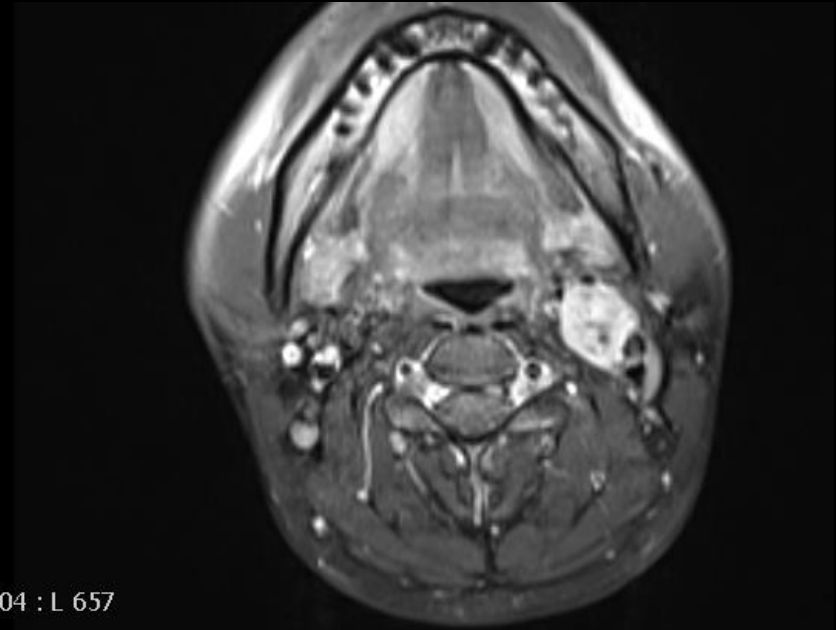


Answer:
Hemangioblastoma

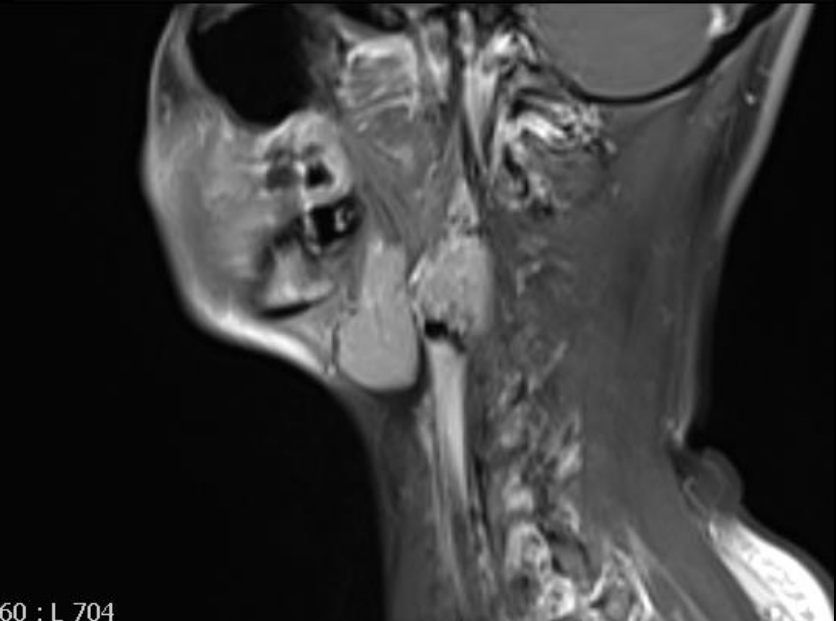
Q10 Neck bulging mass, What is your Diagnosis?



15



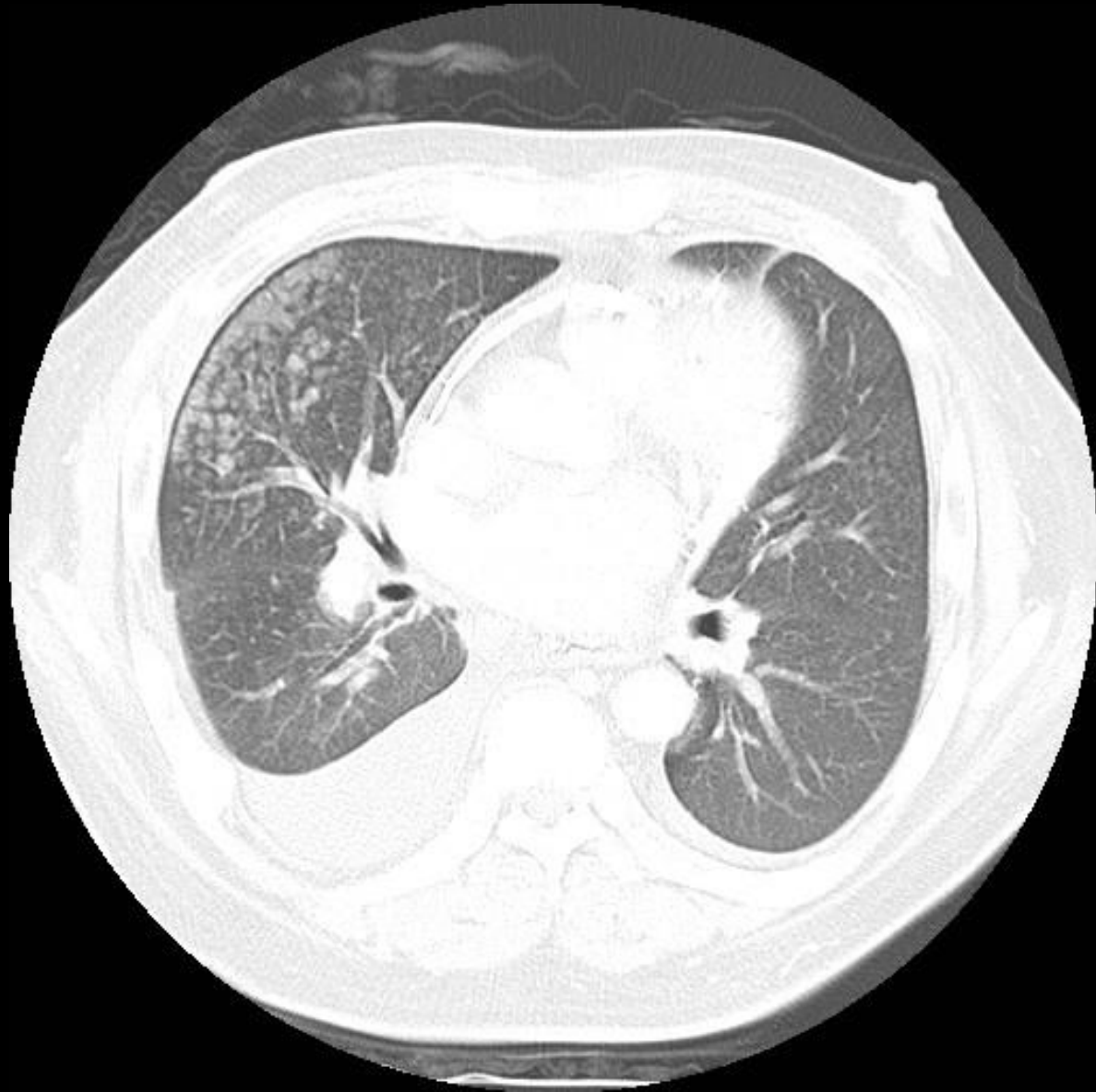
16



A10

Answer:
Carotid body tumor

Q11 56 y/o male, chronic renal failure, What is your Diagnosis?

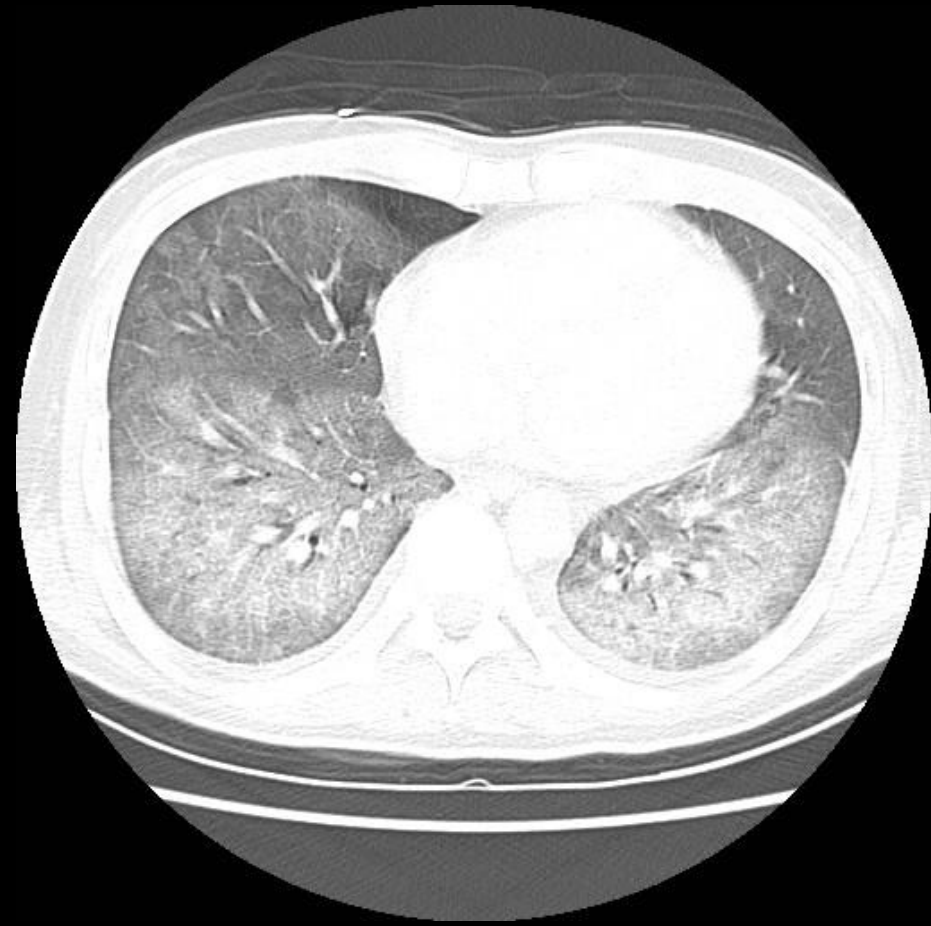
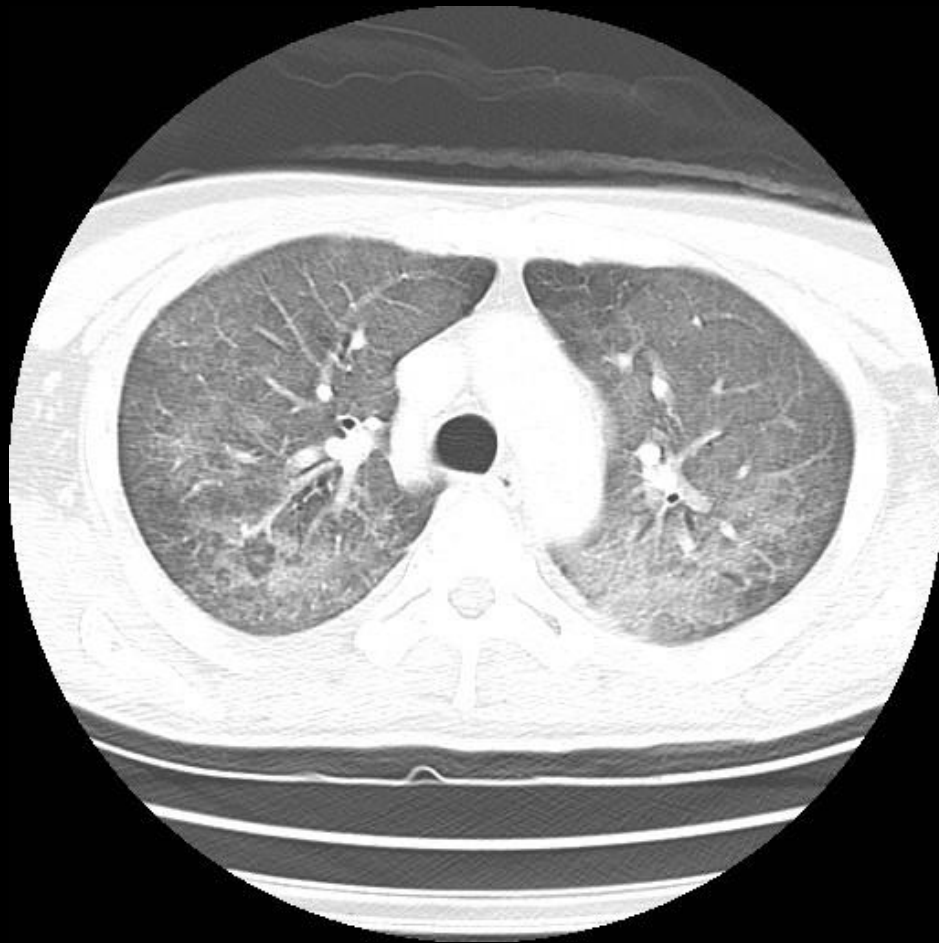


A11

Answer:

pulmonary alveolar microlithiasis

Q12 37 y/o male, r/o pneumonia, What is your Diagnosis?



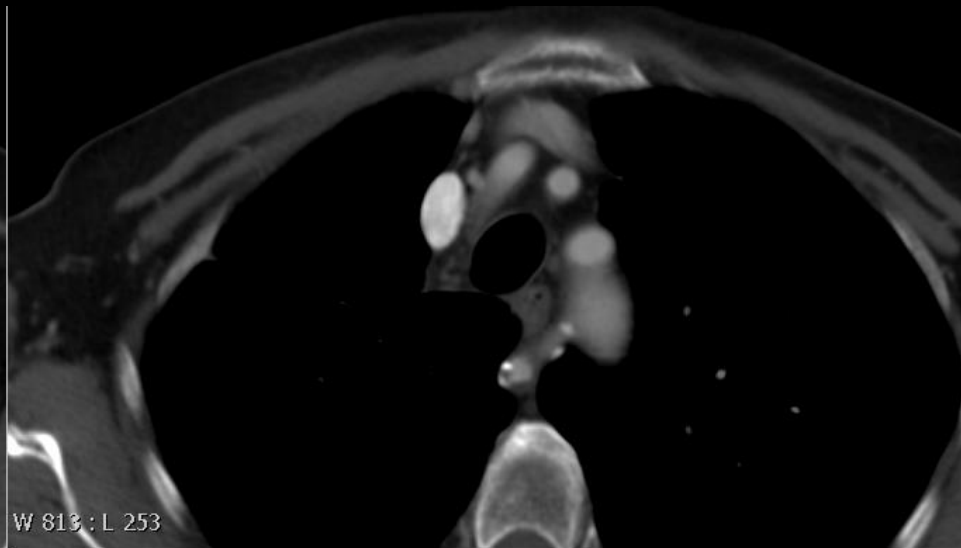
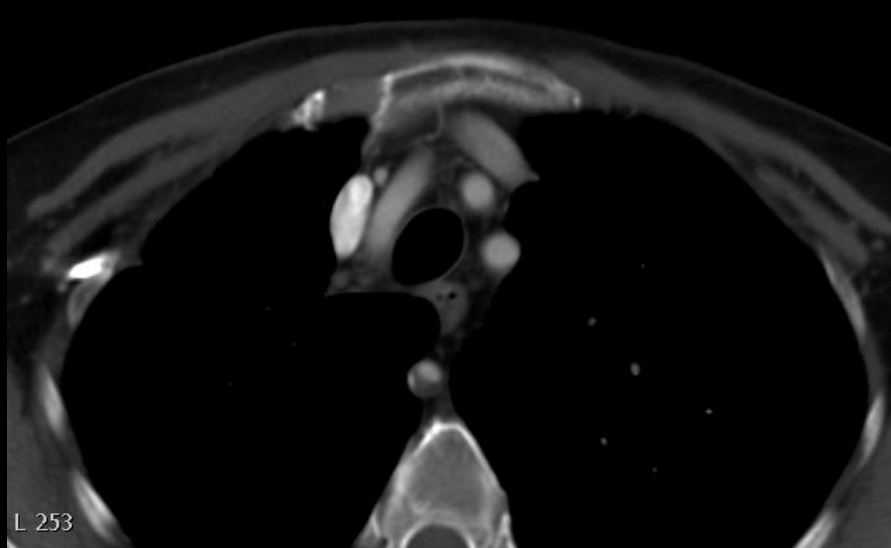
Answer:

Pneumocystis jirovecii (PJP)

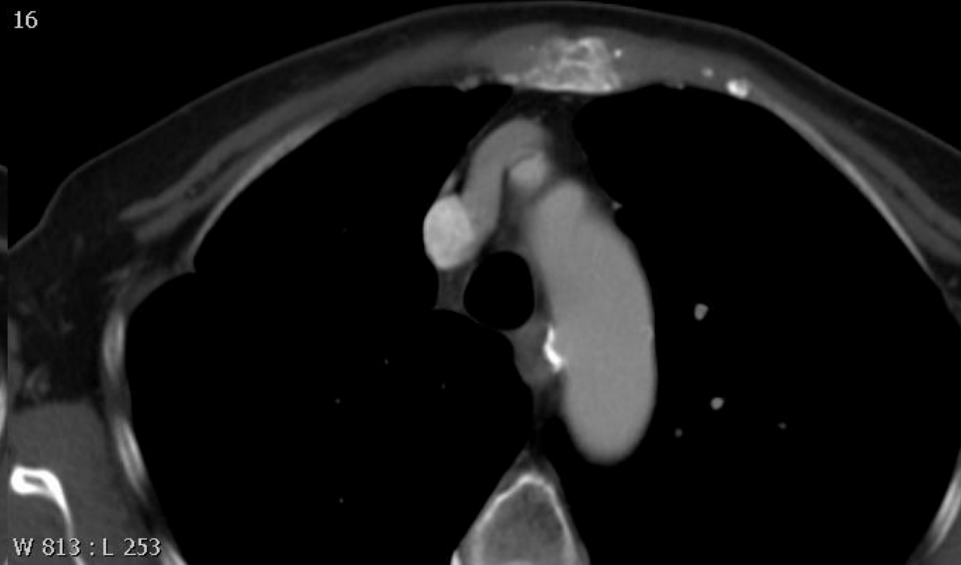
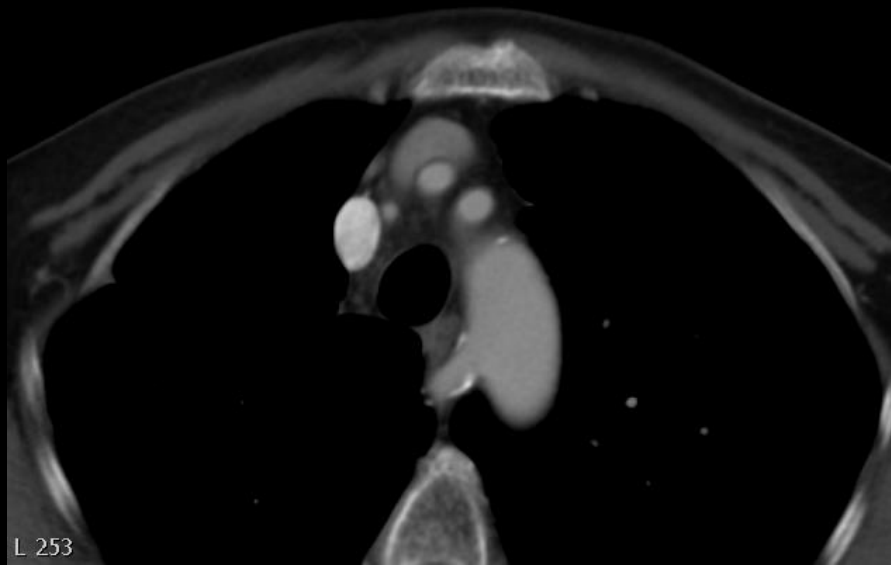
or

Pneumocystis carinii pneumonia (PCP)

Q13 Hx: non, What is your Diagnosis?



16

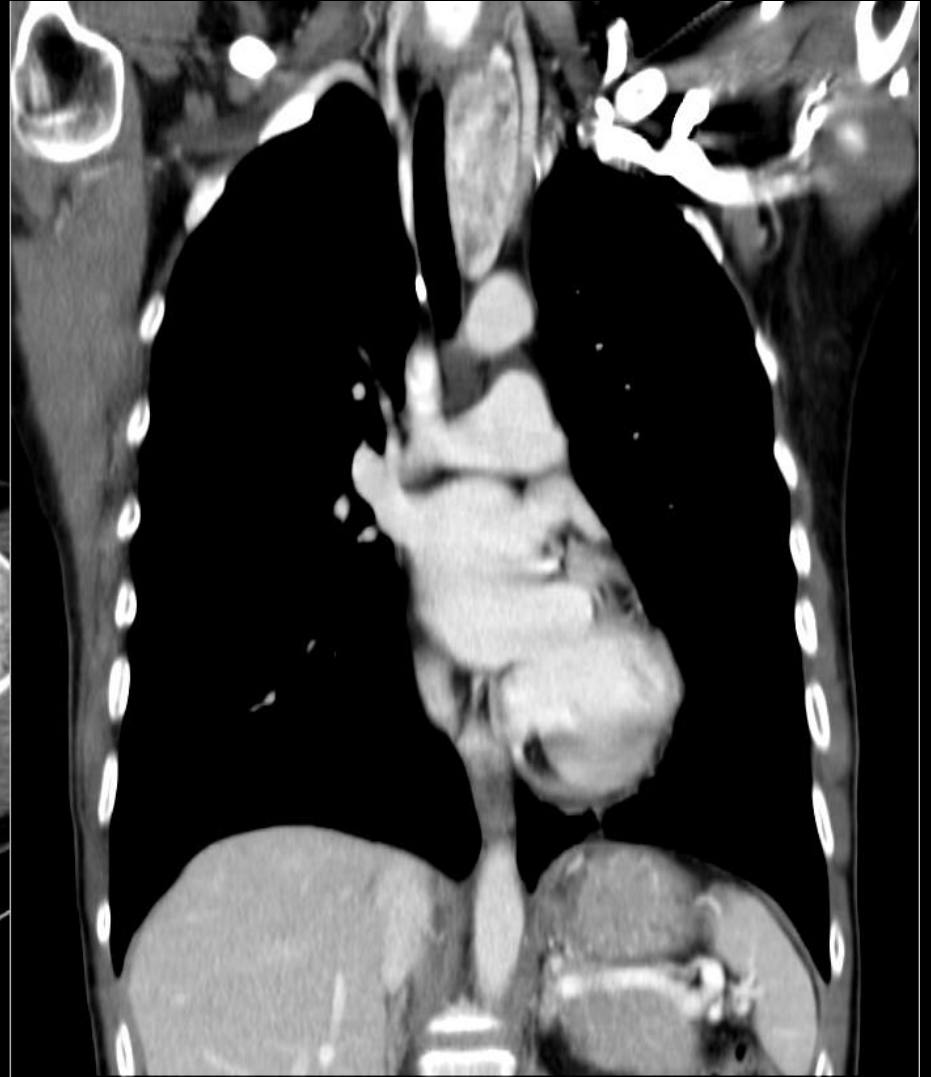
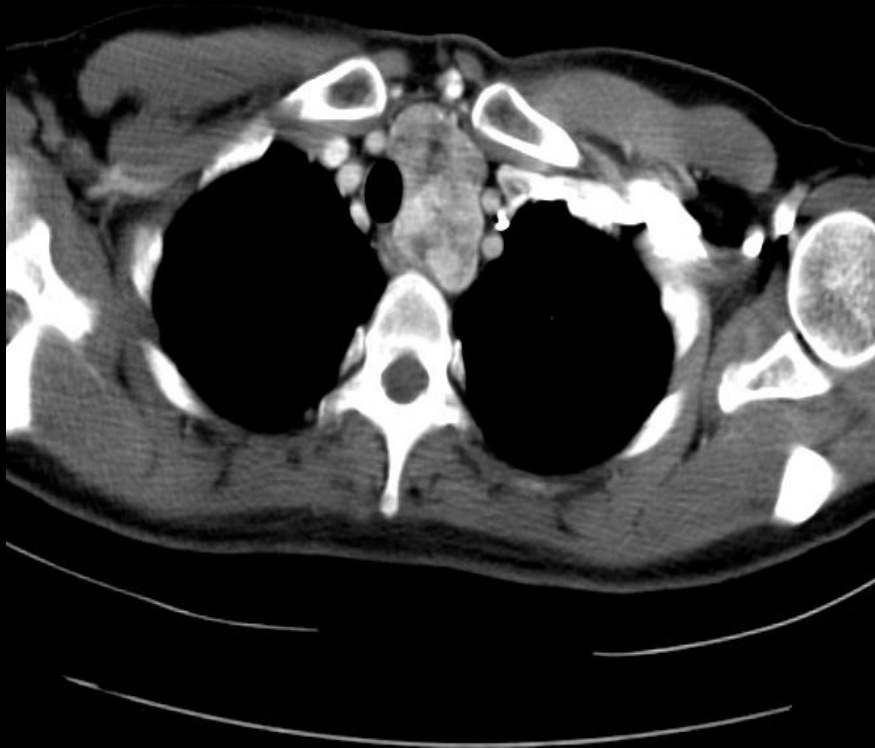

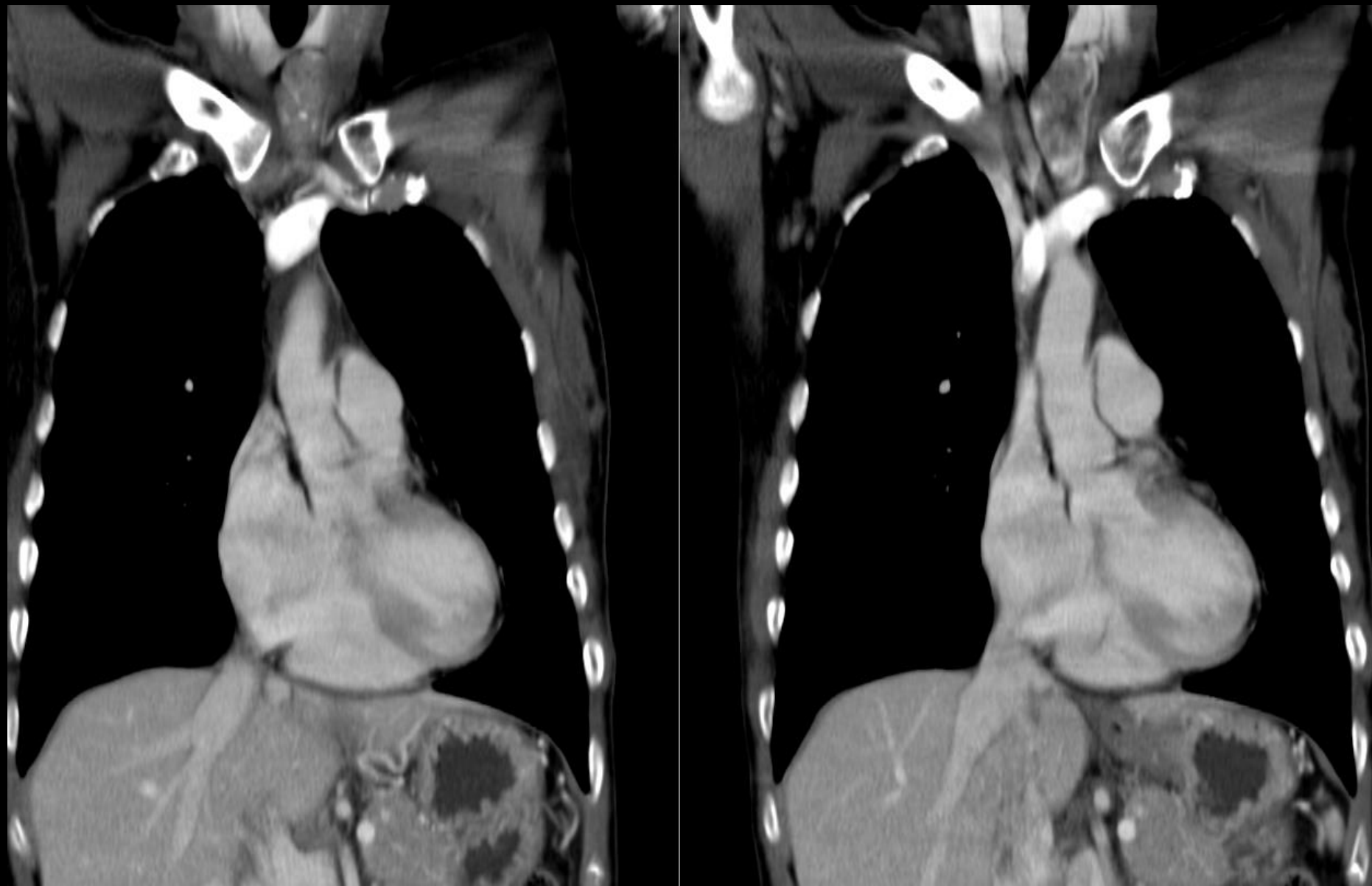
Answer:

Aberrant right subclavian artery

Q14

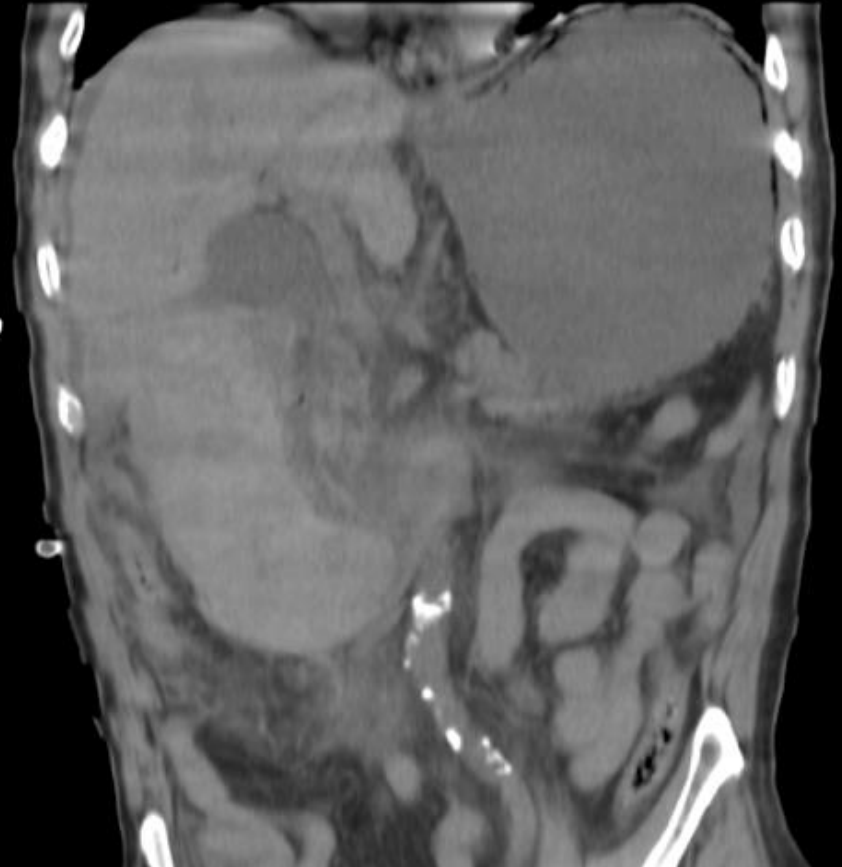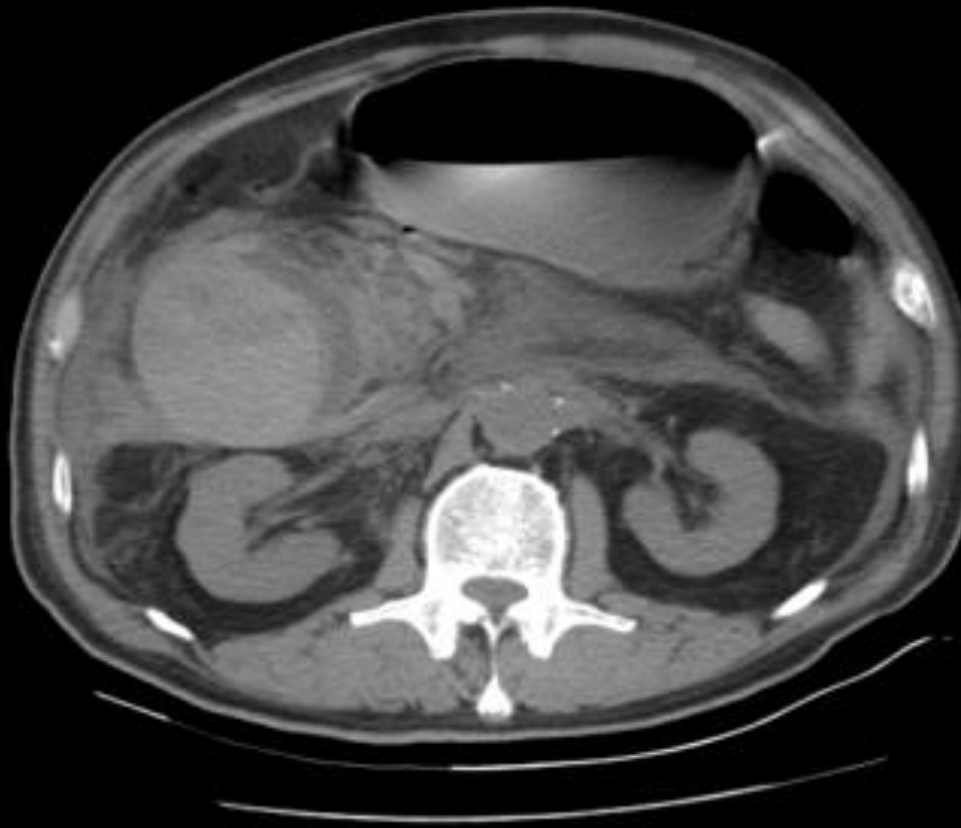Mass in upper chest found in health examination, What is your Diagnosis?





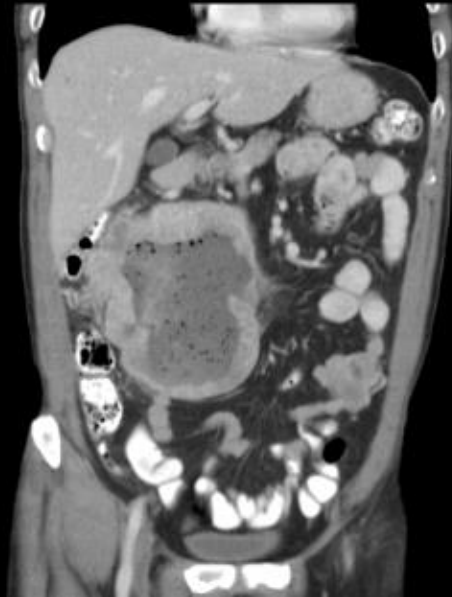
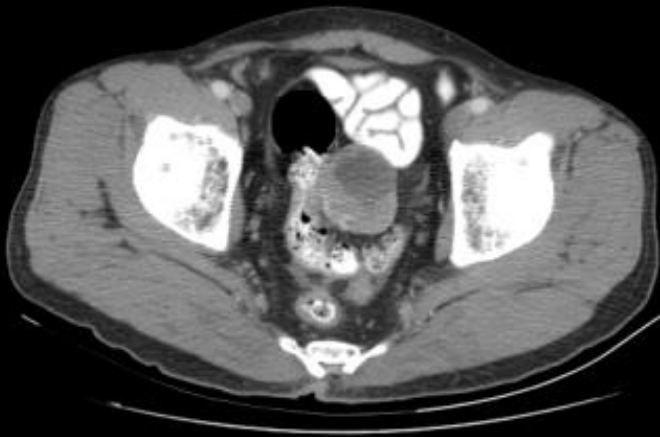
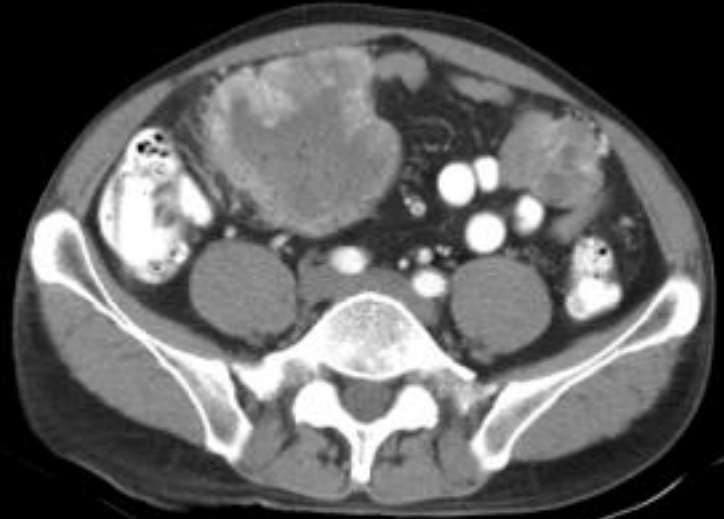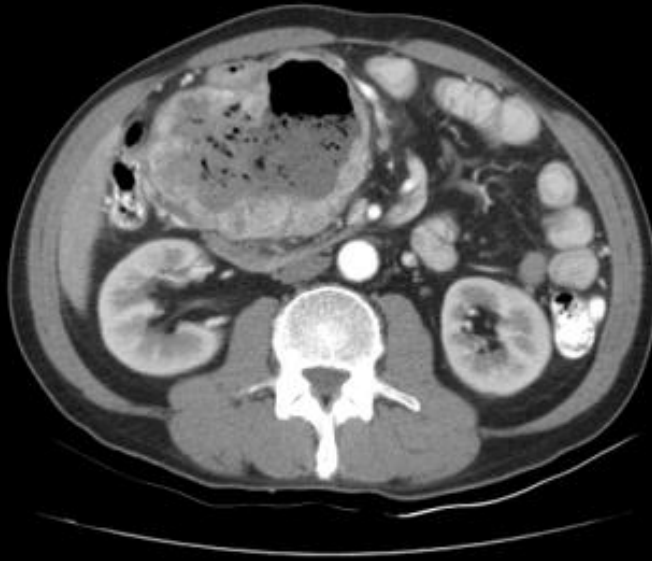Answer:
Intrathoracic goiter

Q15 55 y/o male, Sudden onset abdominal pain,
What is your Diagnosis?



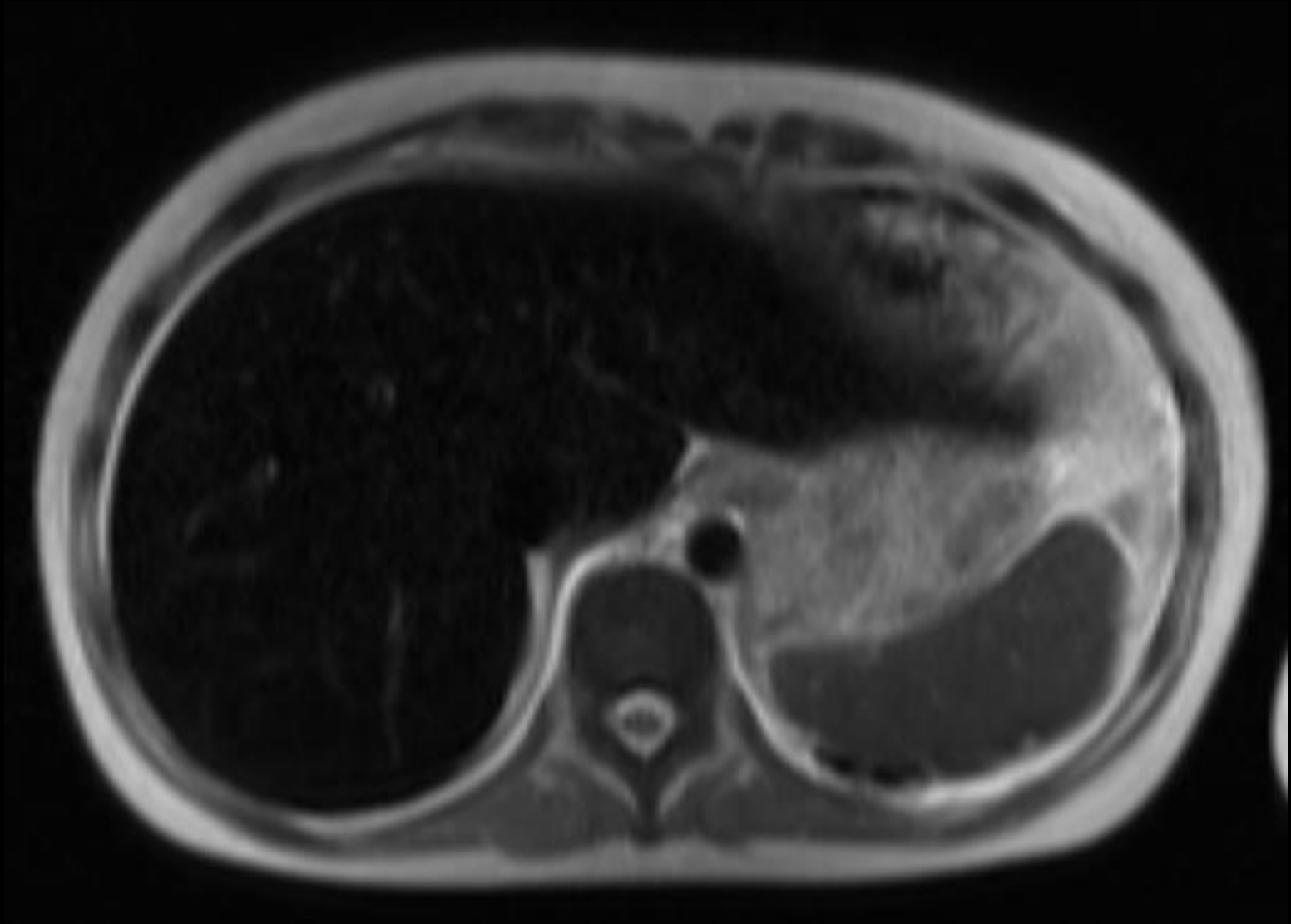
- Ans:
Active Duodenal Bleeding

Q16 48 y/o male, Vague abdominal pain, What is your Diagnosis?



- Ans:
Multiple Small Bowel GIST

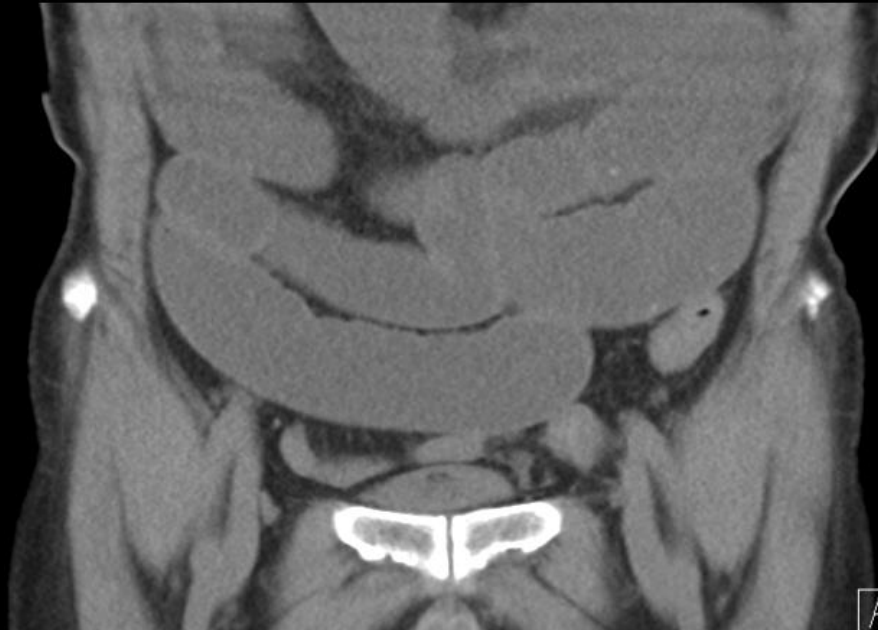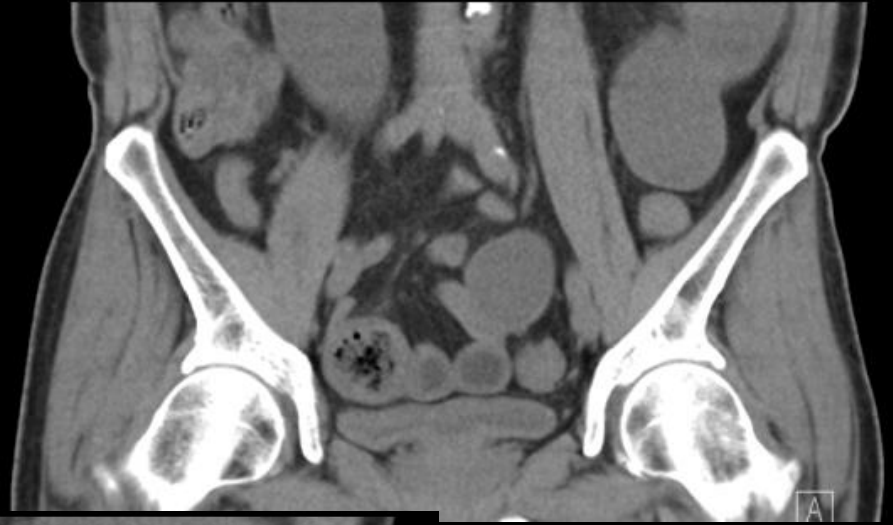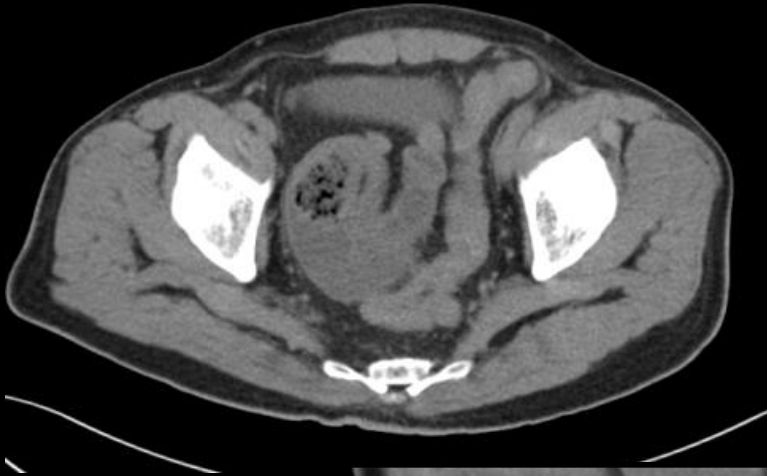Q17 30 y/o Female with history of Thalassemia,
What is your Diagnosis?



Ans:

Hepatic Hemosiderosis

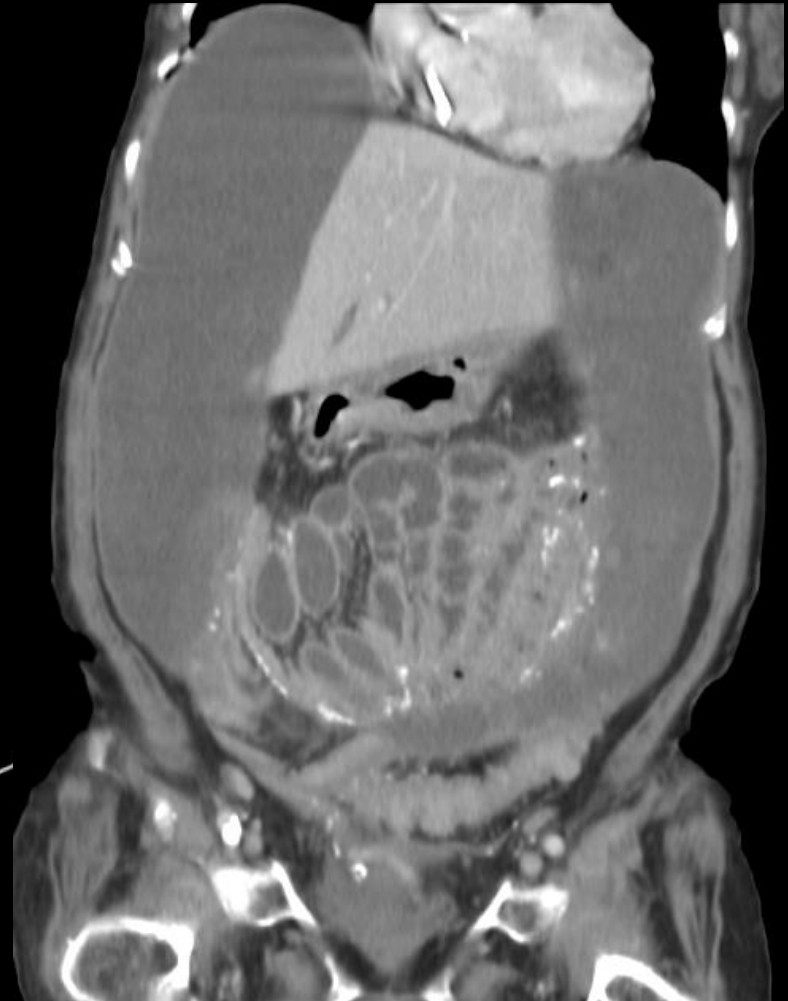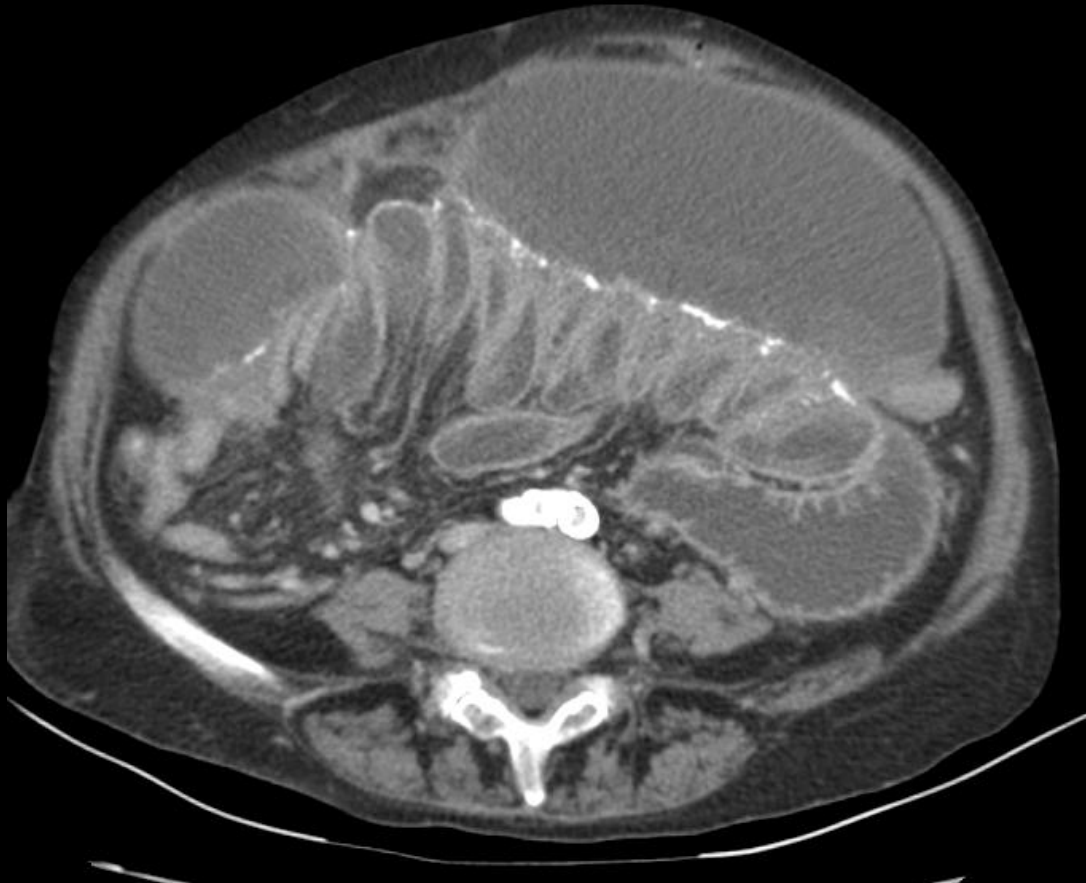Q18 80 y/o male, Abdominal pain, What is your Diagnosis?



- Ans:

Small bowel Obstruction due to Bezoar

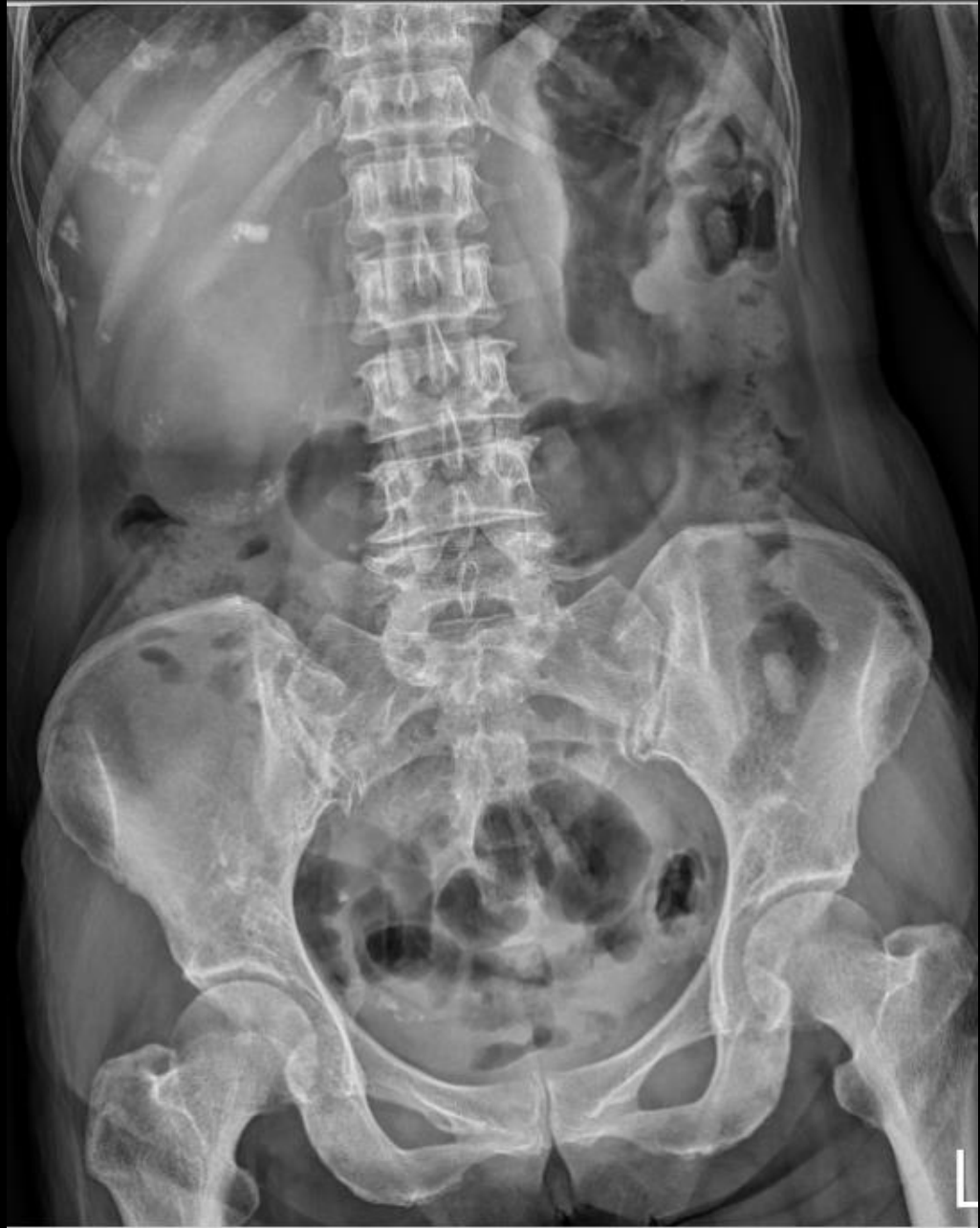Q19 77 y/o Female, Abdominal pain, What is your Diagnosis?



- Ans:

Encapsulated Peritoneal Sclerosis

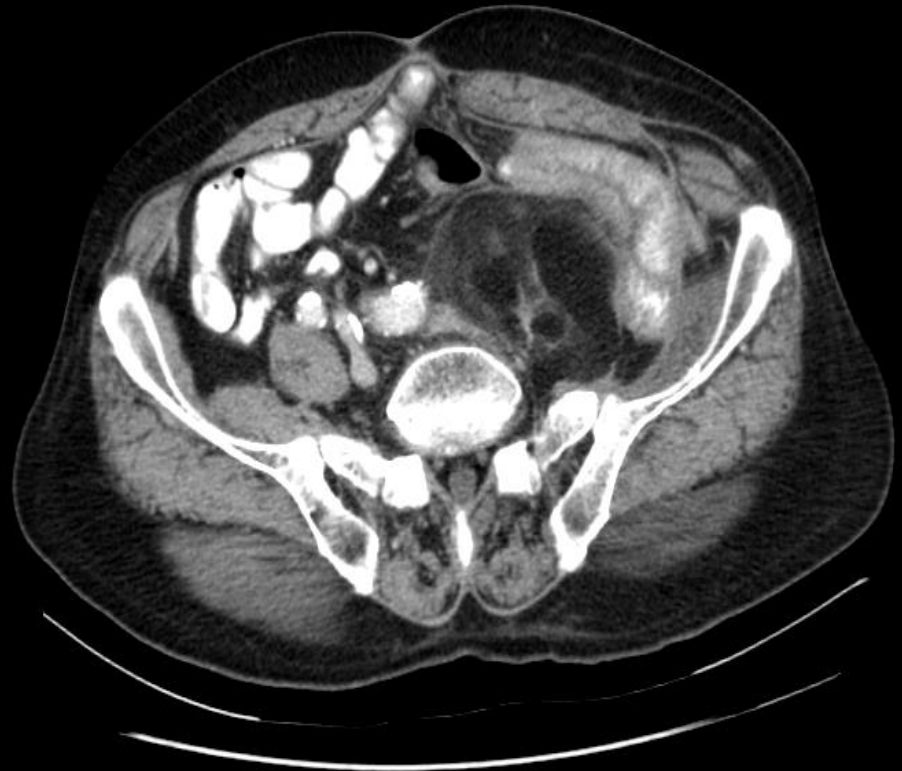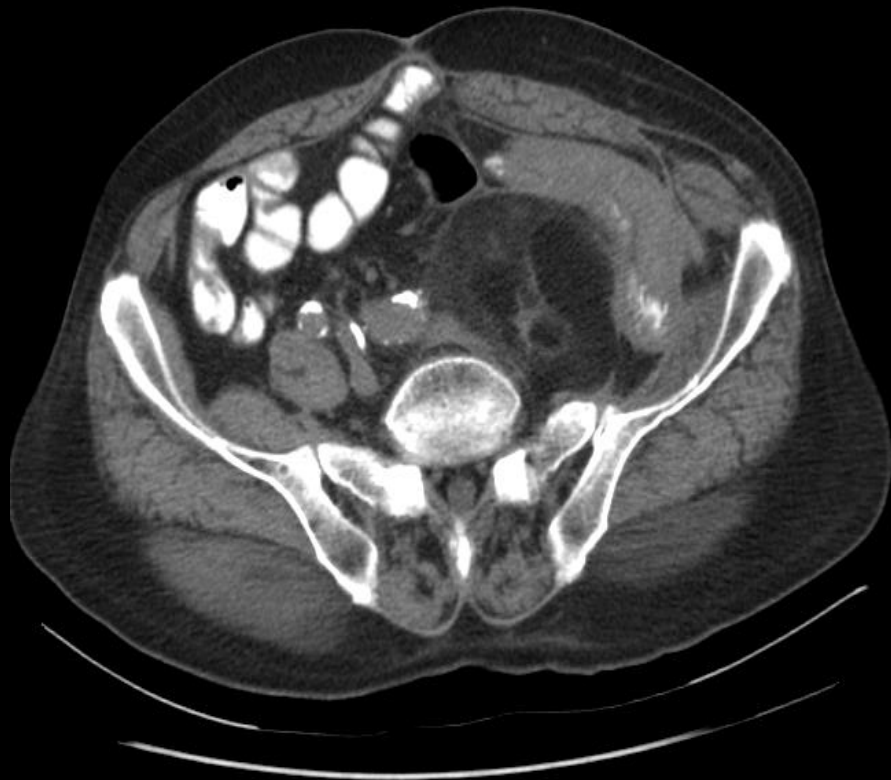Q20 70 y/o Female, abdominal pain, What is your Diagnosis?



Answer:

Porcelain Gallbladder

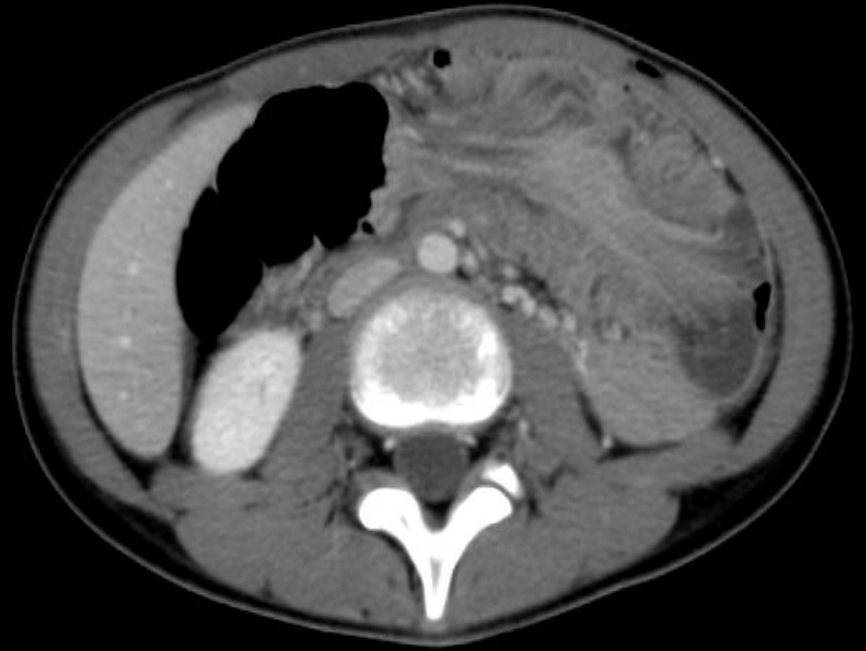
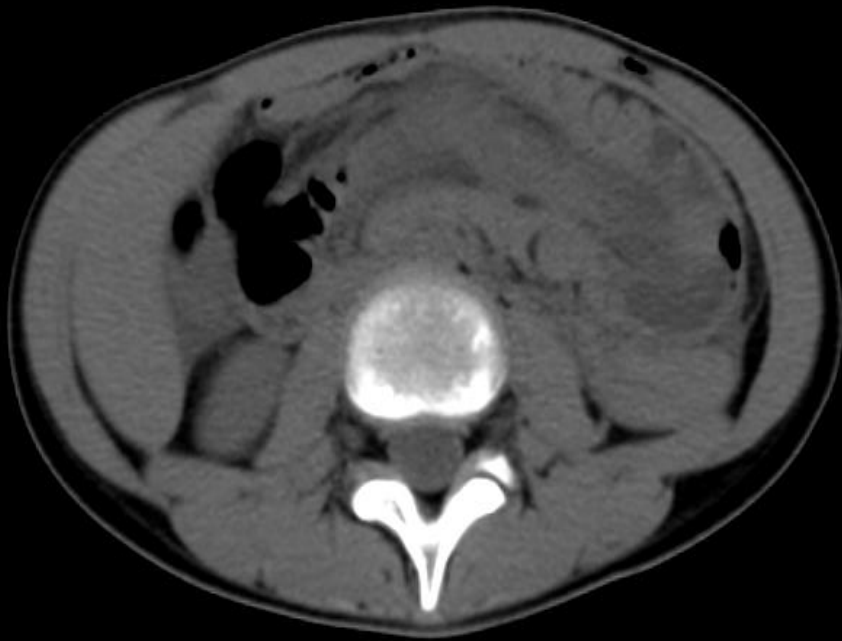Q21 Constipation, What is your Diagnosis?

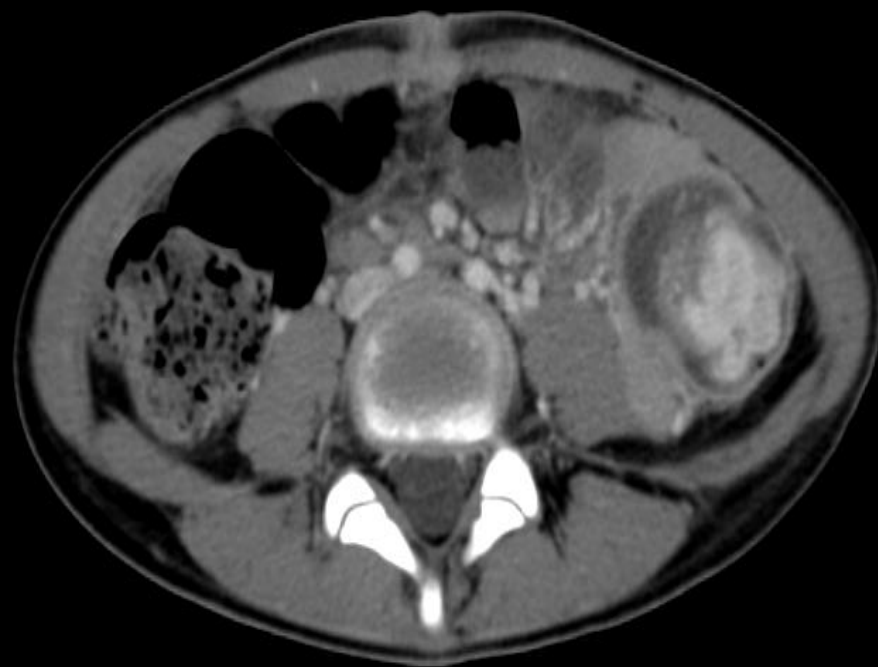
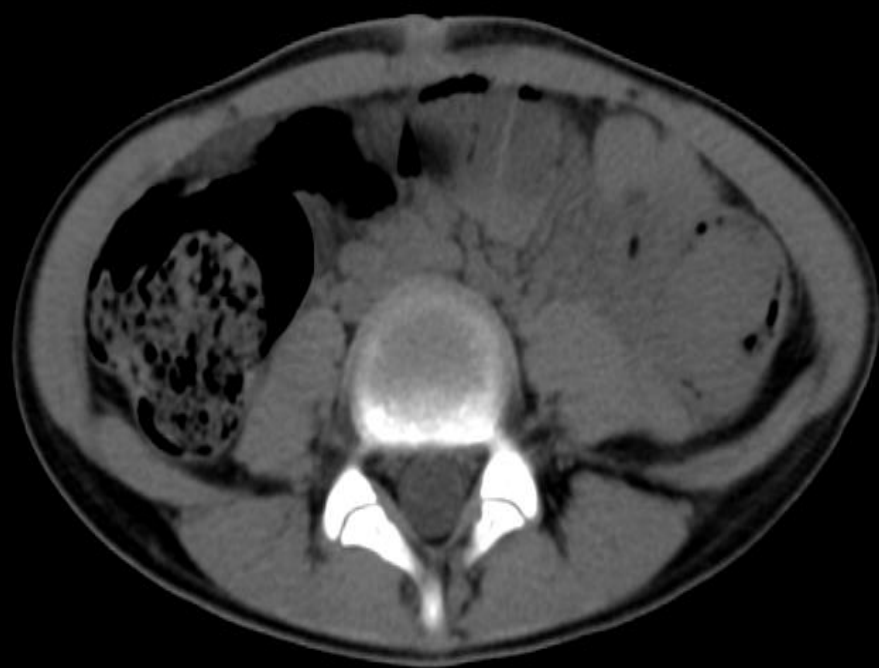
Answer:

Retroperitoneum liposarcoma

Q22 Abdominal pain, What is your Diagnosis?



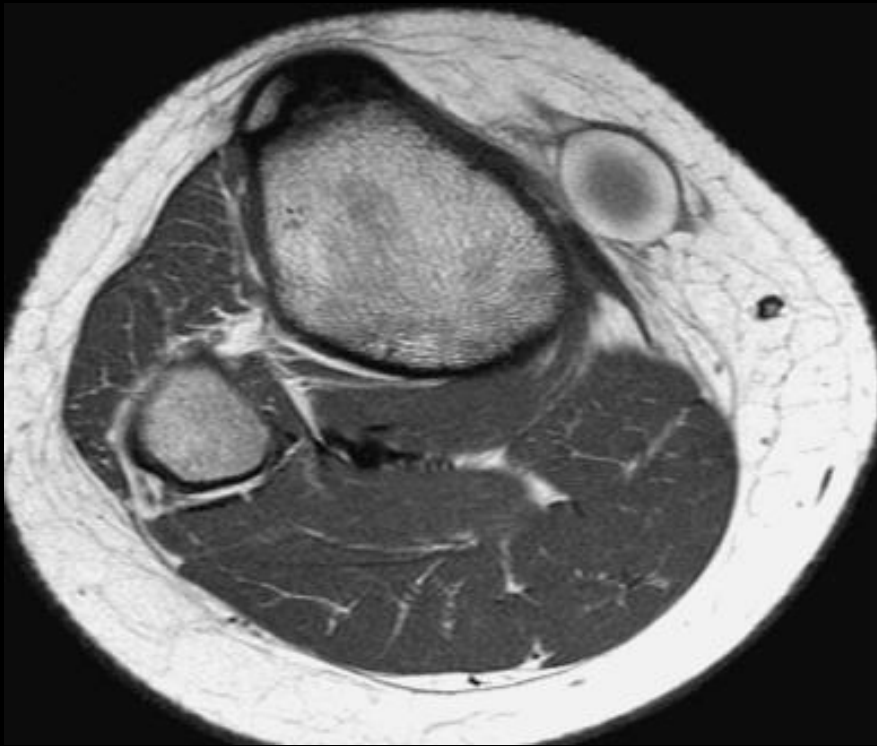

Answer:

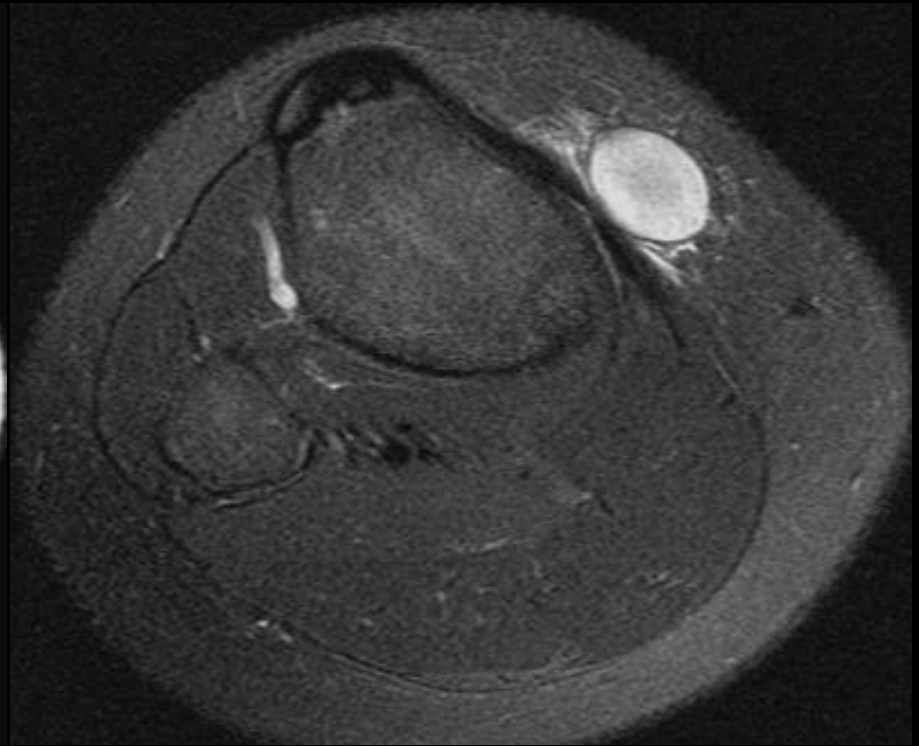
Colon-colon type intususception

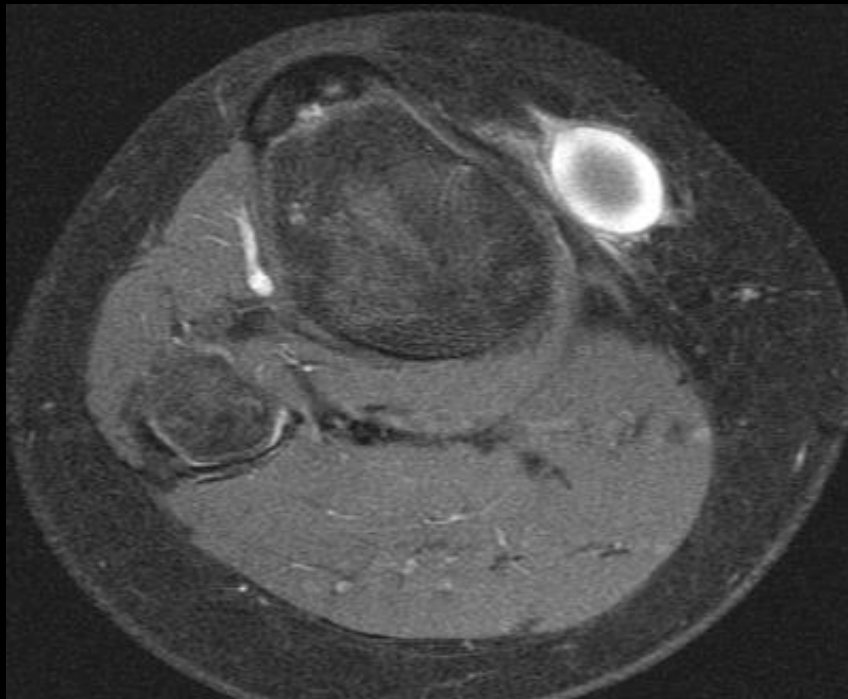
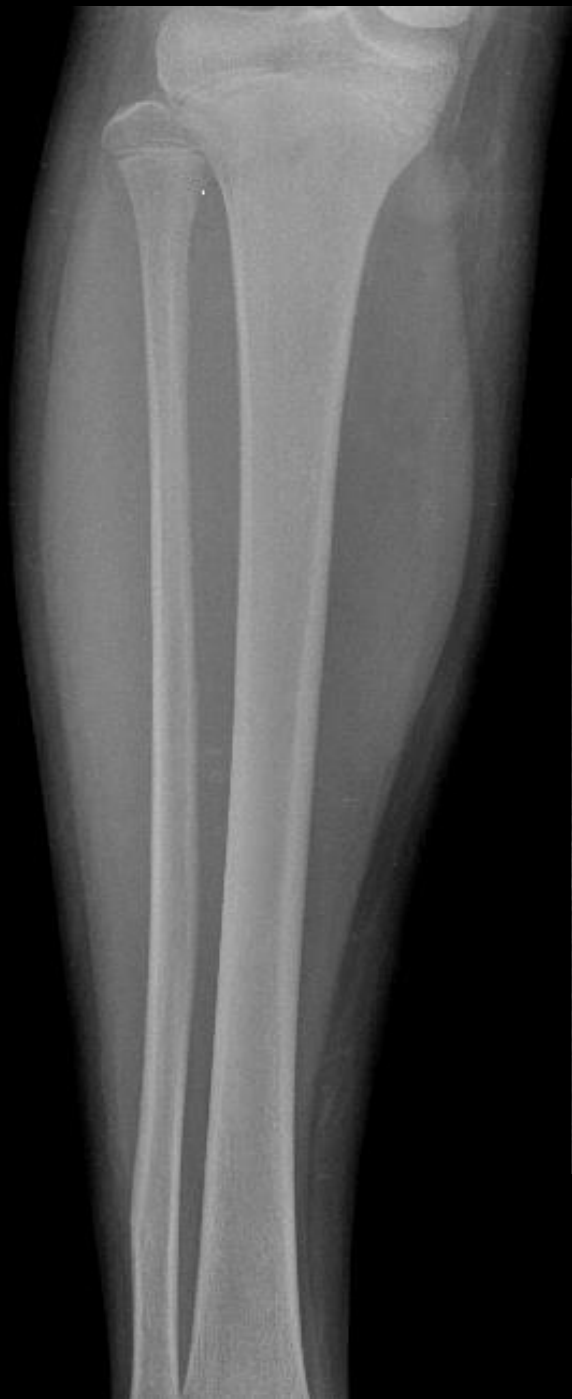Q23 13 y/o, male, a palpable mass in his right medial calf for 1 month. No trauma history. What is your Diagnosis?

T1W



T2 FS





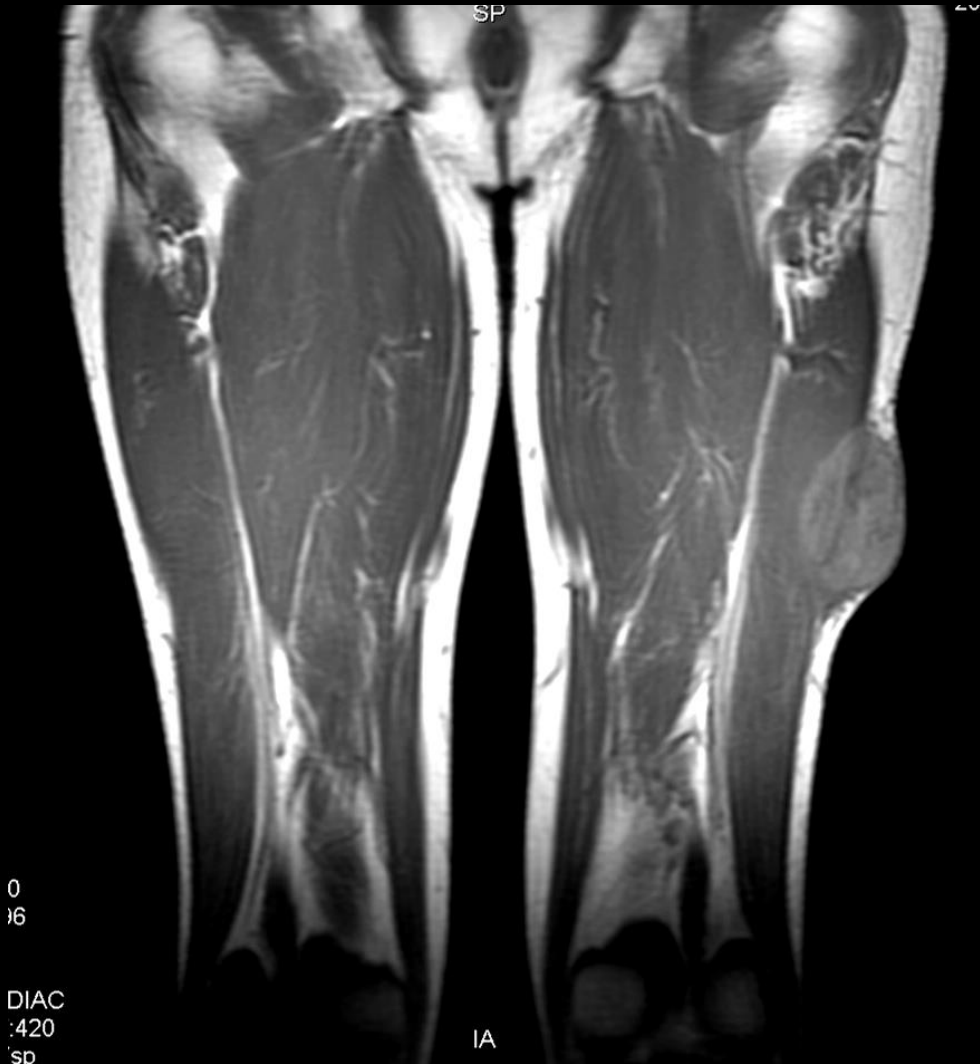C+
T1FS

A23

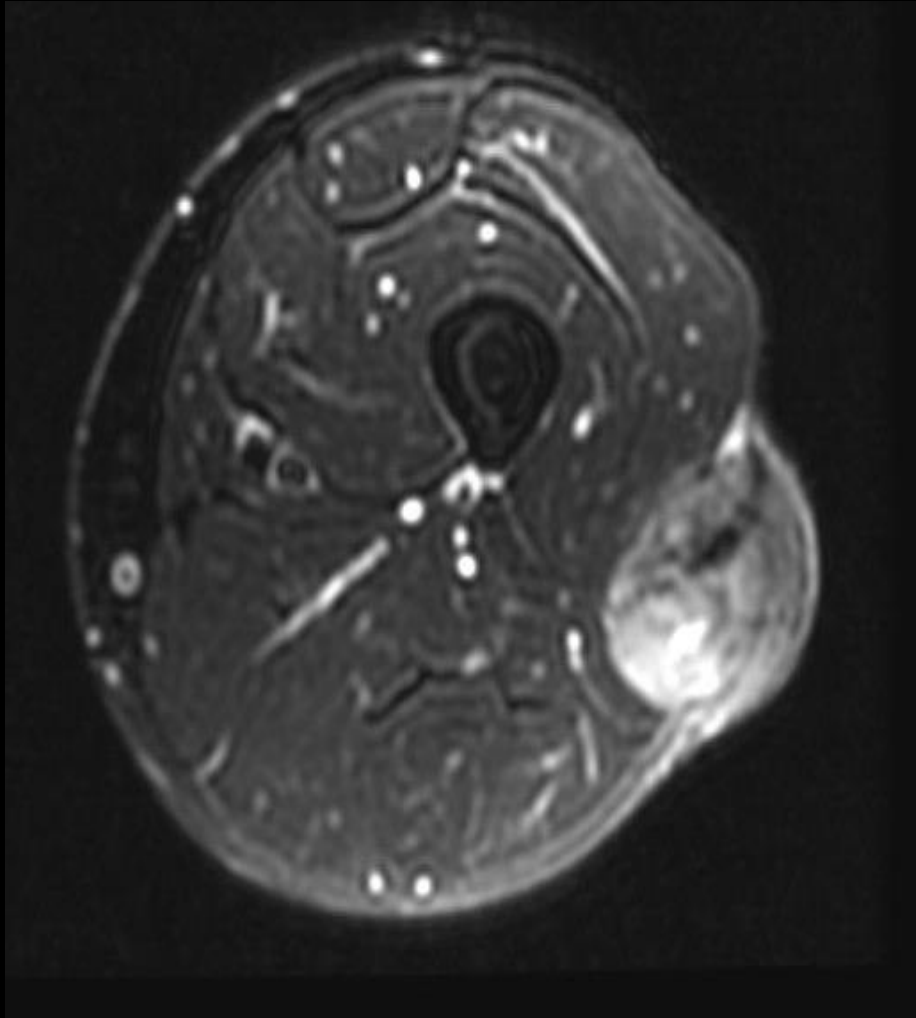
Answer:
Hematoma

Q24 46 y/o, male, a palpable firm nodule in his left lateral thigh for 18 years, with progressive enlargement in recent 4 years. What is your Diagnosis?

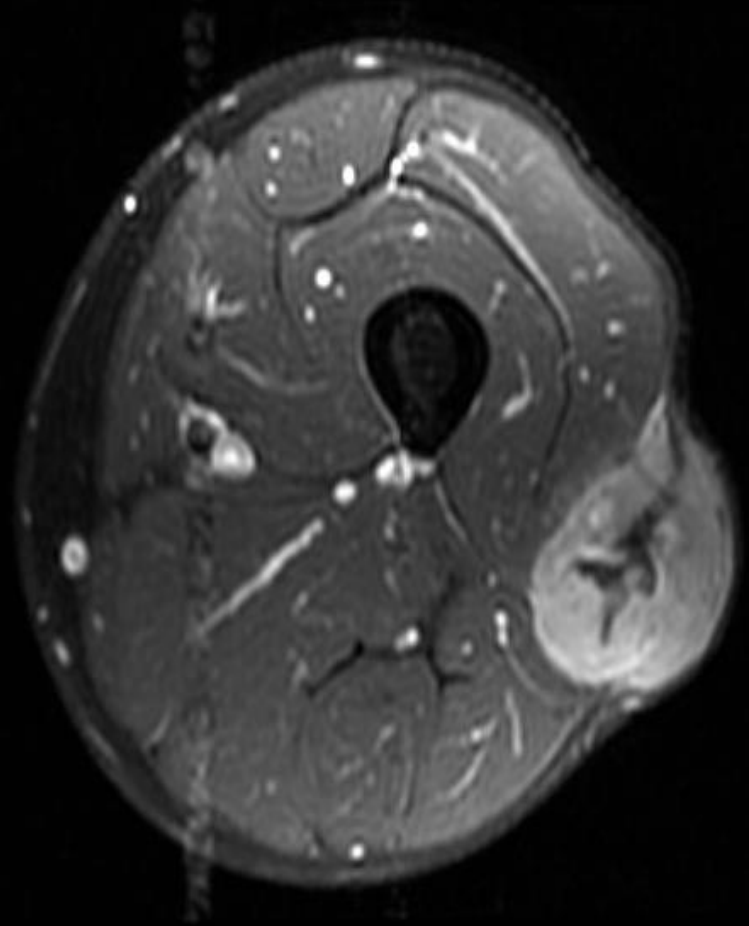
T1W



T2W

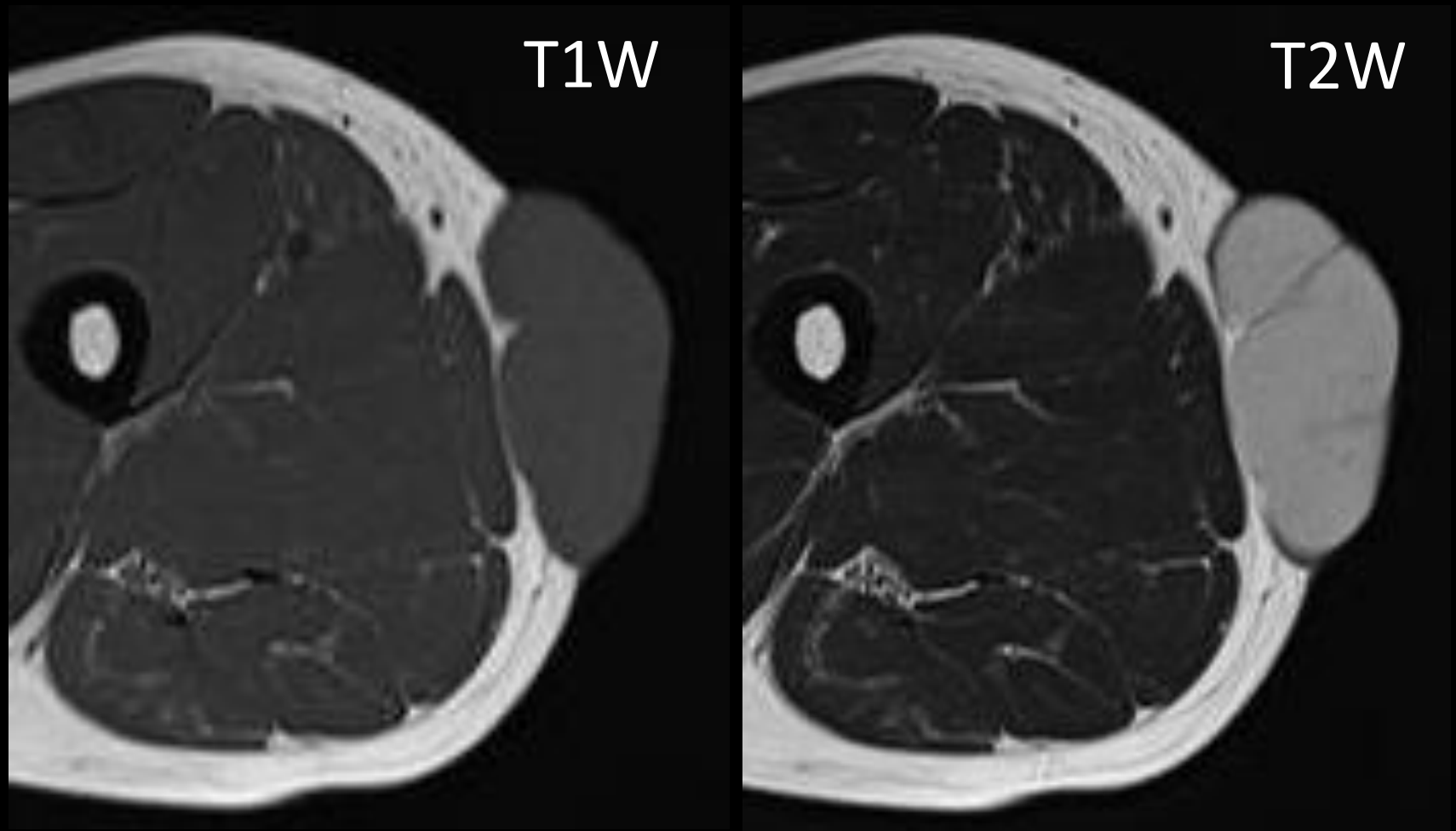


C+ T1FS

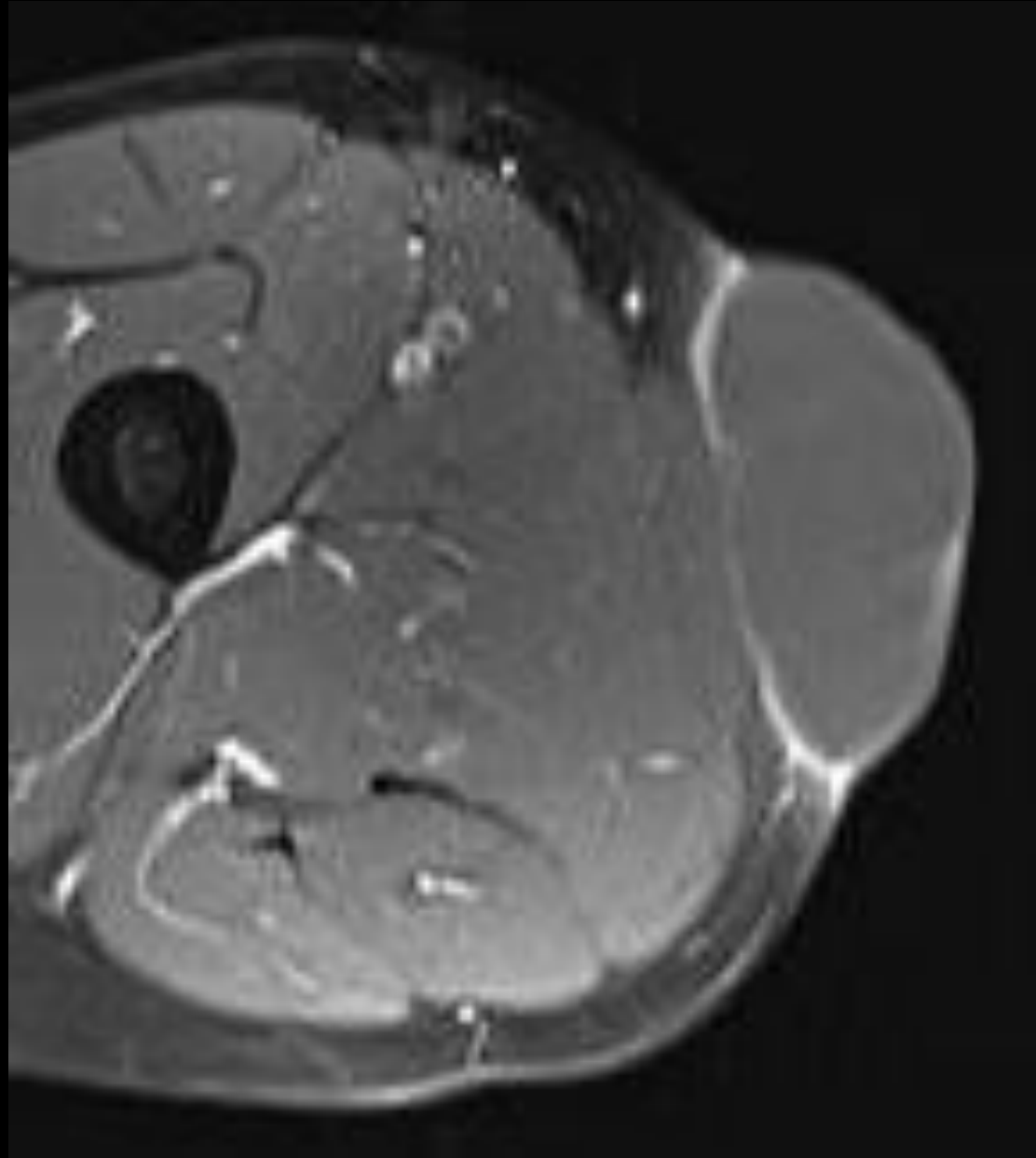


Answer:
Clear cell sarcoma

Q25 31 y/o, male, a palpable mass in his right medial thigh for 3 months. What is your Diagnosis?



C+ T1FS



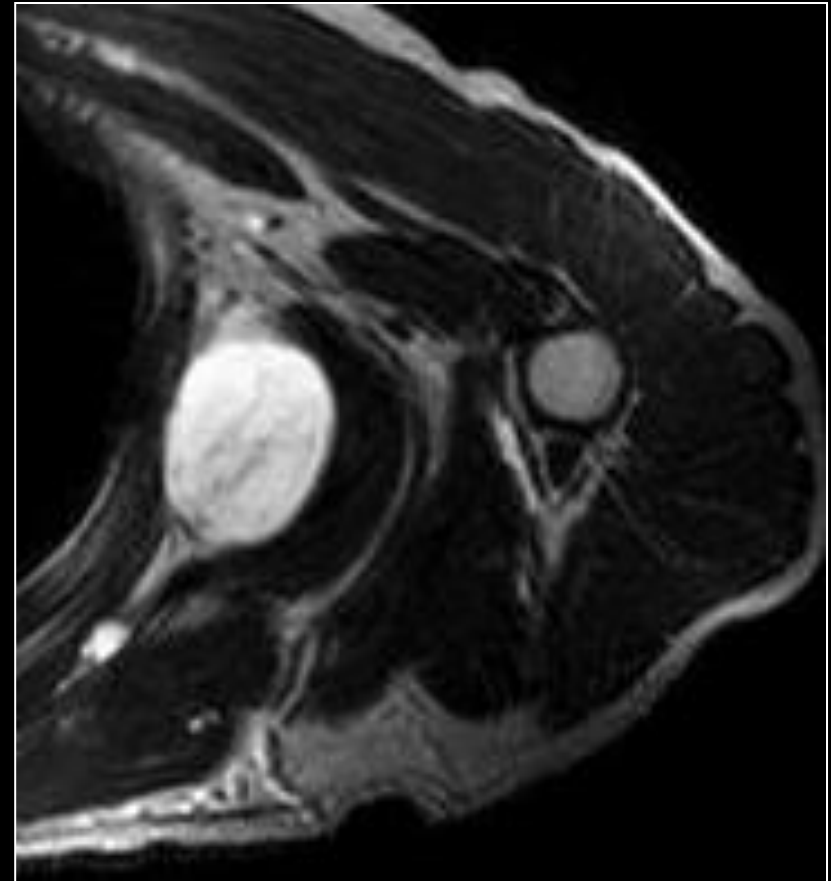
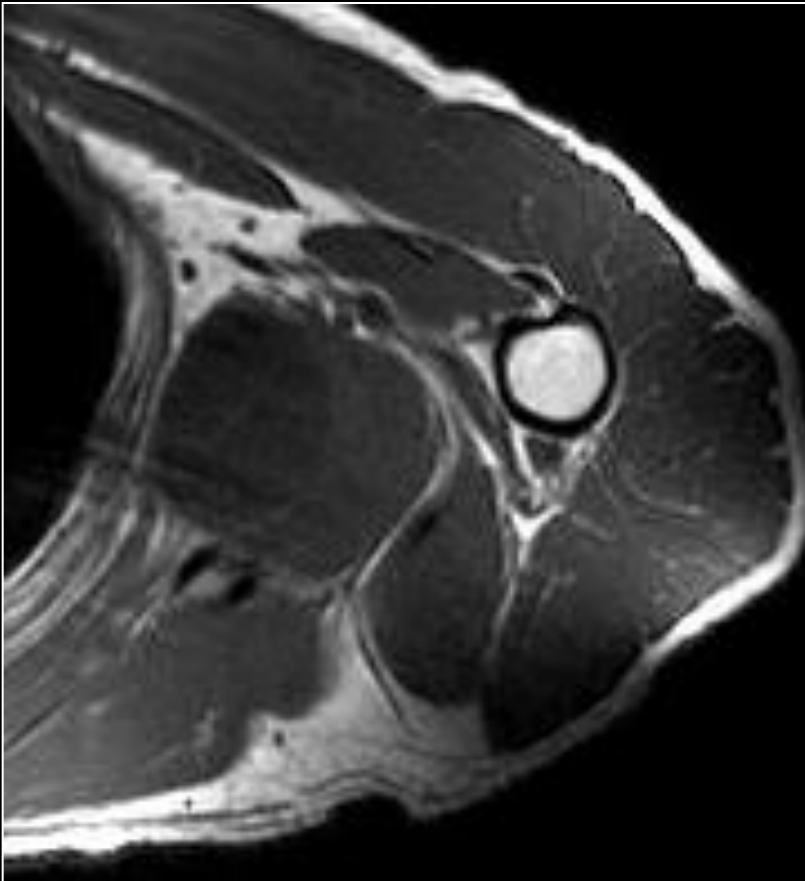
A25

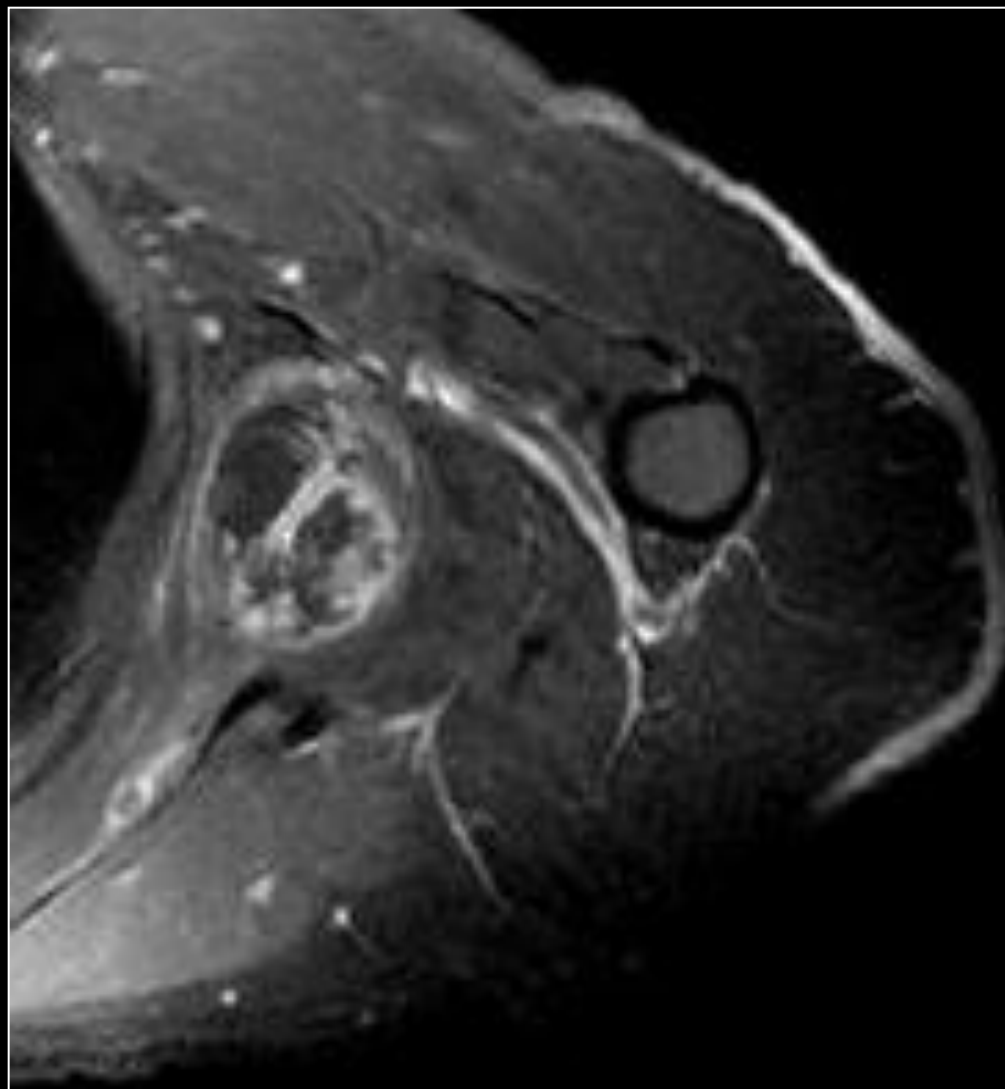
Answer:
Epidermal cyst

Q26 50 y/o, male, an incidental mass. What is your
Diagnosis?

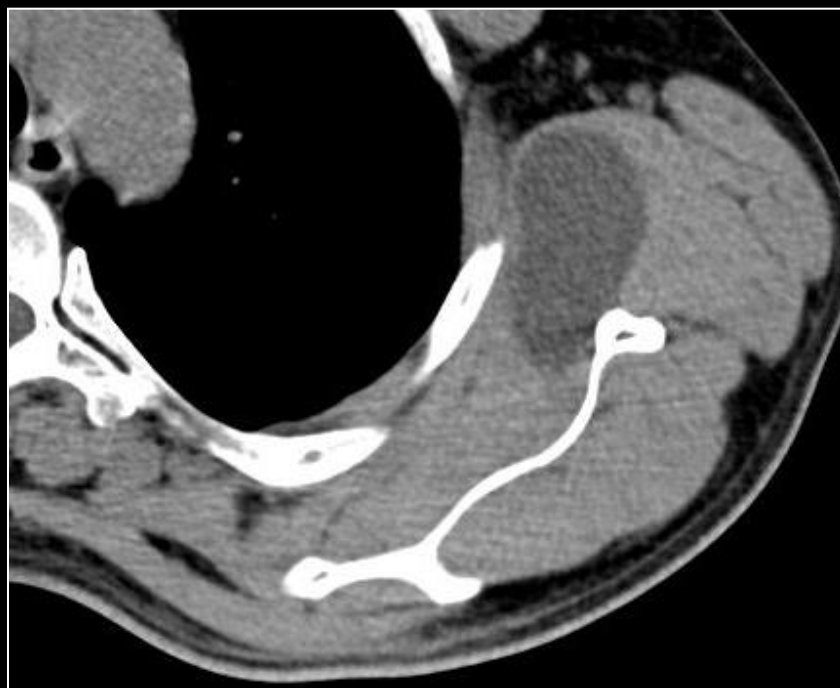T1W

T2W





C+ T1



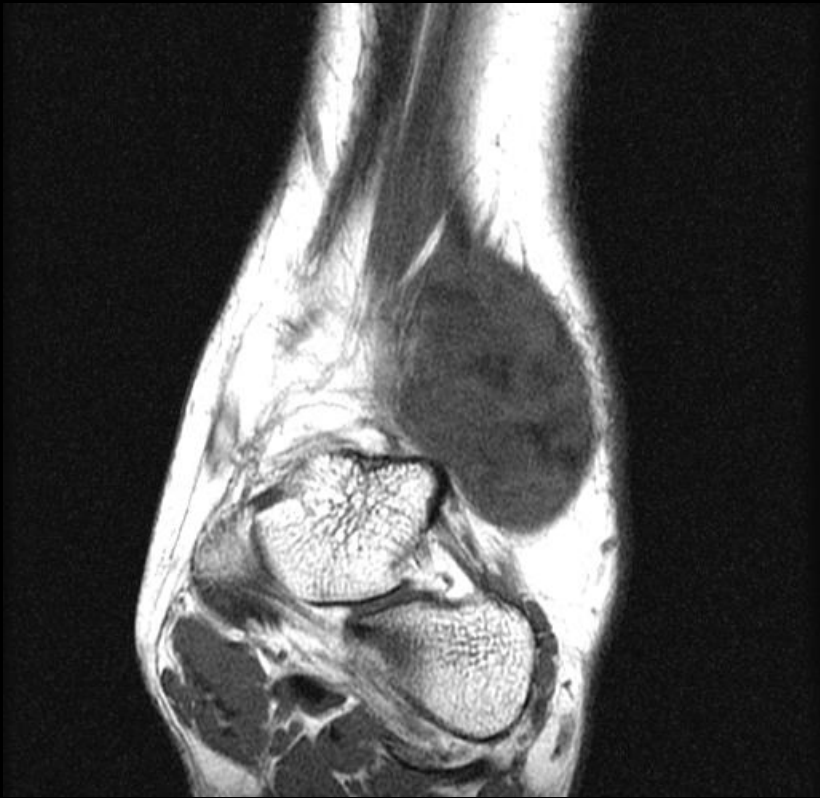CT

Answer:
Intramuscular myxoma

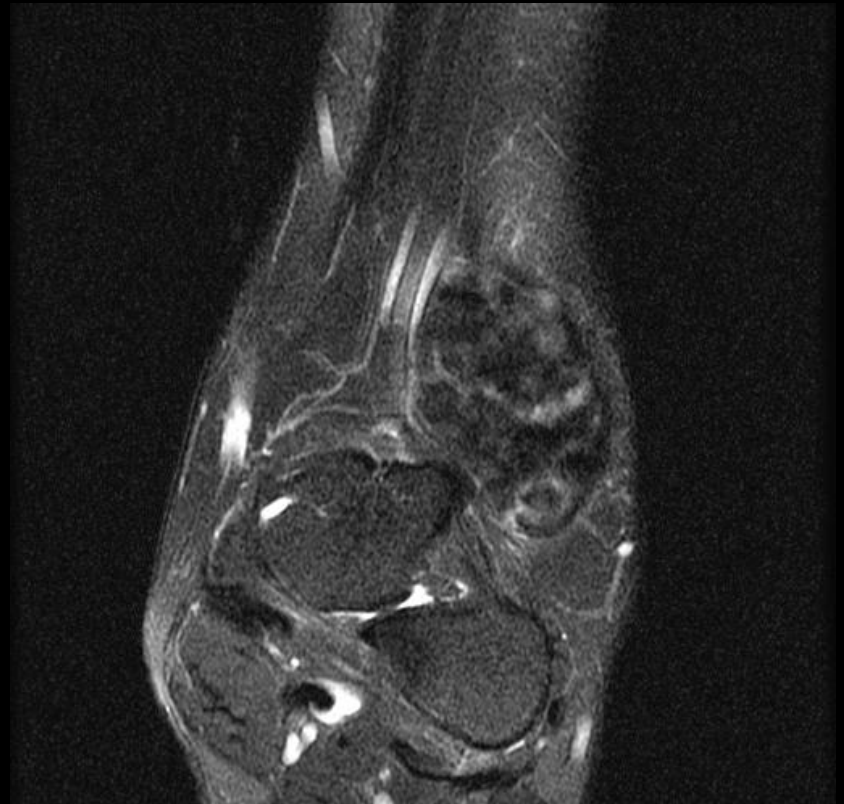Q27

41 y/o, female, a palpable mass in her left ankle for 3 months. What is your Diagnosis?

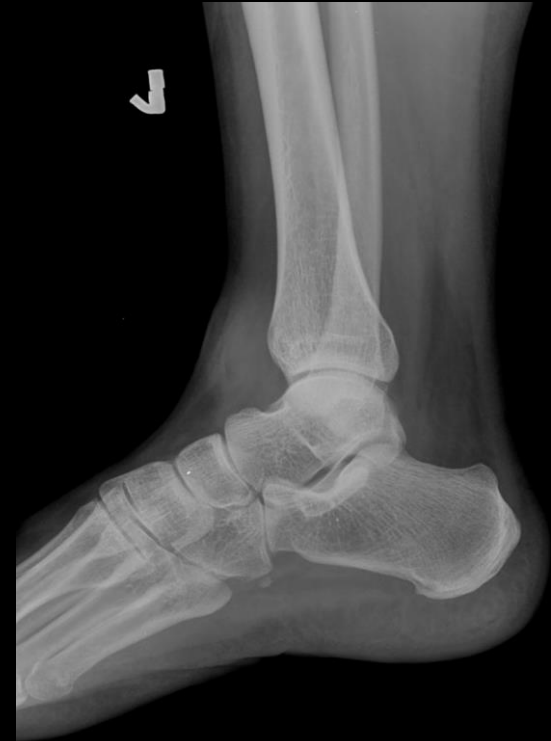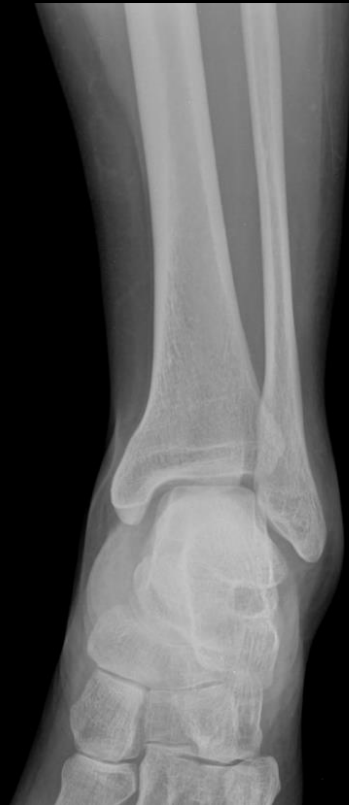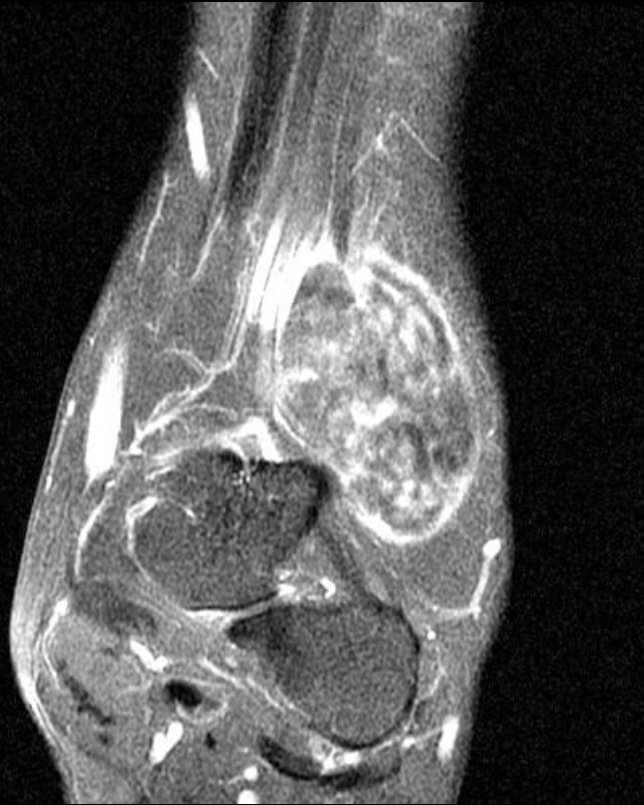
T1W



T2 FS



C+ T1FS



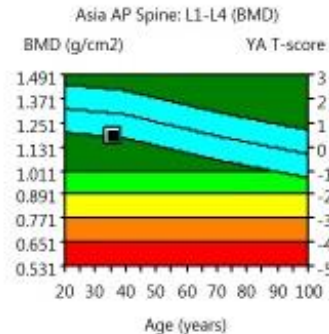
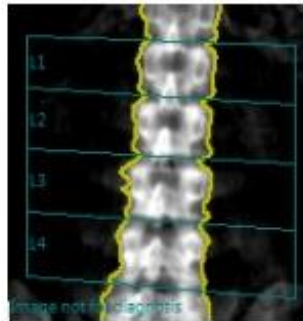
A27

Answer:
Fibromatosis

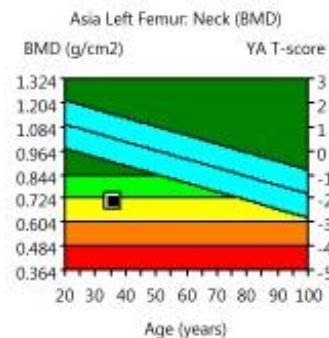
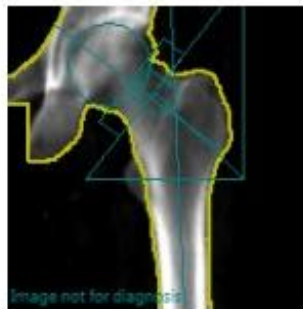Q28 35 y/o, Male, Asian. What is your Diagnosis?

Birth Date : 1979/7/20 35.9 years
 Height / Weight : 184.0 cm 105.0 kg
 Sex / Ethnic : Male Asian

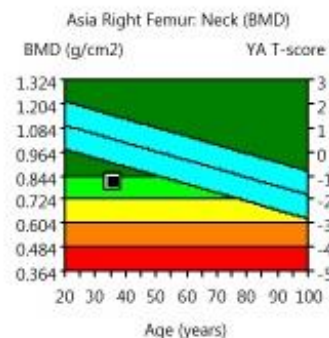
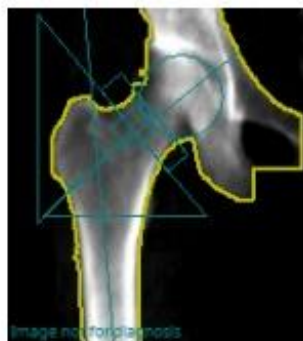Exam ID : 415625028000001
 Measured : 2015/7/2 下午04:26:10 (15 [SP 1])



Region	BMD (g/cm ²)	Young-Adult T-score	Age-Matched Z-score
L1	1.136	0.6	-0.8
L2	1.183	0.4	-1.0
L3	1.216	0.5	-0.8
L4	1.188	0.4	-1.1
L1-L2	1.160	0.5	-0.8
L1-L3	1.181	0.5	-0.8
L1-L4	1.183	0.4	-0.9
L2-L3	1.200	0.5	-0.9
L2-L4	1.196	0.4	-1.0
L3-L4	1.201	0.5	-0.9



Region	BMD (g/cm ²)	Young-Adult T-score	Age-Matched Z-score
Neck Left	0.707	-2.1	-2.7
Upper Neck Left	0.500	-	-
Lower Neck Left	0.910	-	-
Ward's Left	0.629	-1.8	-2.1
Troch Left	0.688	-1.0	-1.6
Shaft Left	0.935	-	-
Total Left	0.809	-1.2	-1.6



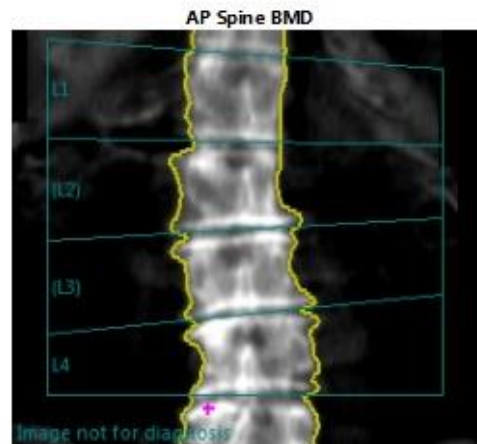
Region	BMD (g/cm ²)	Young-Adult T-score	Age-Matched Z-score
Neck Right	0.815	-1.2	-1.7
Upper Neck Right	0.693	-	-
Lower Neck Right	0.935	-	-
Ward's Right	0.719	-1.2	-1.5
Troch Right	0.771	-0.3	-0.9
Shaft Right	1.048	-	-
Total Right	0.901	-0.5	-0.9

Answer:
Below the expected range for age.

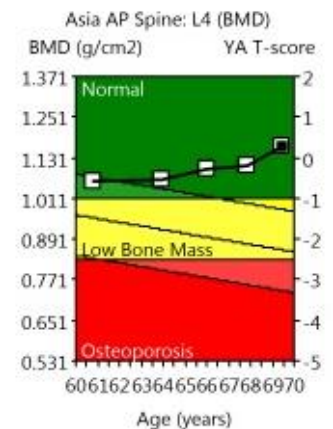
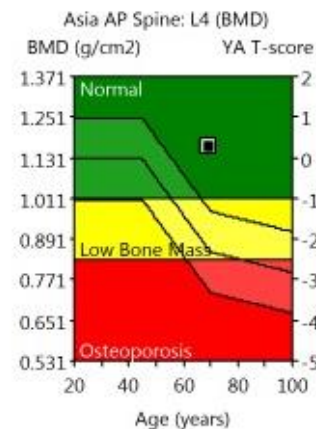
Q29 69 y/o, Female, Asian. The examination is compared to the technically similar prior study of the ____ (site). In the interim, there has been ____.

Patient ID: 41563002D000001
 Birth Date: 1946/1/16 69.4 years
 Height / Weight: 163.7 cm 53.5 kg
 Sex / Ethnic: Female Asian

Exam ID: 41563002D000001
 Measured: 2015/7/7 下午02:56:01 (15 [SP1])

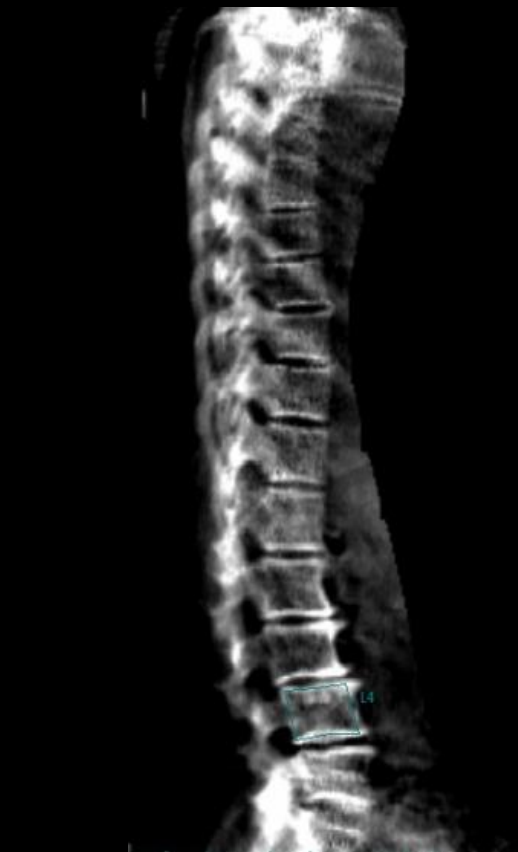

COMMENTS: 25098(K)



Region	BMD : Asia		
	BMD (g/cm2)	Young-Adult T-score	Age-Matched Z-score
L1	0.886	-1.3	1.1
L2	1.002	-0.9	1.6
L3	1.123	-0.1	2.4
L4	1.164	0.3	2.5
L1-L4 (L2,L3)	1.034	-0.5	2.0

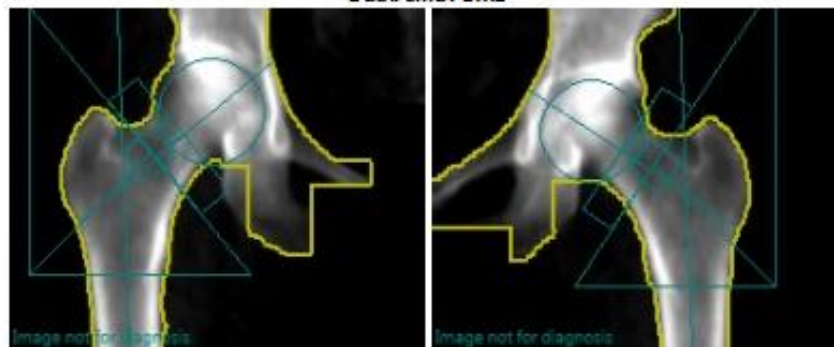
BMD Trend : L4				
Measured Date	Birth Date (years)	BMD (g/cm2)	Change vs Baseline (%)	Change vs Baseline (%/yr)
2015/7/7	69.4	1.164	9.8 *	1.1 *
2013/12/10	67.8	1.108	4.5	0.6
2012/2/6	66.0	1.098	3.6	0.7
2010/1/15	63.9	1.068	0.8	0.2
2006/11/13	60.8	1.060	baseline	baseline



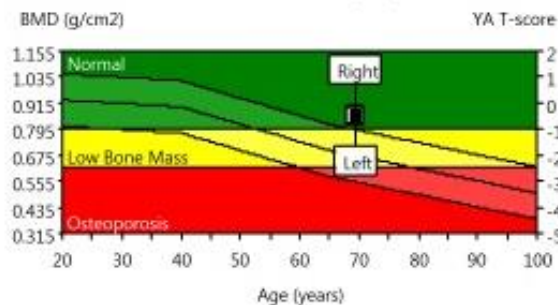
Birth Date : 1946/1/16 69.4 years
 Height / Weight : 163.7 cm 53.5 kg
 Sex / Ethnic : Female Asian

Exam ID : 41563002D000001
 Measured : 2015/7/7 下午 02:56:01 (15 [SP1])

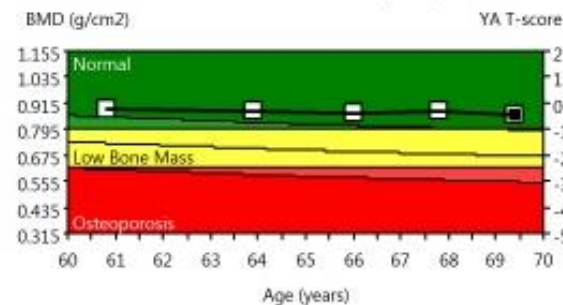
DualFemur BMD



Asia DualFemur: Neck (BMD)



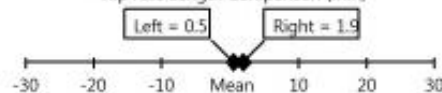
Asia DualFemur: Neck Mean (BMD)



BMD : Asia			
Region	BMD (g/cm ²)	Young Adult T-score	Age-Matched Z-score
Neck Left	0.855	-0.5	1.5
Neck Right	0.863	-0.4	1.6
Neck Mean	0.859	-0.5	1.6
Neck Diff.	0.008	0.1	0.1
Total Left	0.882	-0.6	1.1
Total Right	0.874	-0.6	1.0
Total Mean	0.878	-0.6	1.0
Total Diff.	0.008	0.1	0.1

Trend : Neck Mean				
Measured Date	Measured Age (years)	BMD (g/cm ²)	Change vs Baseline (%)	Change vs Baseline (%/yr)
2015/7/7	69.4	0.859	-0.016	-1.8
2013/12/10	67.8	0.875	0.007	0.8
2012/2/6	66.0	0.868	-0.009	-1.0
2010/1/15	63.9	0.877	-0.009	-1.0
2006/11/13	60.8	0.886	-	-

Hip Axis Length Comparison (mm)



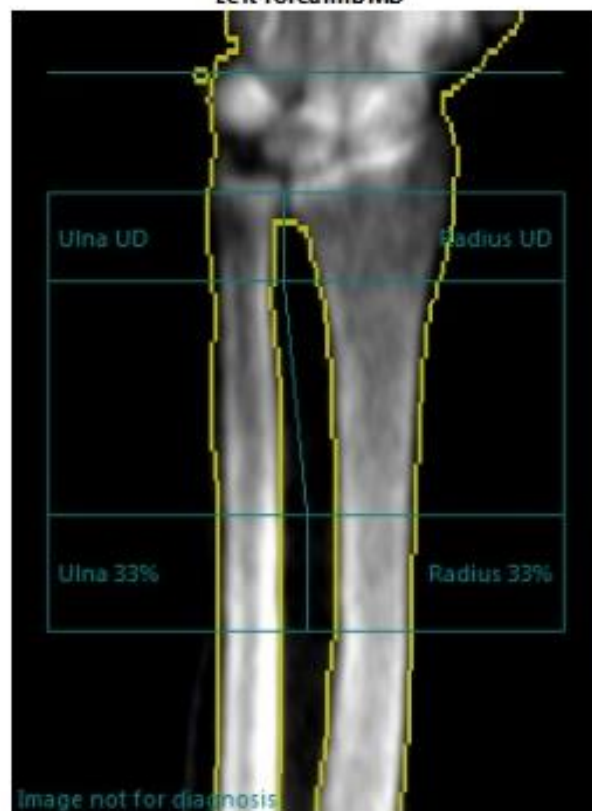
Right = 105.0 mm Avg = 103.1 mm Left = 103.6 mm

COMMENTS: 25098(K)

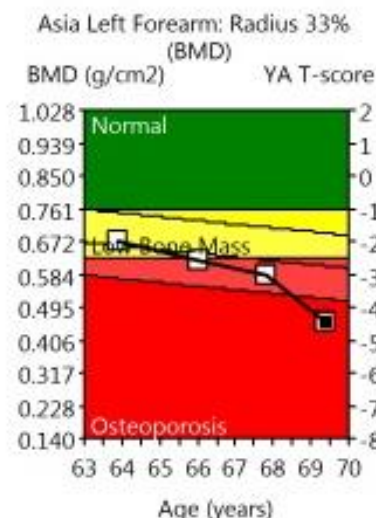
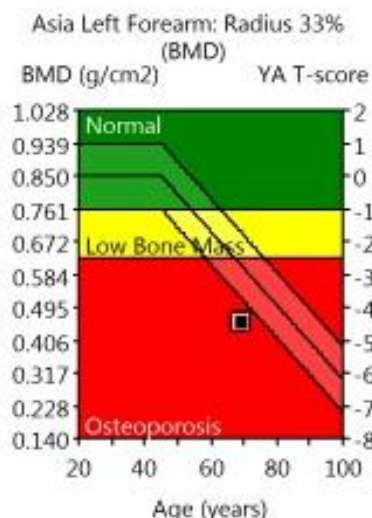
Birth Date : 1946/1/16 69.4 years
 Height / Weight : 163.7 cm 53.5 kg
 Sex / Ethnic : Female Asian

Exam ID : 41563002D000001
 Measured : 2015/7/7 下午 02:56:01 (15 [SP 1])

Left ForearmBMD



COMMENTS: 25098(K)



Region	BMD : Asia		
	BMD (g/cm ²)	Young-Adult T-score	Age-Matched Z-score
Radius UD	0.234	-4.7	-2.0
Ulna UD	0.211	-	-
Radius 33%	0.457	-4.4	-1.7
Ulna 33%	0.526	-	-
Both UD	0.227	-	-
Both 33%	0.487	-	-
Radius Total	0.333	-5.3	-2.5
Ulna Total	0.349	-	-
Both Total	0.340	-	-

BMD Trend : Radius 33%				
Measured Date	Birth Date (years)	BMD (g/cm ²)	Change vs Baseline (%)	Change vs Baseline (%/yr)
2015/7/7	69.4	0.457	-32.3 *	-5.9 *
2013/12/10	67.8	0.582	-13.8	-3.5 *
2012/2/6	66.0	0.620	-8.1	-4.0
2010/1/15	63.9	0.675	baseline	baseline


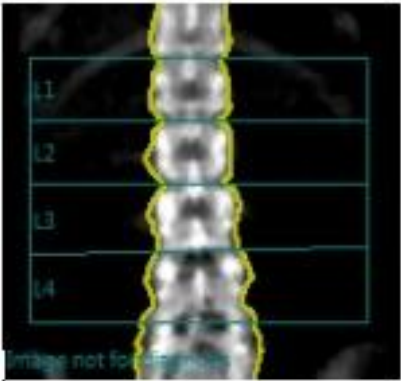
Answer:

Forearm, a significant decrease of BMD.

Q30

36 y/o, Female, Asian. The BMD measured in the _____ (specify levels?) region chosen is correct.

Birth Date :	1978/8/10 36.9 years	Exam ID :	41572906C000001
Height / Weight :	159.0 cm 48.2 kg	Measured :	2015/8/5 下午03:11:09 (15 [SP1])
Sex / Ethnic :	Female Asian		

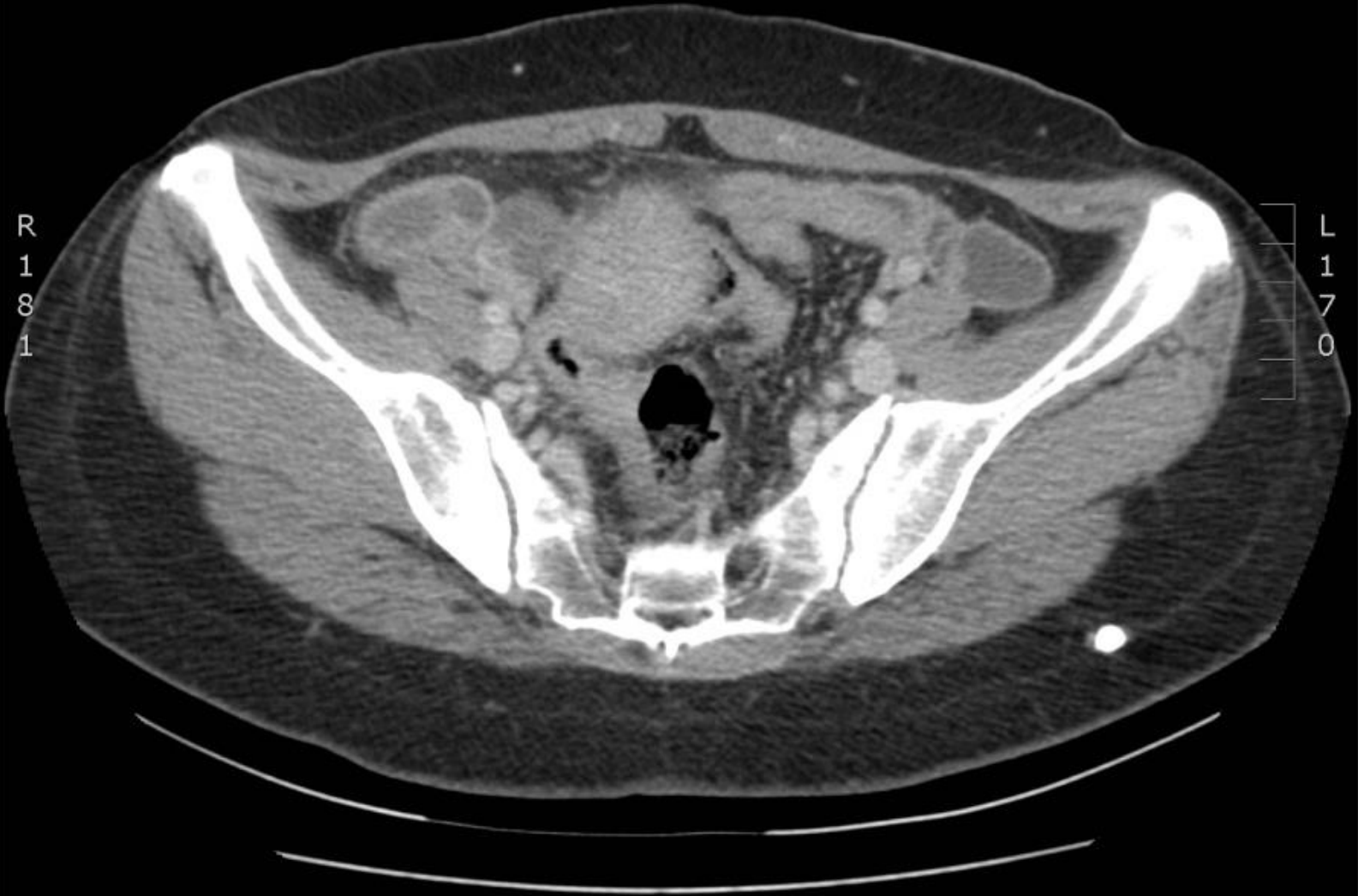


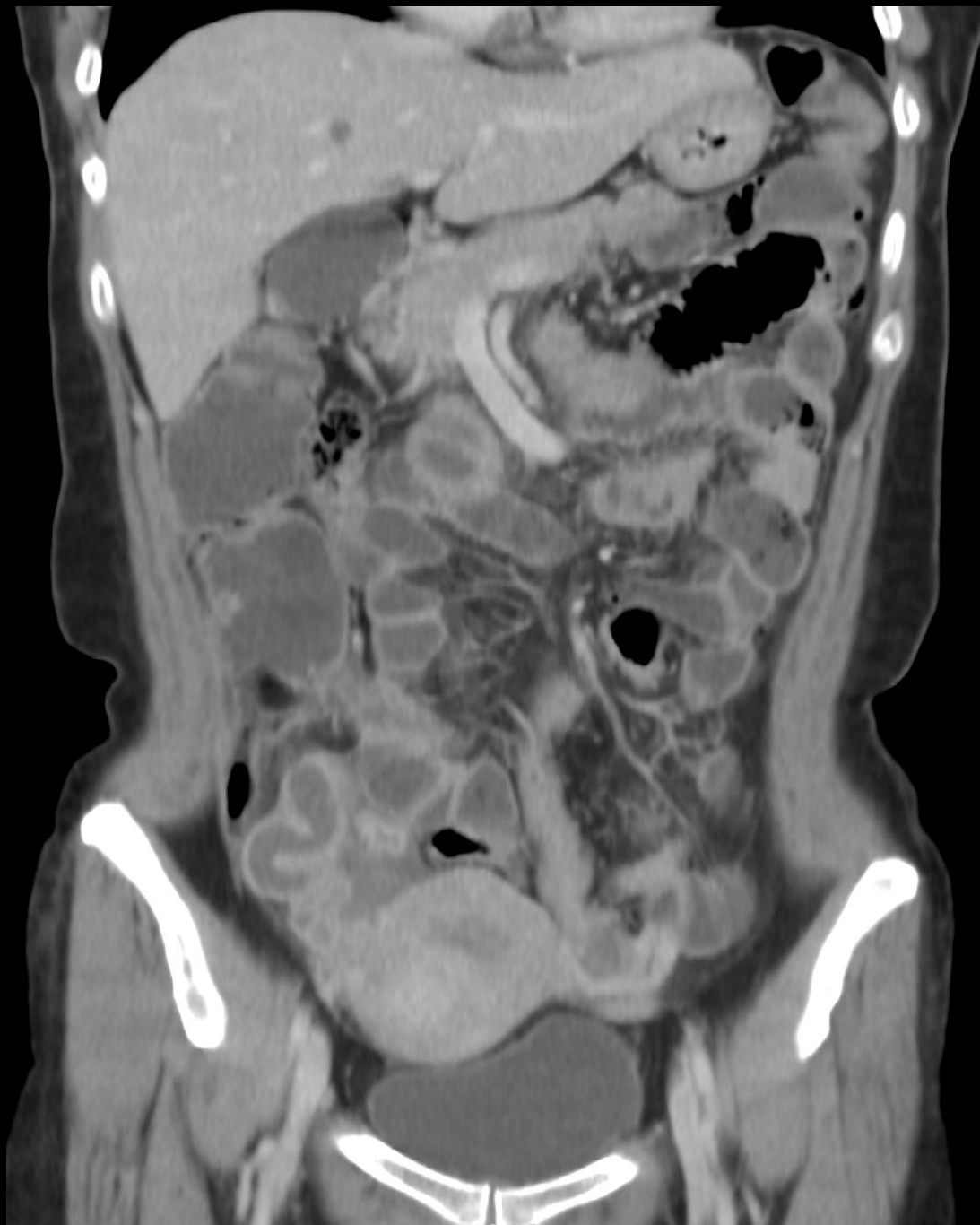Region	BMD (g/cm ²)	Young-Adult T-score	Age-Matched Z-score
L1	1.097	0.4	0.8
L2	1.162	0.4	0.7
L3	1.272	1.1	1.5
L4	1.106	-0.2	0.1
L1-L2	1.131	0.4	0.8
L1-L3	1.184	0.7	1.0
L1-L4	1.159	0.4	0.7
L2-L3	1.221	0.8	1.1
L2-L4	1.175	0.4	0.7
L3-L4	1.179	0.4	0.7

A30

Answer:
L1-3

Q31 49 y/o Female, Fever, lower abdominal pain for 2 days, What is your Diagnosis?





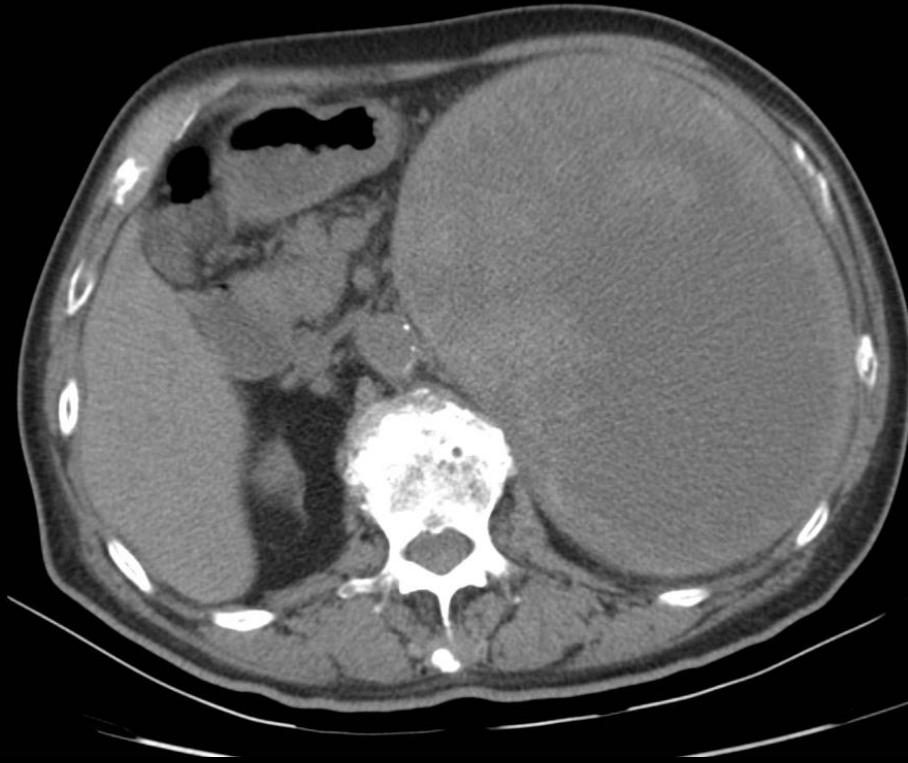
SI

A31

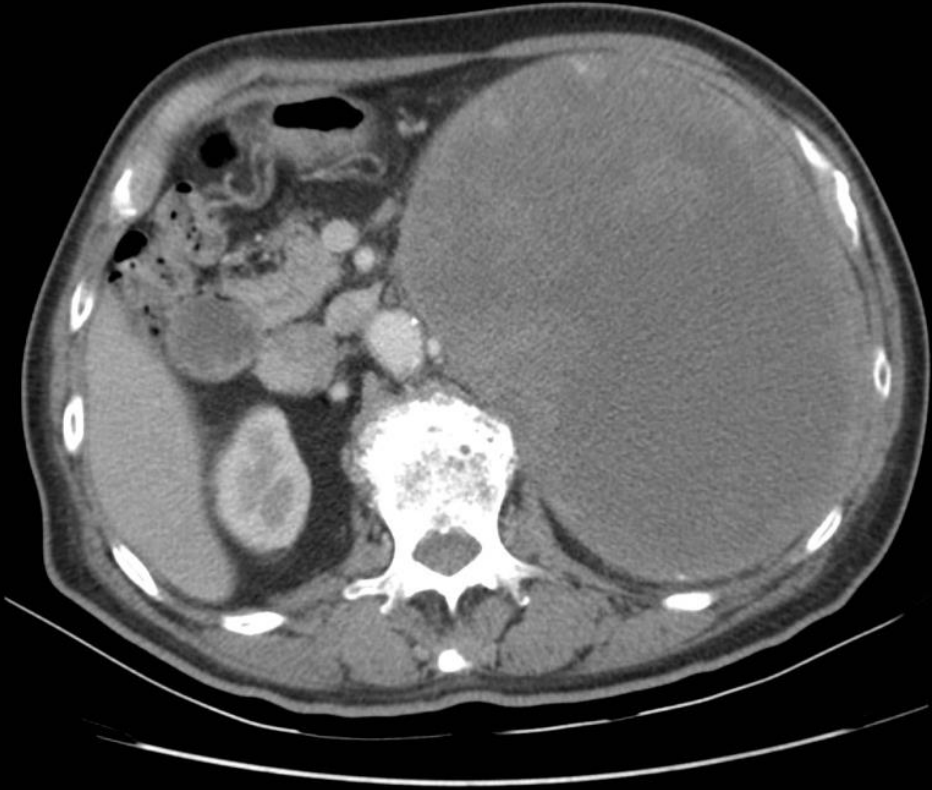Answer:
Pyosalpinx

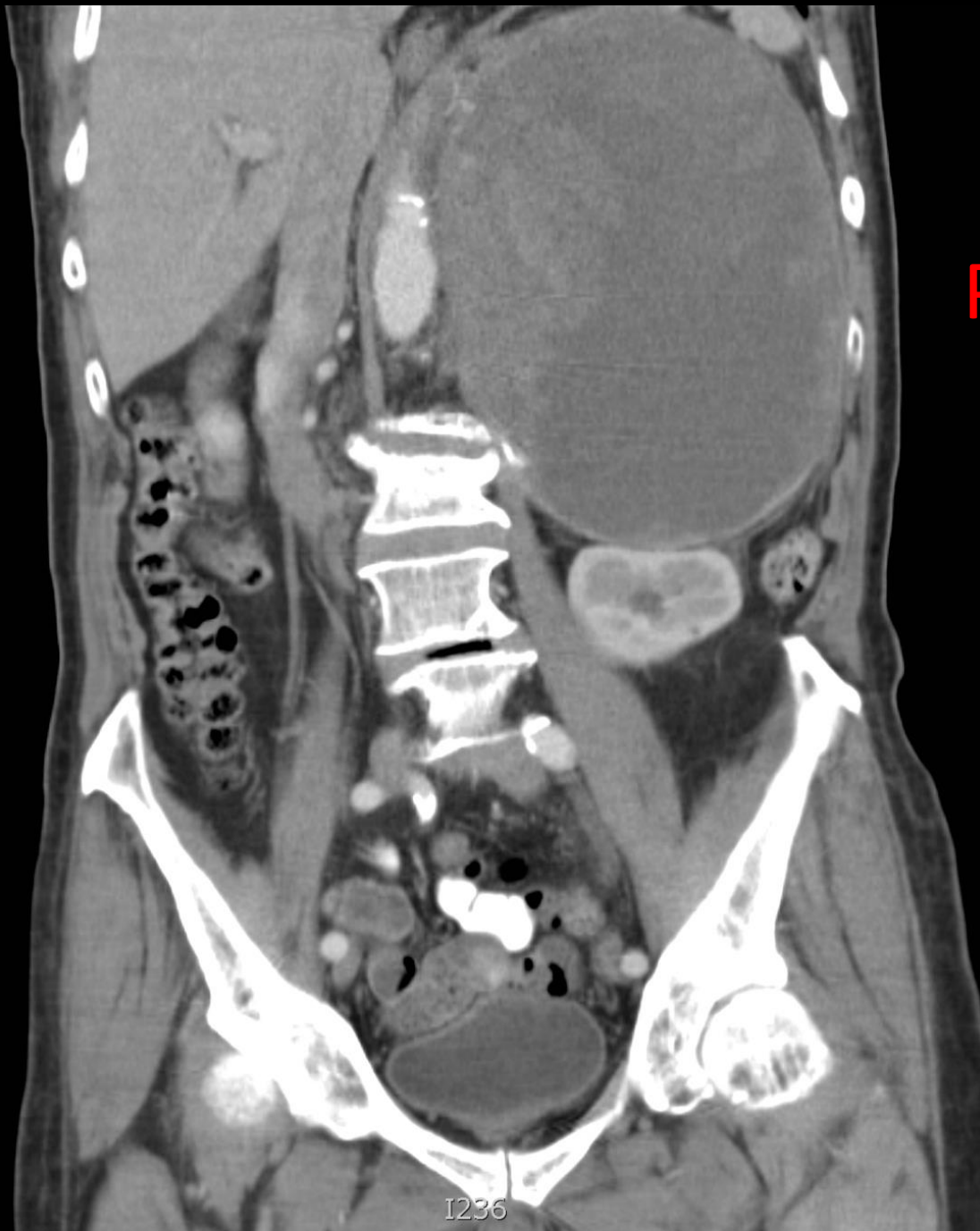Q32 74 y/o male, Palpable LUQ mass, What is your Diagnosis?

Precontrast CT



Post contrast CT





Post contrast CT

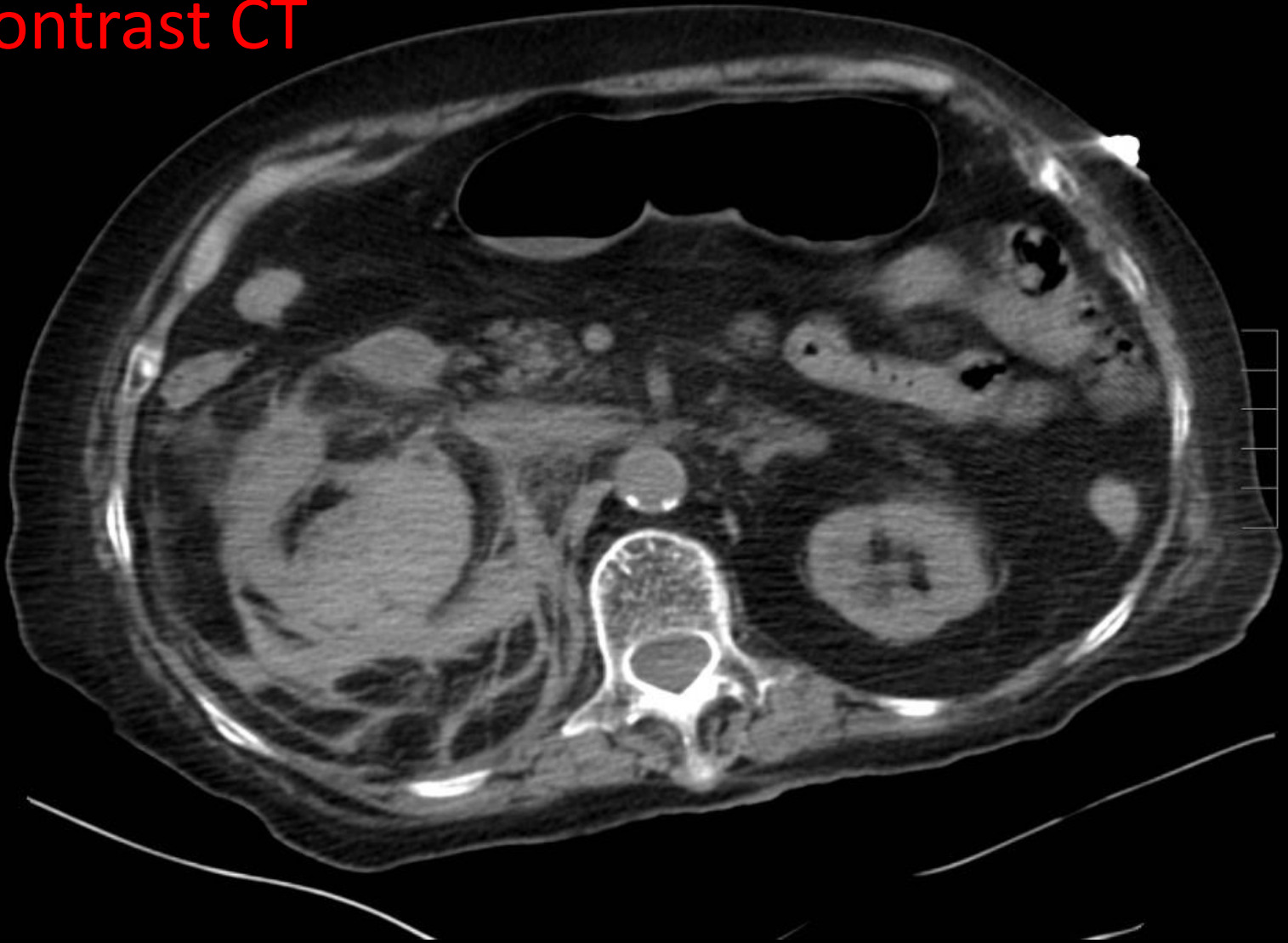
I236

Answer:

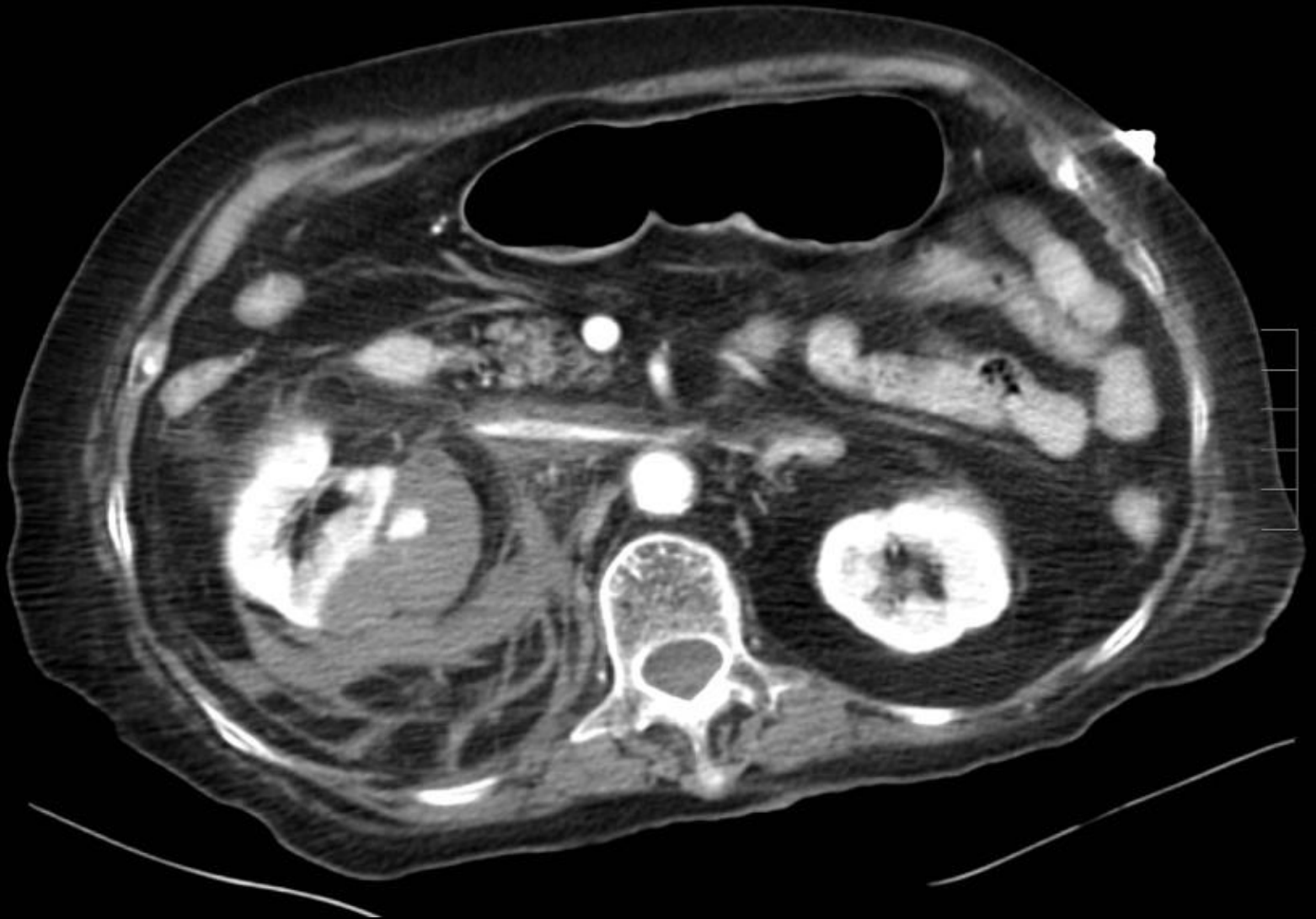
Hemorrhagic cyst of left adrenal gland

Q33 84 y/o Female, trauma, What is your Diagnosis?

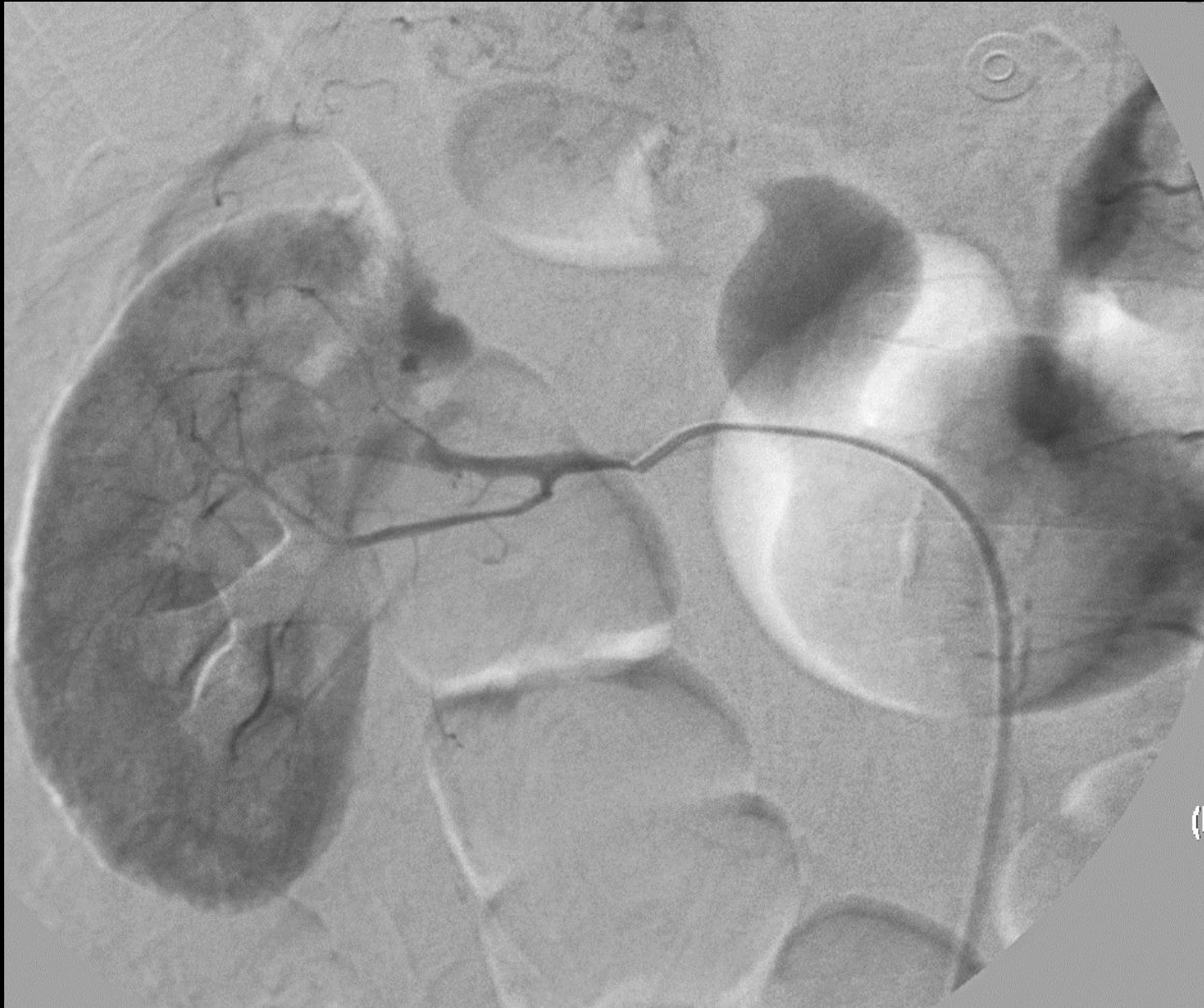Pre contrast CT



Post contrast CT



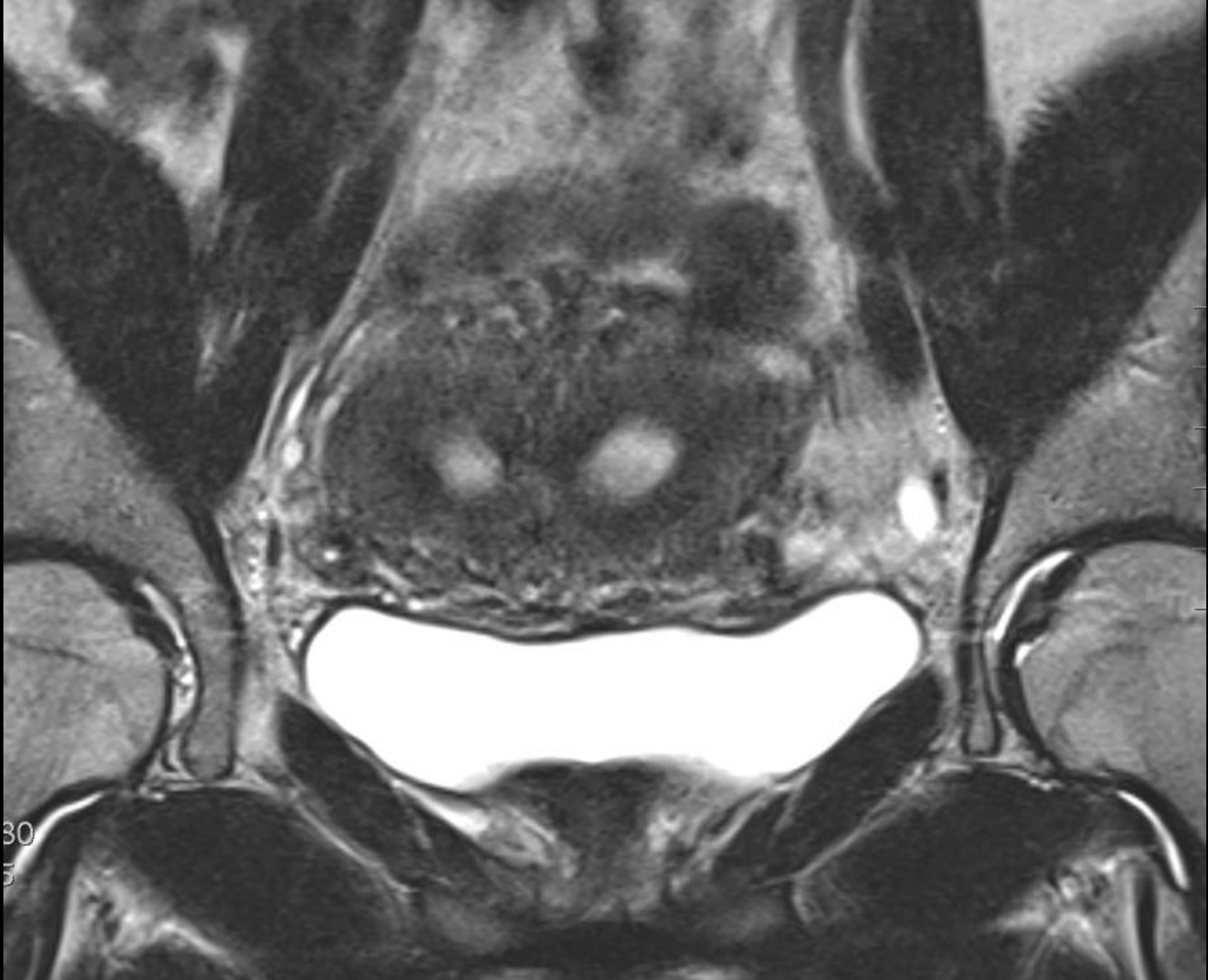
Angiography



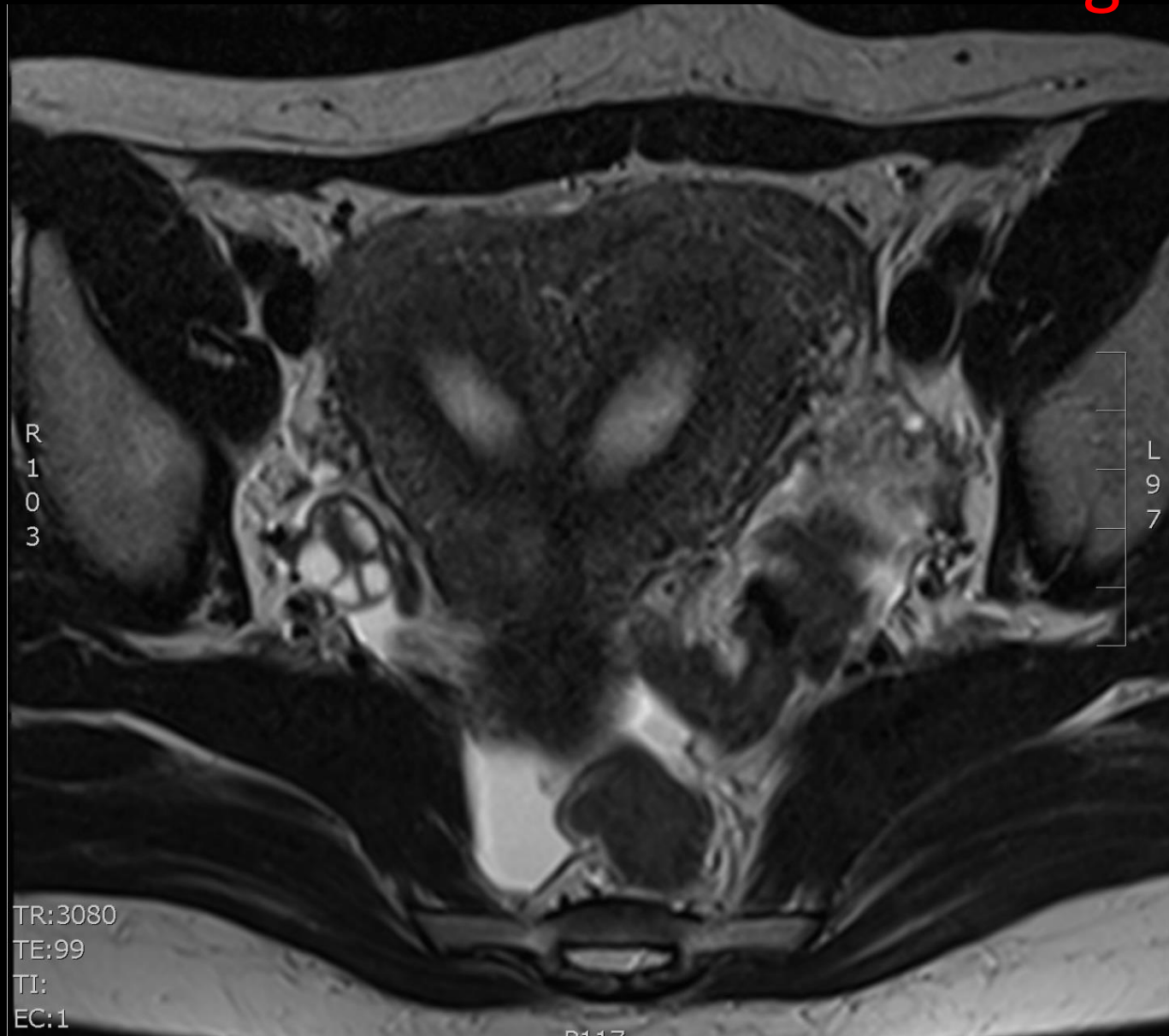
Answer:

Pseudoaneurysm of right renal artery

Q34 37 y/o Female, Incidental finding, What is your
Diagnosis? **T2W image of MR**



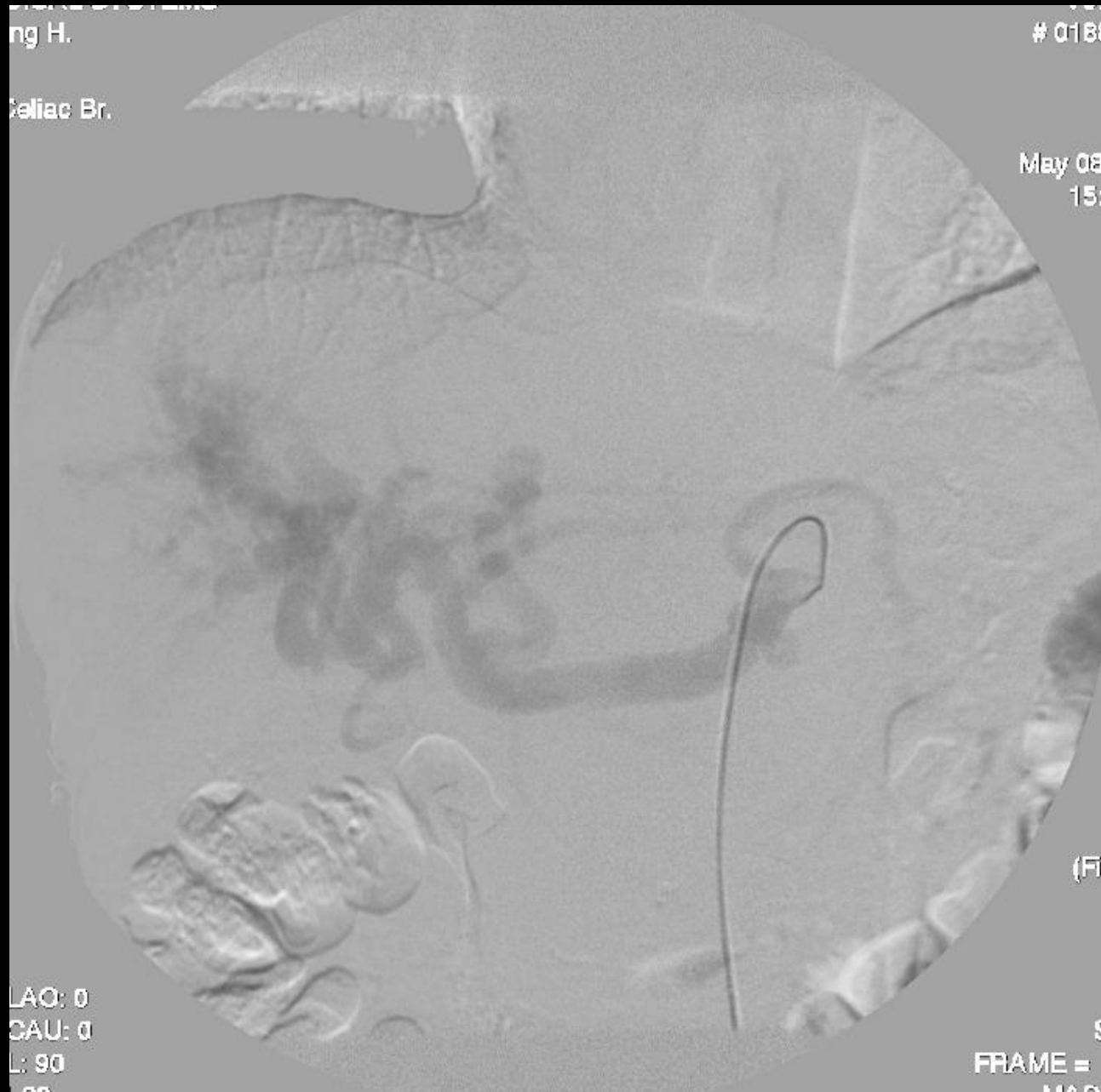T2W image of MR



A34

Answer:
Septate uterus

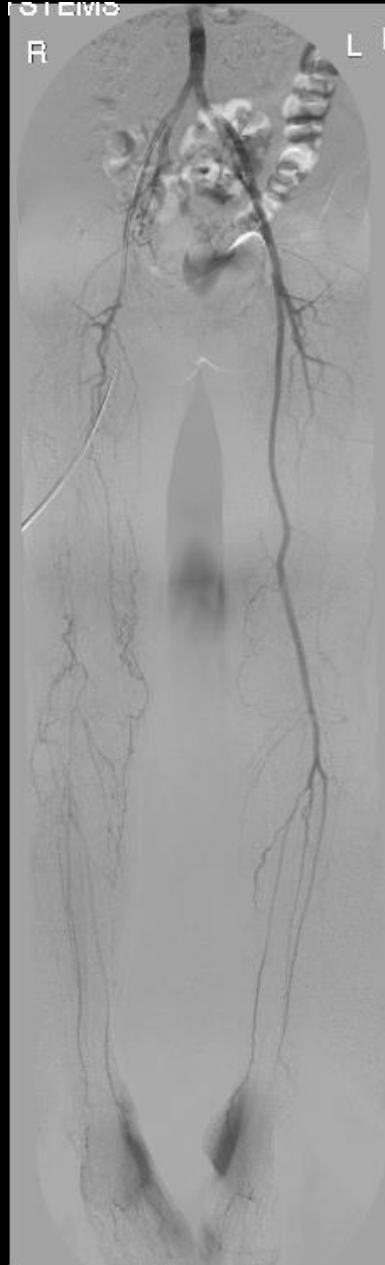Q35 75 y/o male, What is your Diagnosis?



Answer:

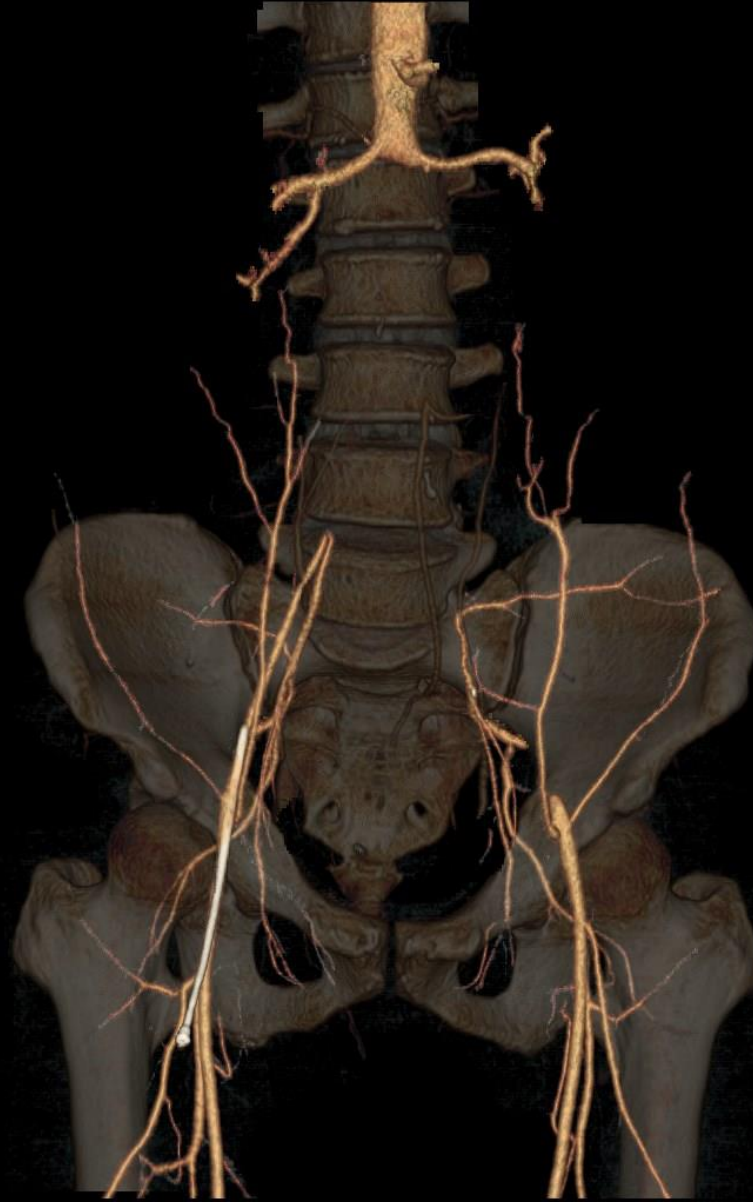
Hereditary hemorrhagic telangiectasia

Q36 30 y/o Female, What is your Diagnosis?



Answer:
Beurger's disease

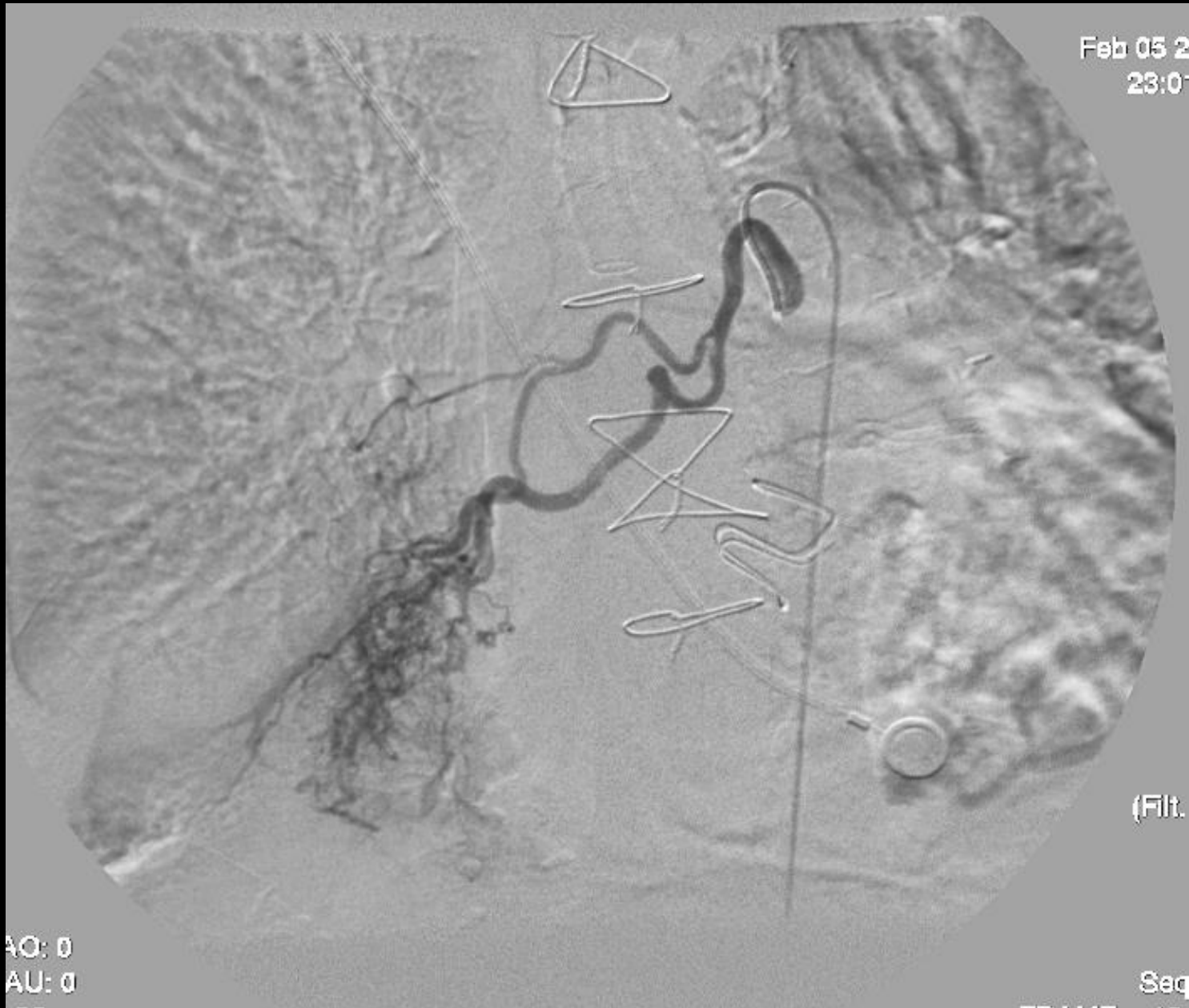
Q37 50 y/o male, What is your Diagnosis?



Answer:

Leriche syndrome

Q38 hemoptysis, 此條出血的血管為何?

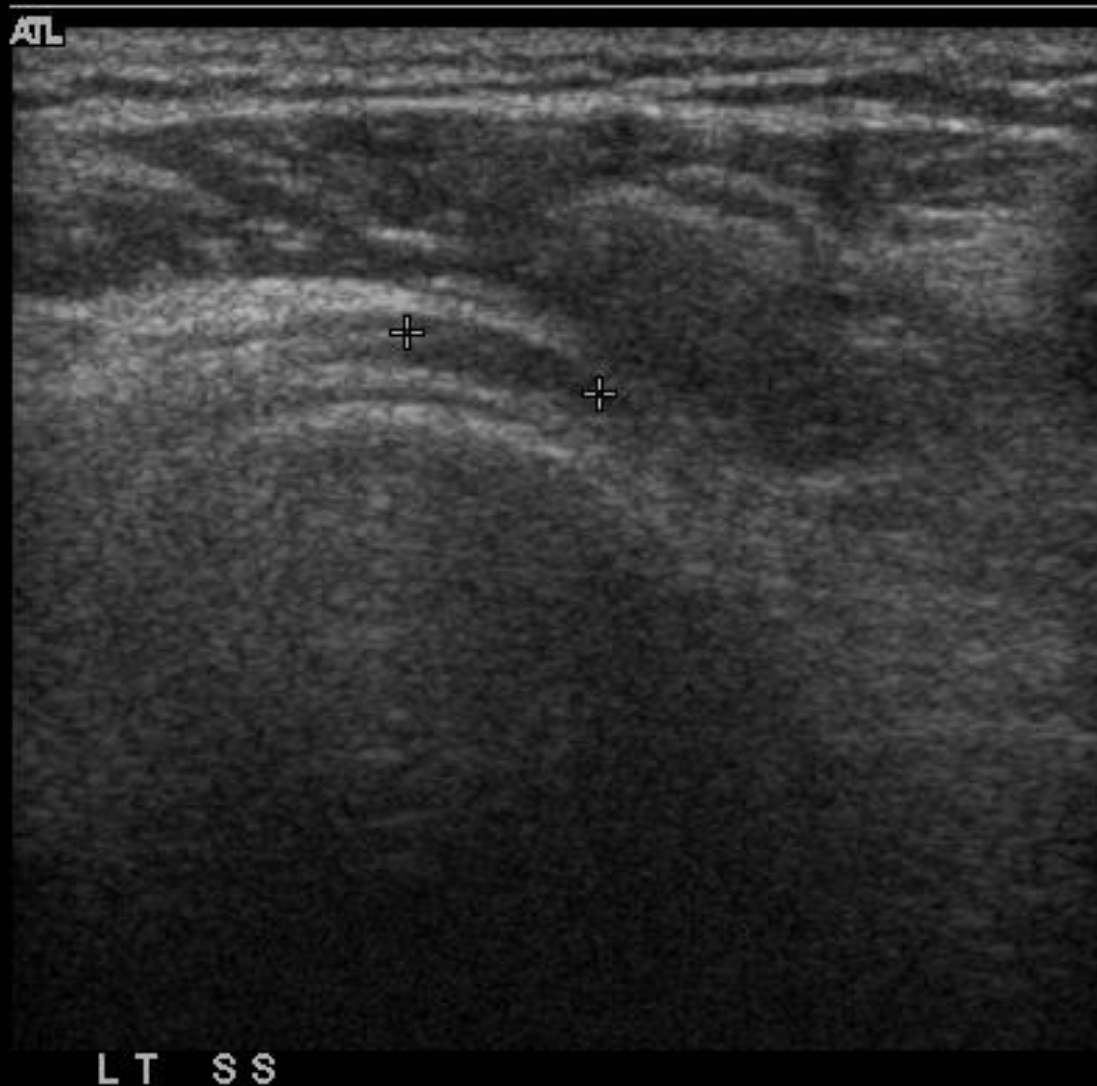


Answer:

Right bronchial artery

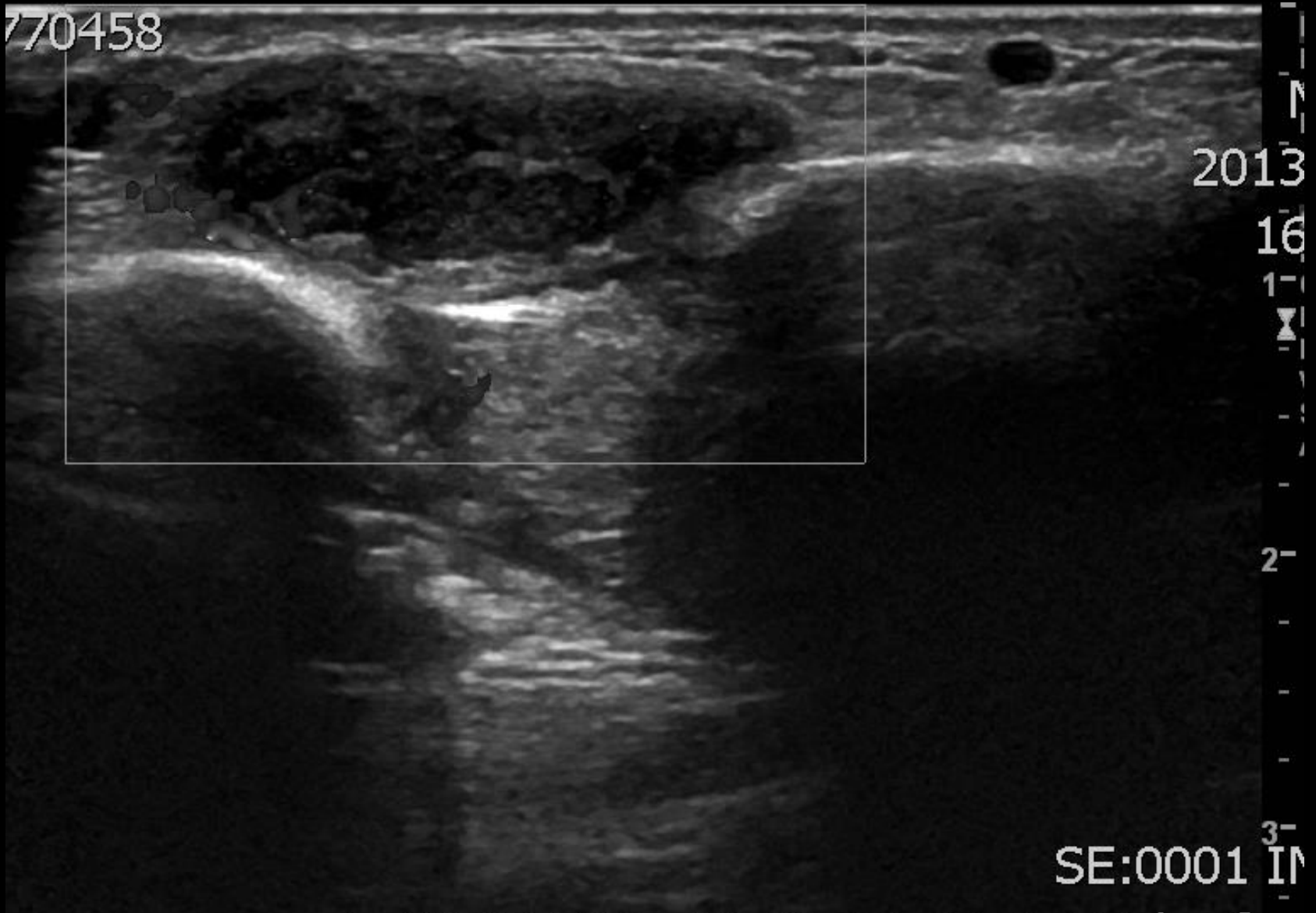
Q39 63 y/o Male, L't Shoulder pain, What is your Diagnosis?

Map 6
130dB/C 6
Persist Med
Fr Rate High
2D Opt:Res



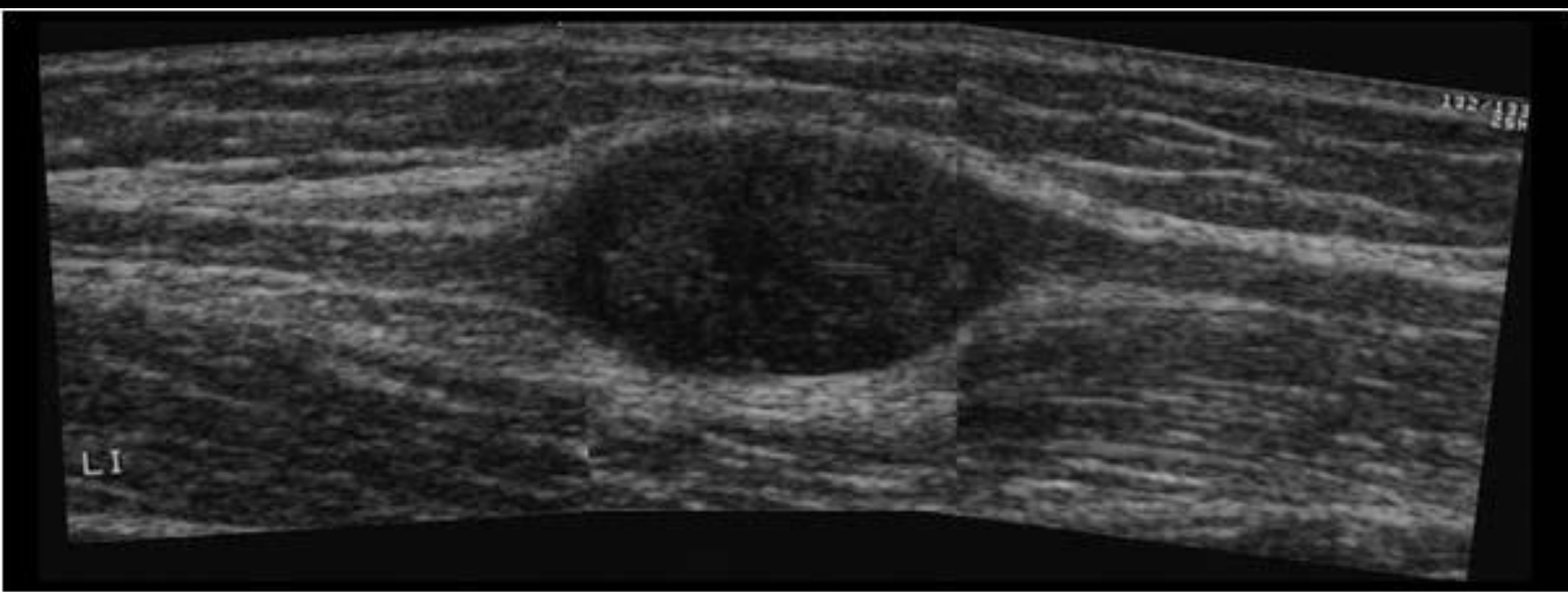
Answer:
Rotator cuff tear.

Q40 49 y/o Male, L't hand tumor for year with progressive enlargement, What is your Diagnosis?



Answer:
Neurilemoma.

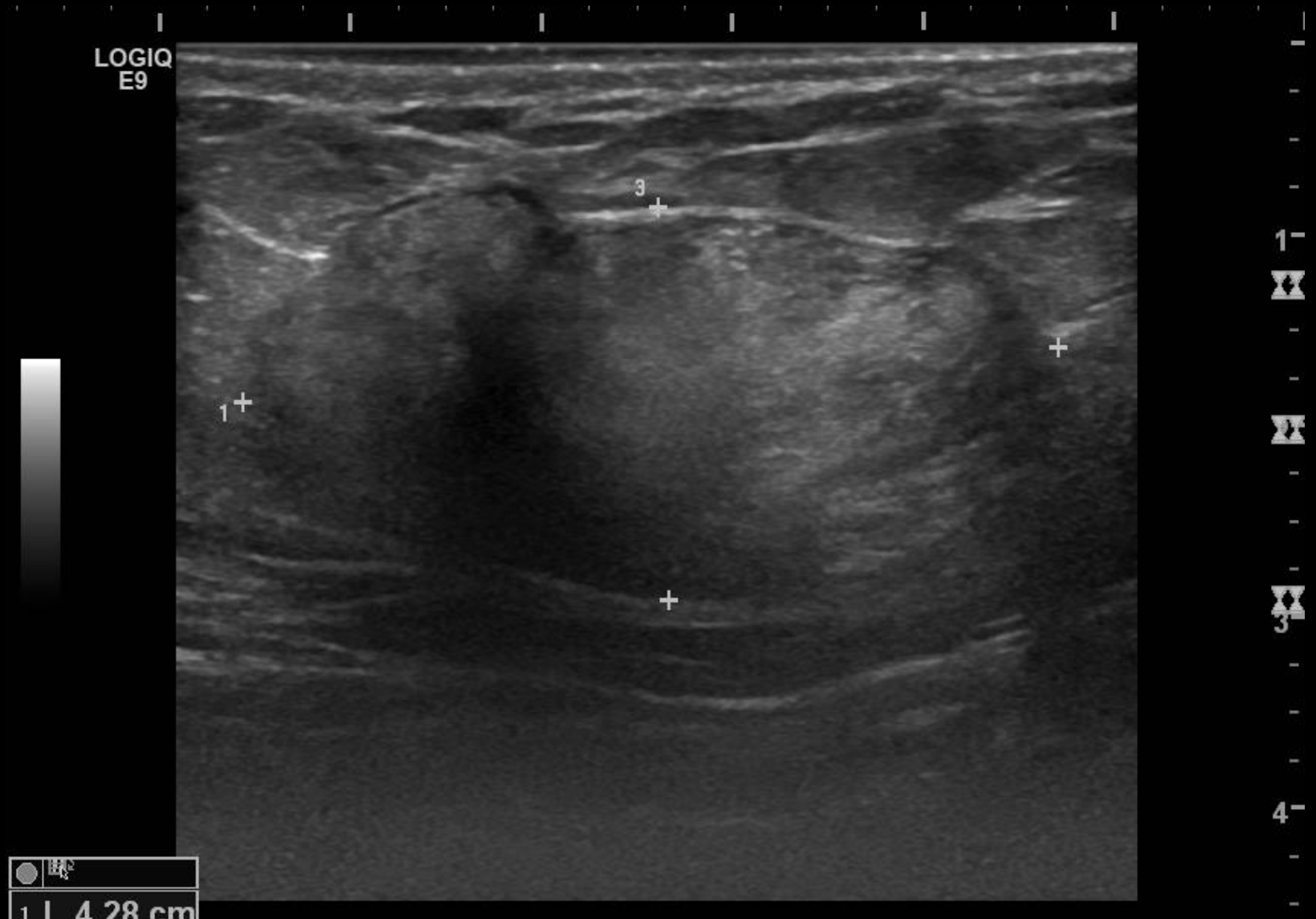
Q41 Soft tissue mass, soft, radiation pain when compression, What is your Diagnosis?



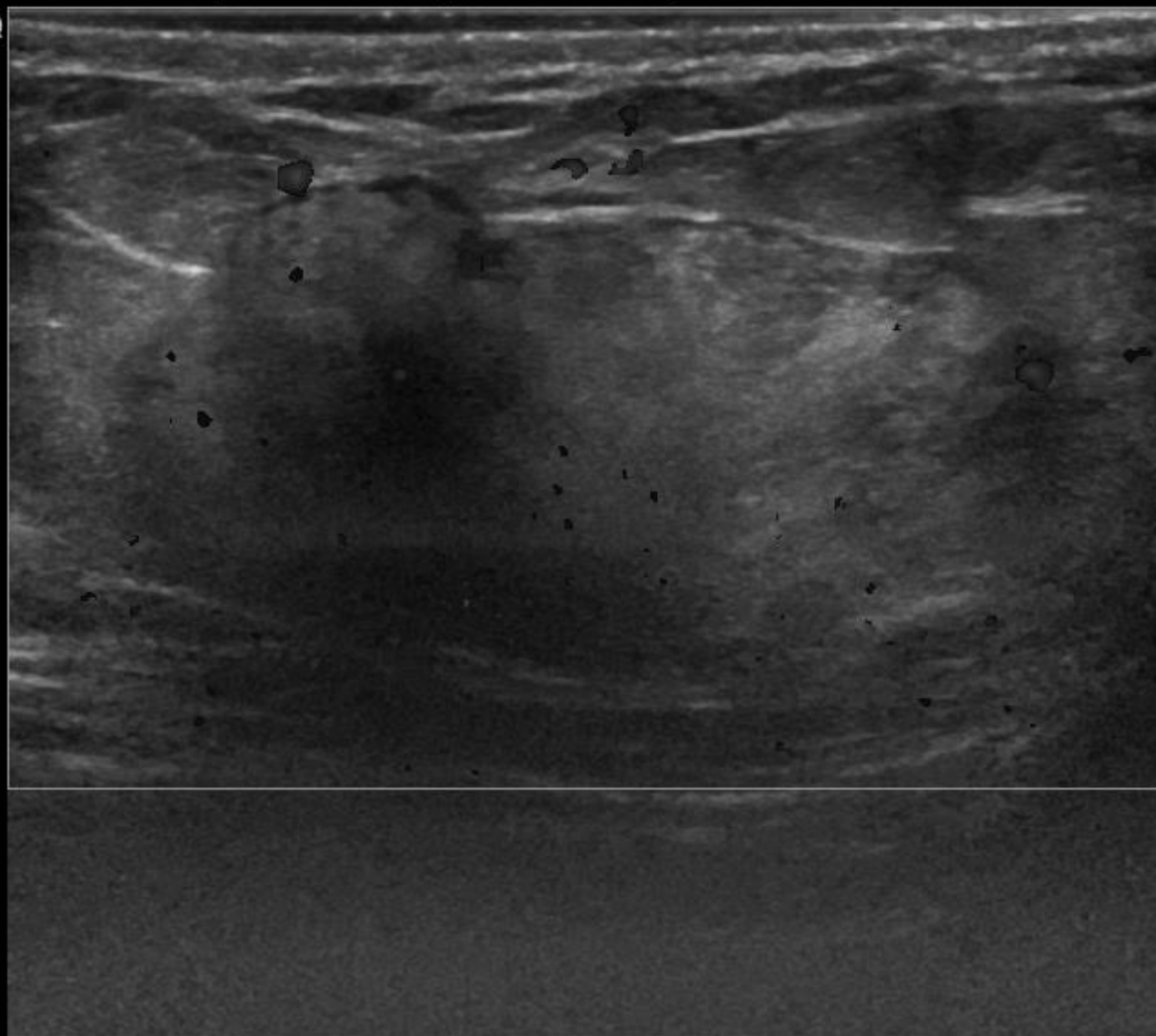
Answer:

Schwannoma (neurogenic tumor).

Q42 66 y/o Male, Inguinal palpable tumor, What is your Diagnosis?



LOGIQ
E9



1

2

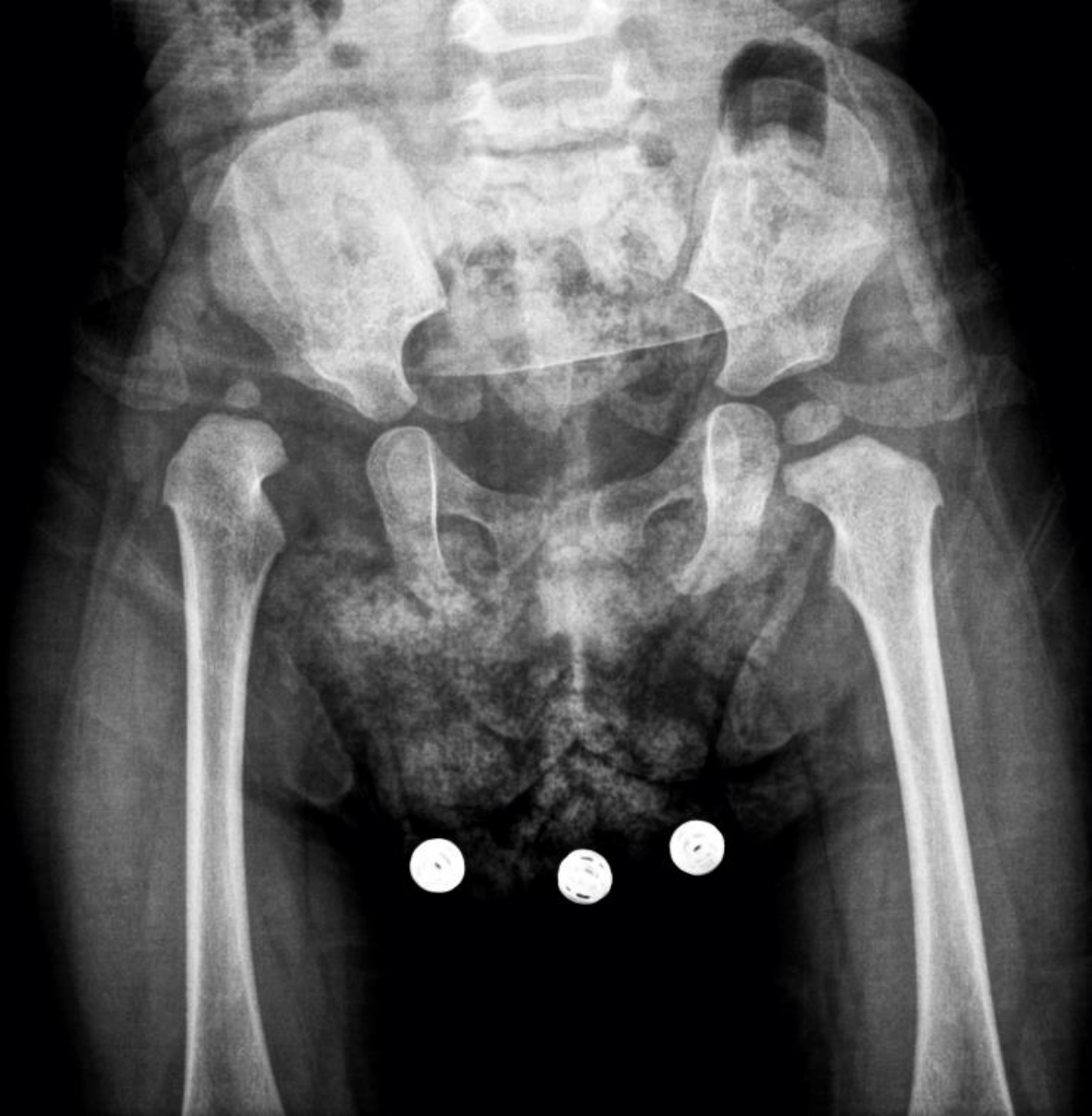3

4

4

Answer:
Angiofibroma.

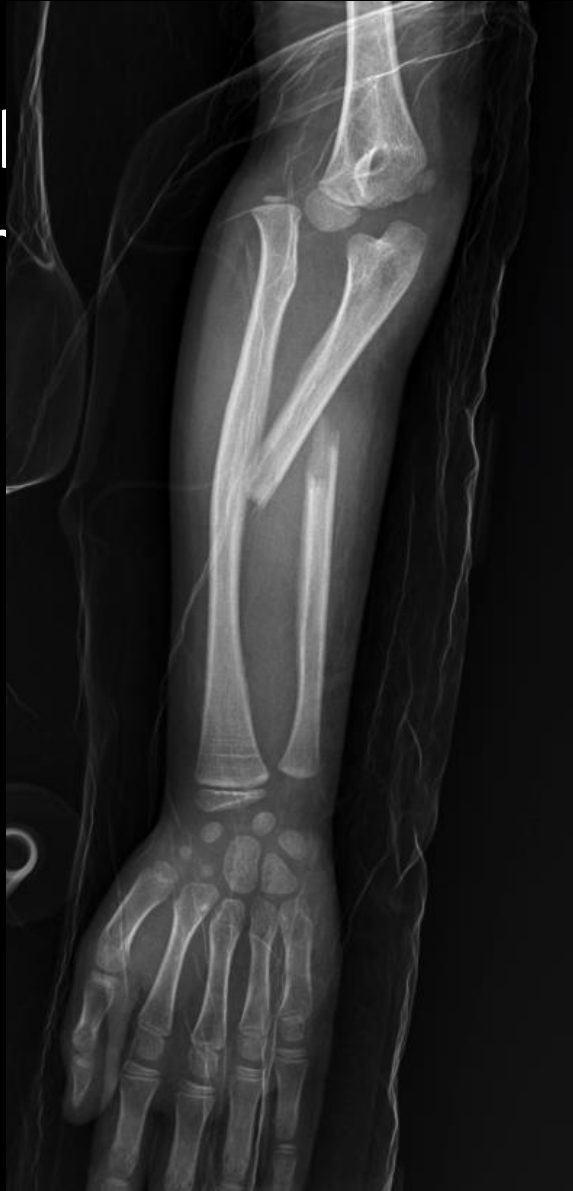Q43 2 y/o Female, cannot walk, What is your Diagnosis?



Answer:

Development dysplasia of right hip

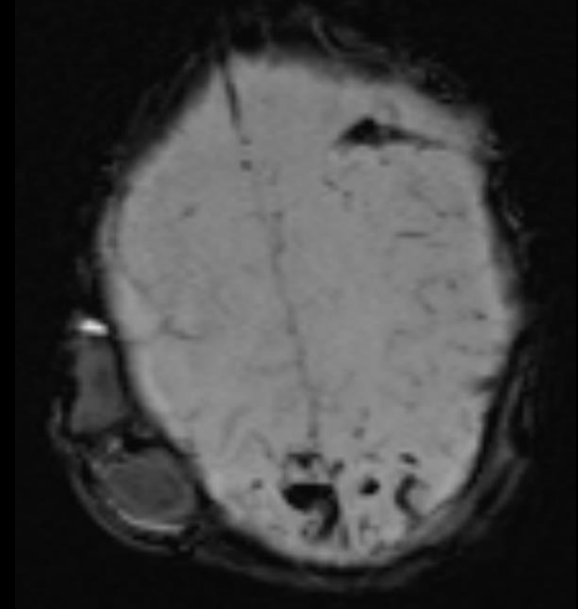
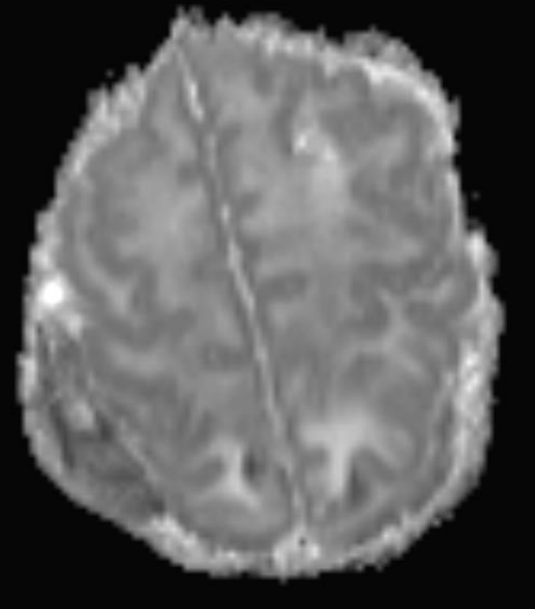
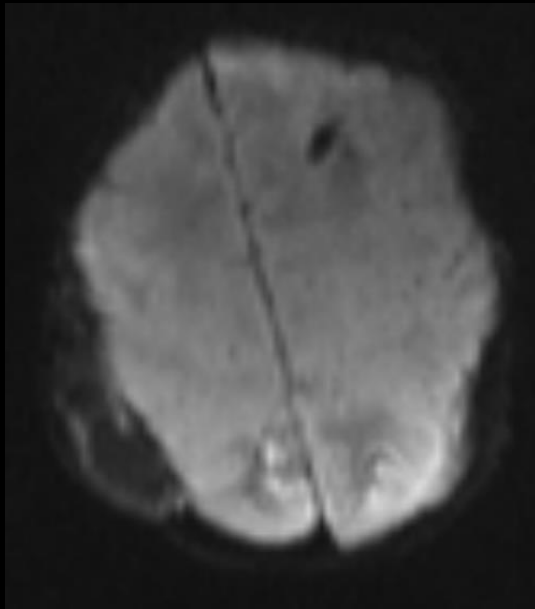
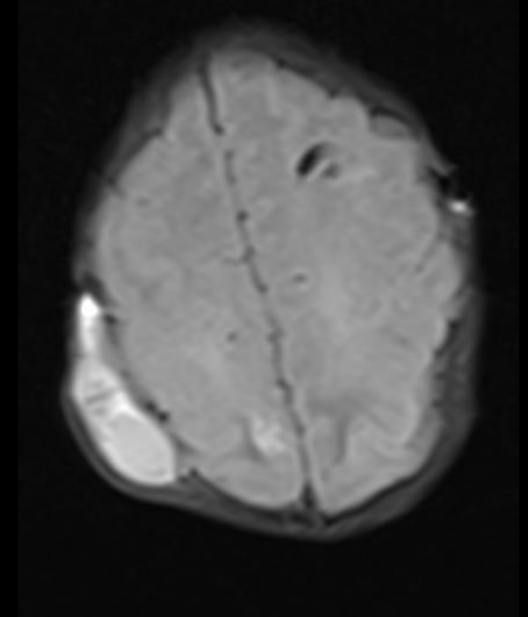
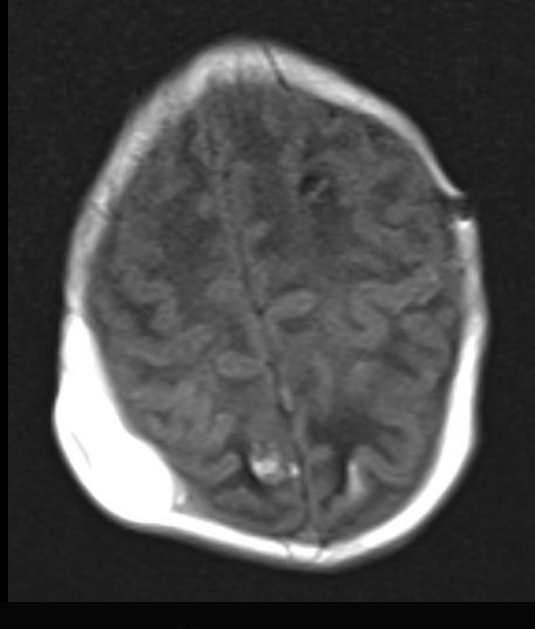
7 y/o Female
trauma, Wh



arm pain after
osis?

Answer:
Monteggia fracture

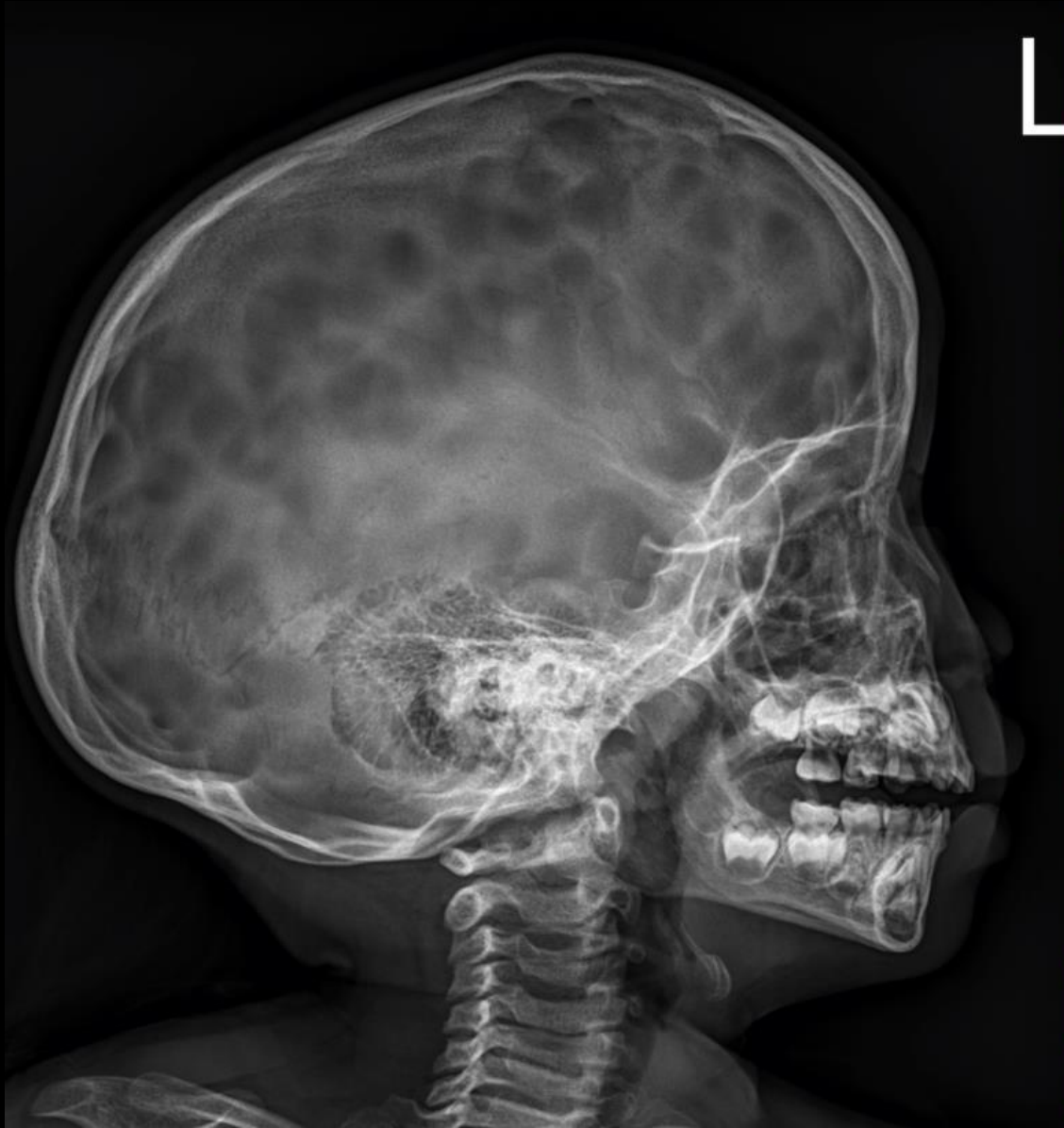Q45 Newborn with hypertension, What is your Diagnosis?

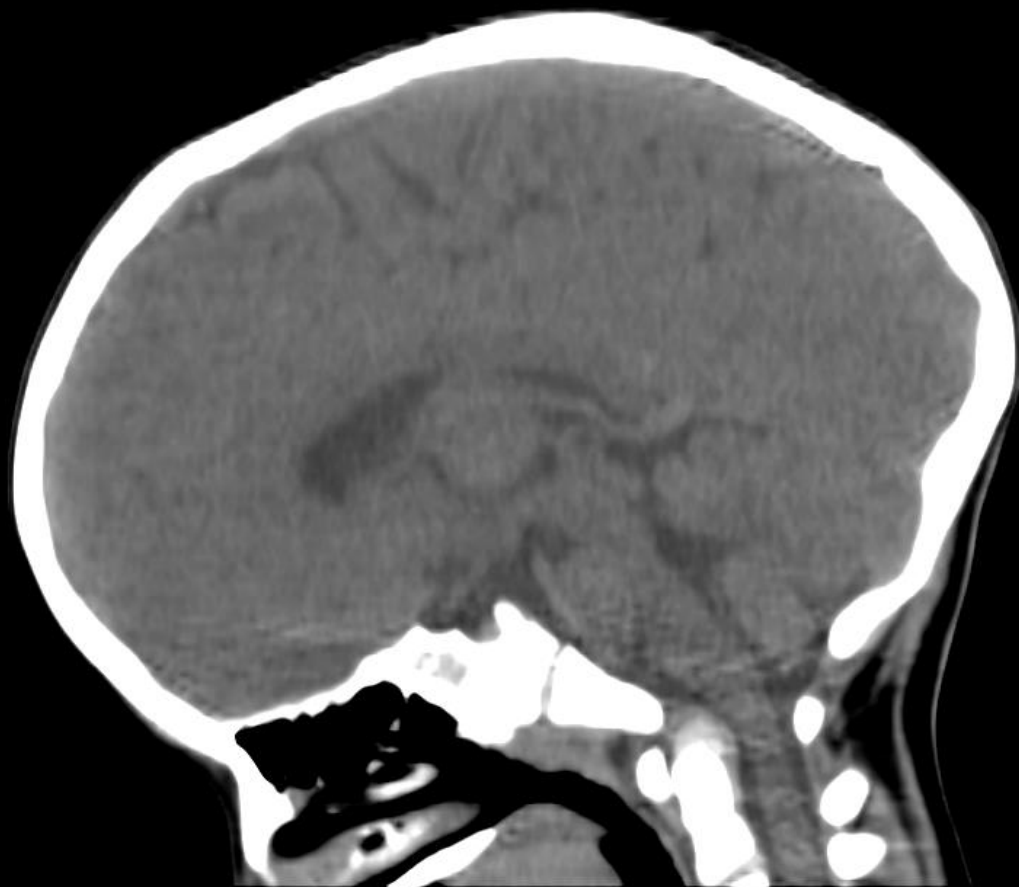
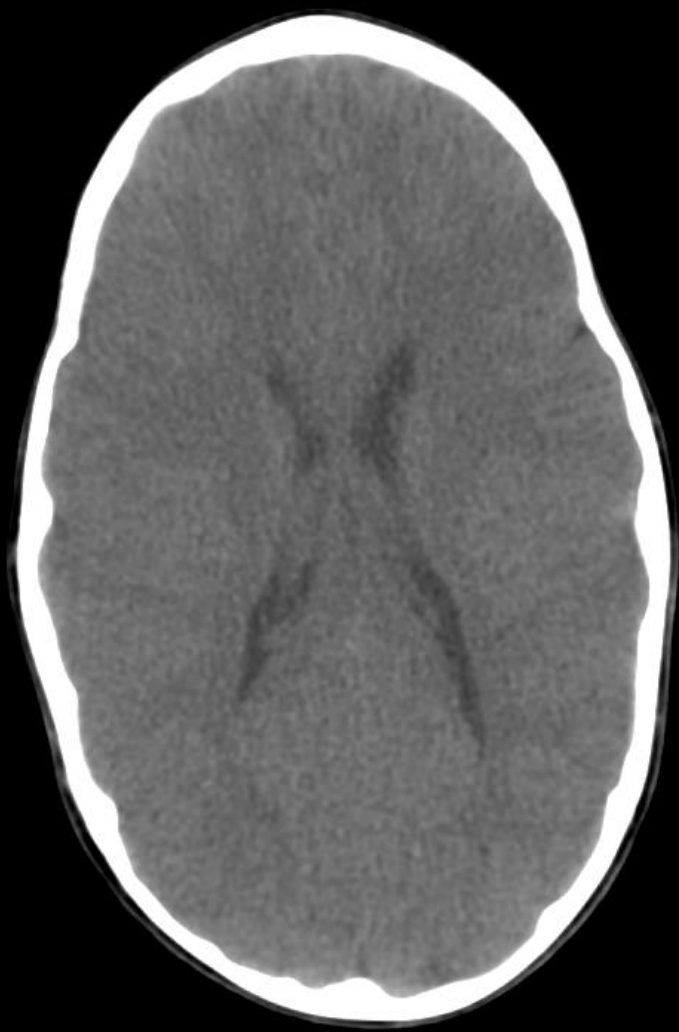
Answer:

1. Cephalohematoma
2. Posterior reversible encephalopathy with hemorrhage

Q46 3 y/o Female, with abnormal skull shape, What is your Diagnosis?

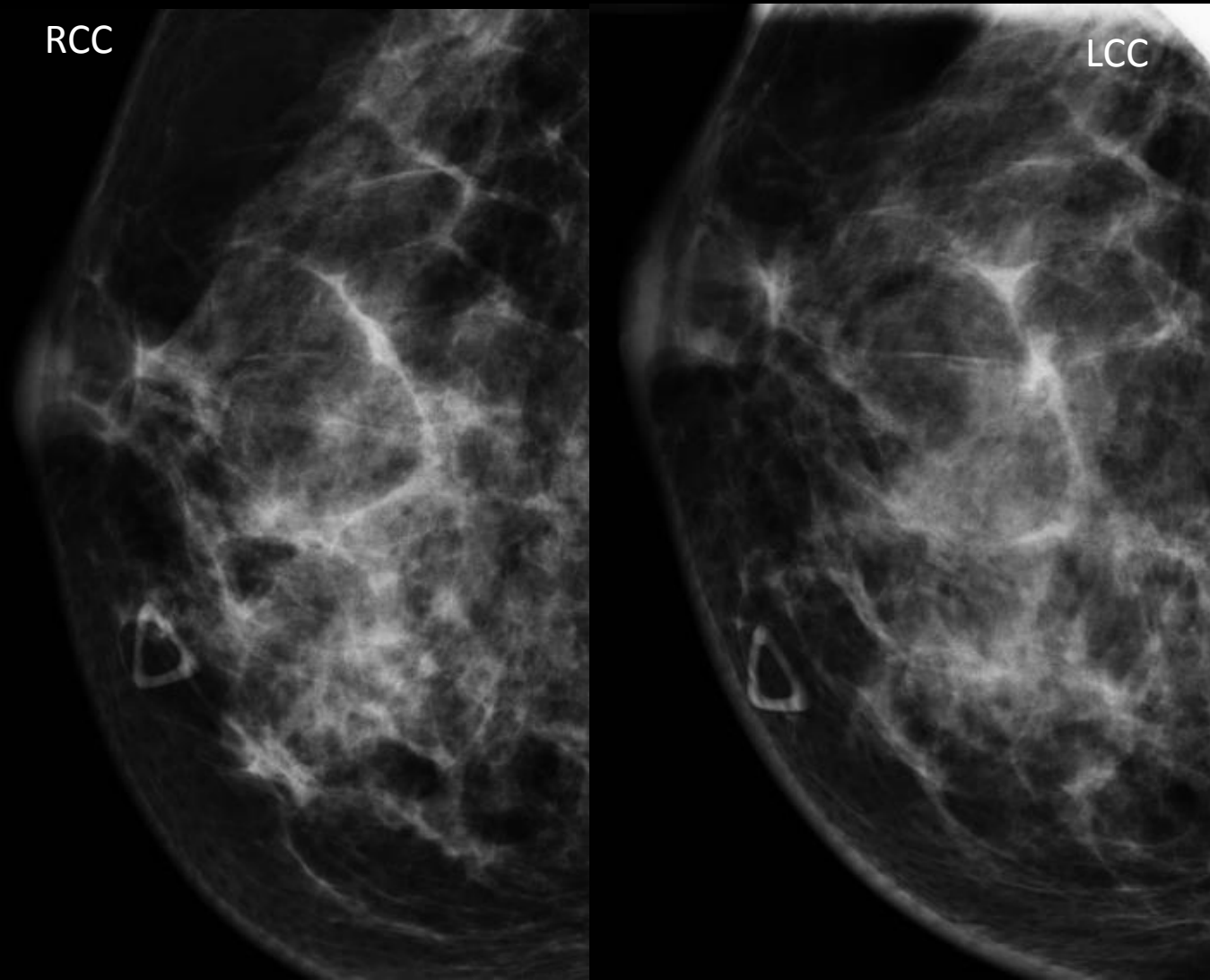


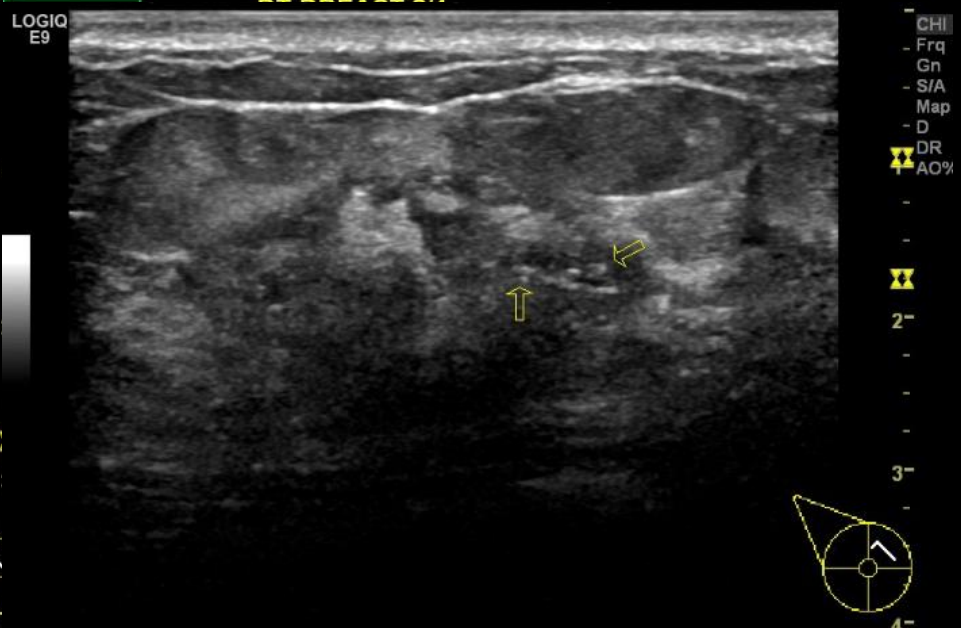
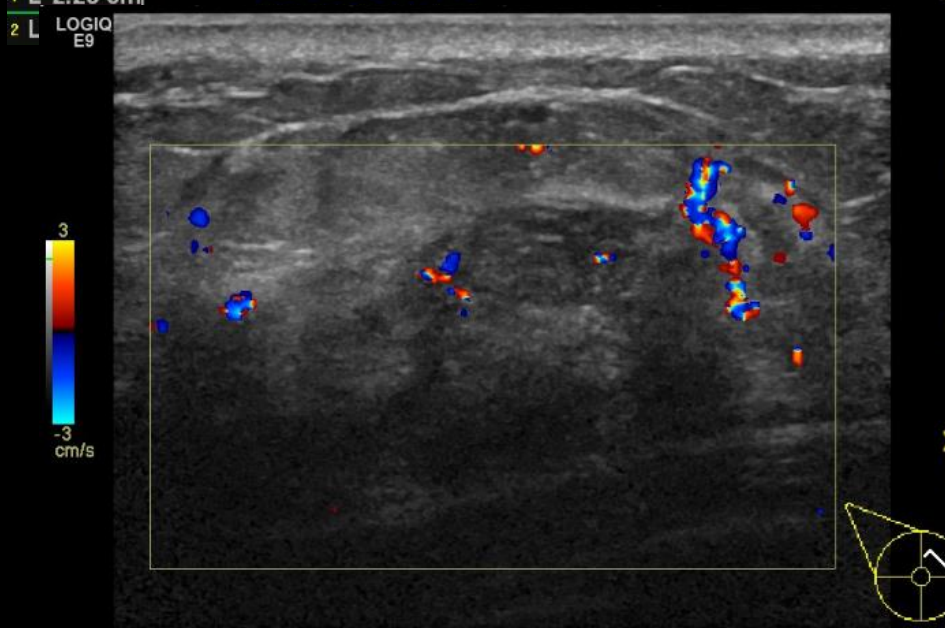
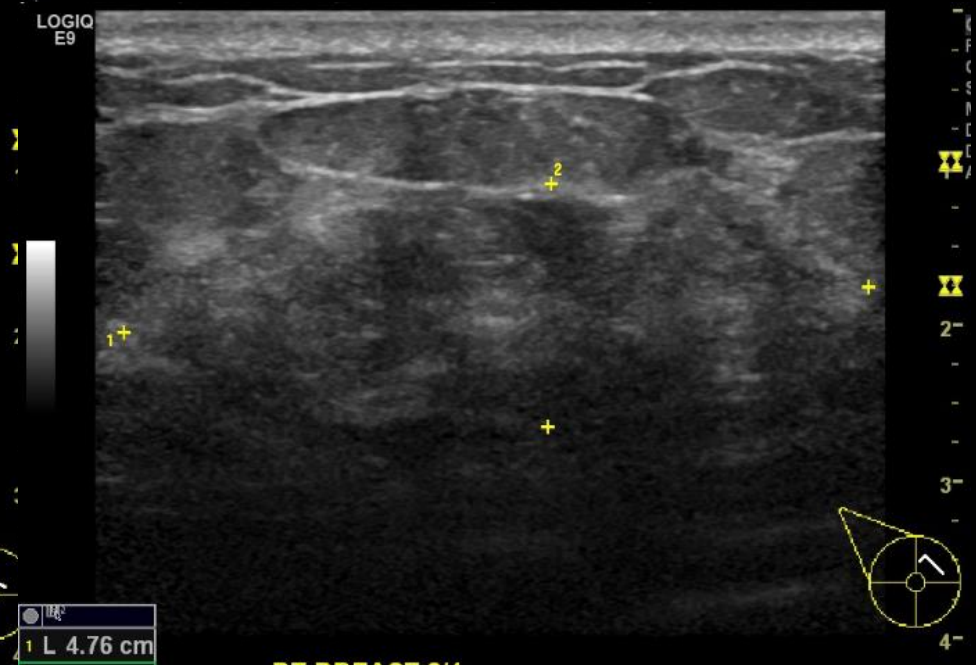
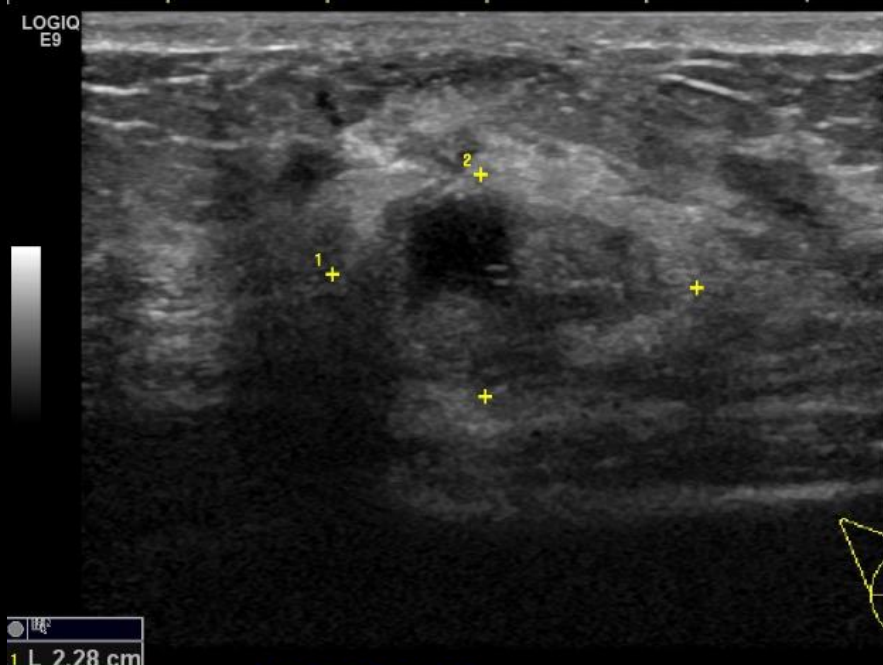

Answer:
scaphocephaly

Q47

41 y/o Female, Right palpable hard mass with nipple bloody discharge, What is your BIRADS Category?





RT BREAST 2/4

RT BREAST 2/4

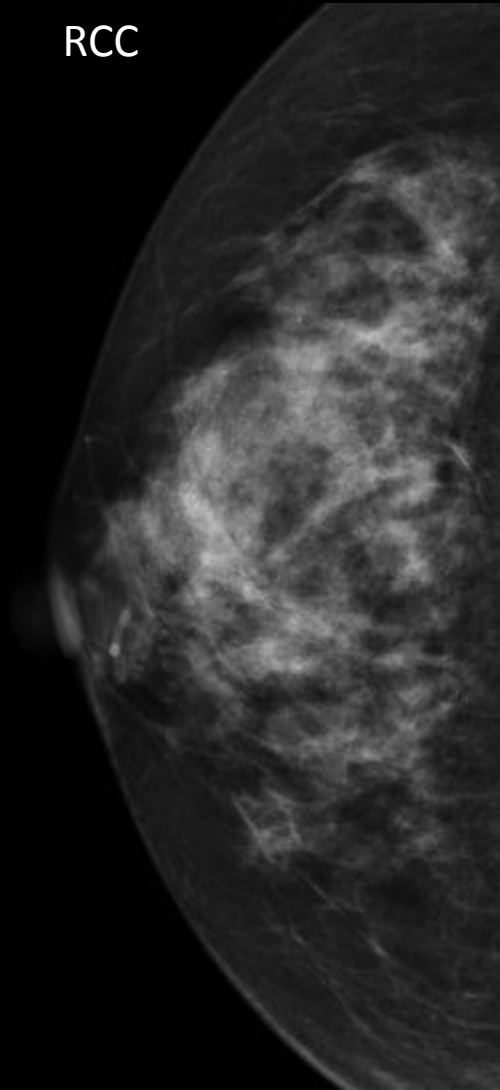
Ans:

1. BIRADS Category 4C / 5
2. Granulomatous inflammation, chronic and acute infiltration, in RLIQ

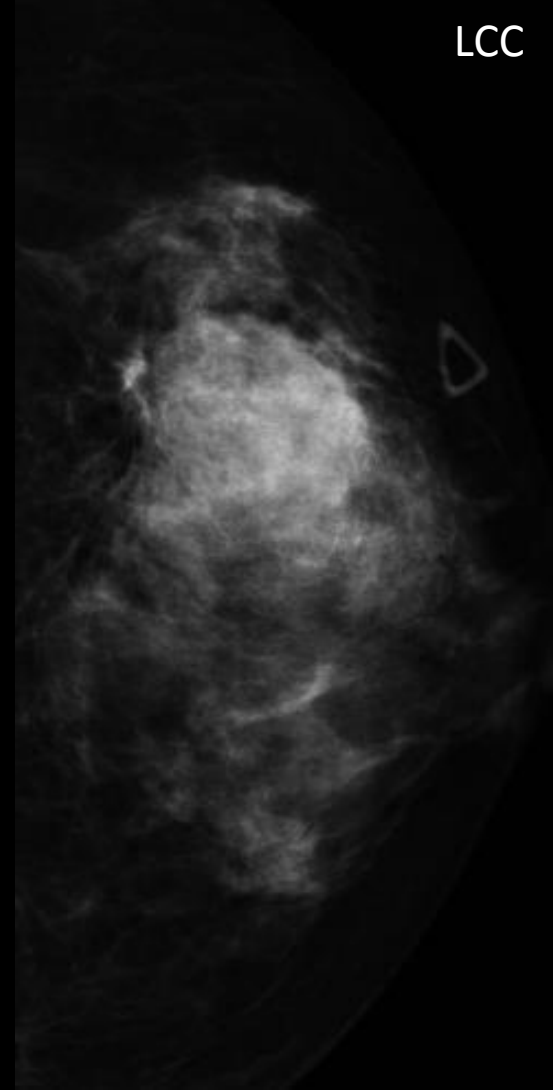
Q48

44 y/o female, Left breast mass for one year.
Left nipple serous discharge for 2 weeks, What
is your BIRADS Category?

RCC

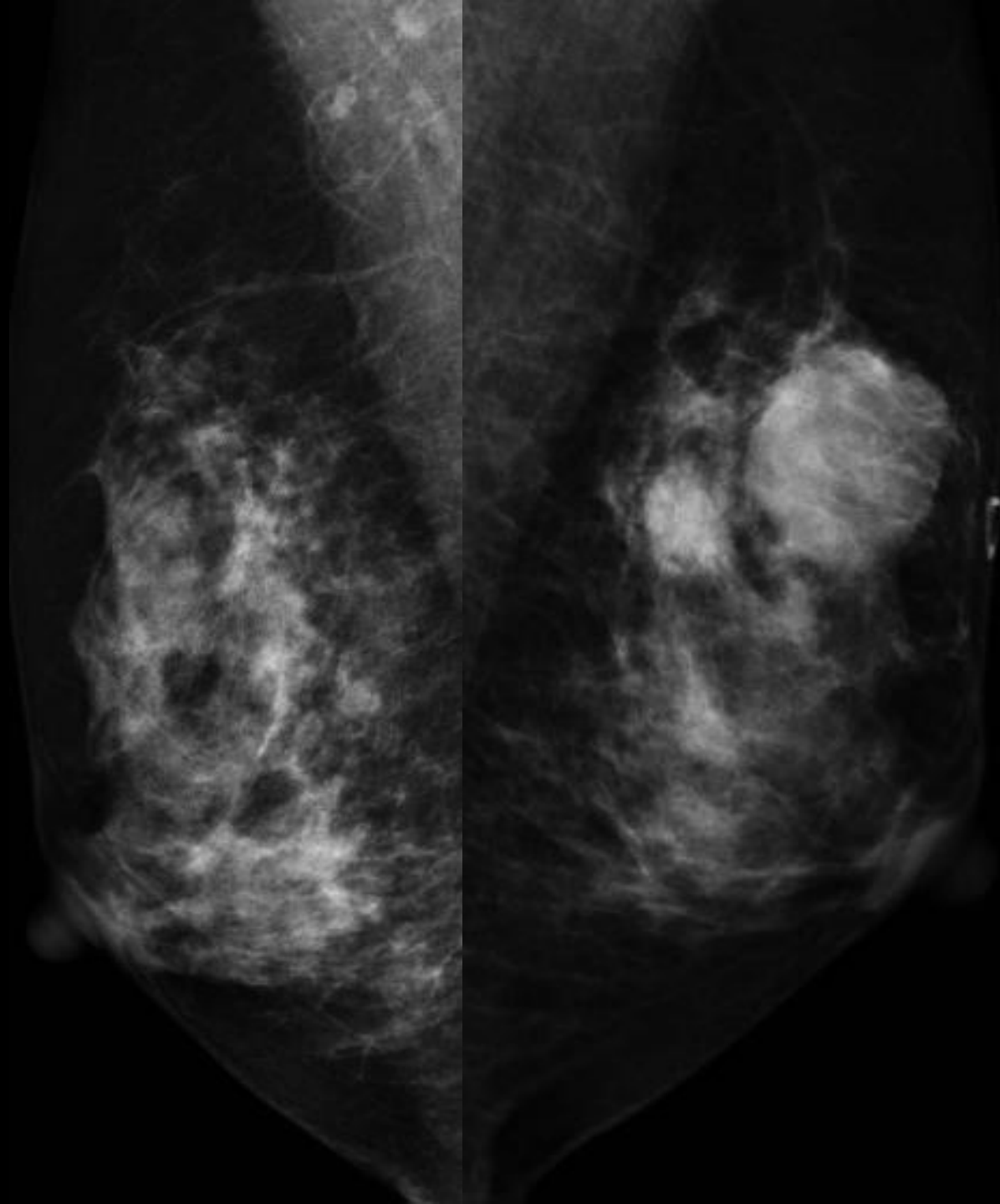


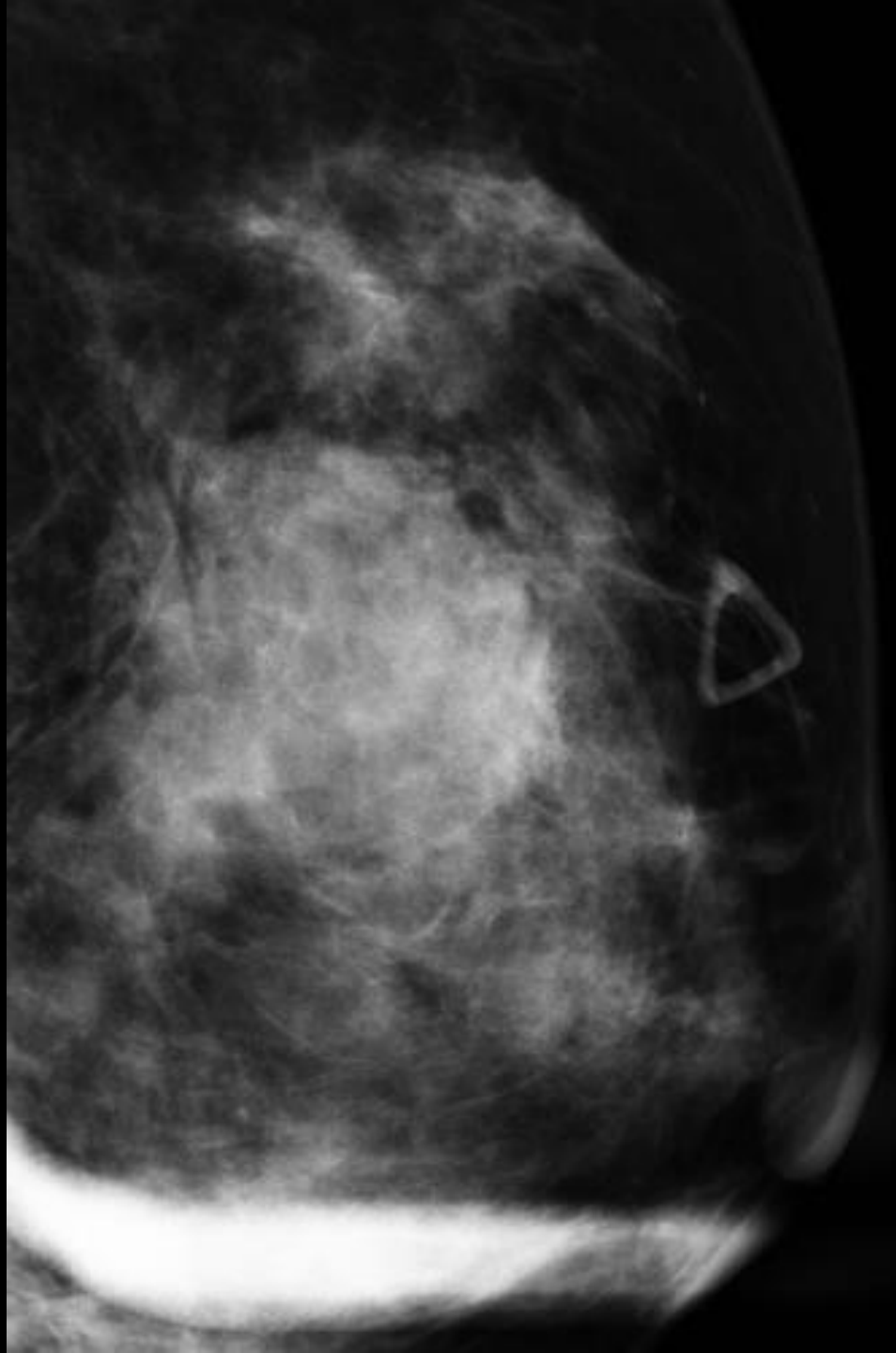
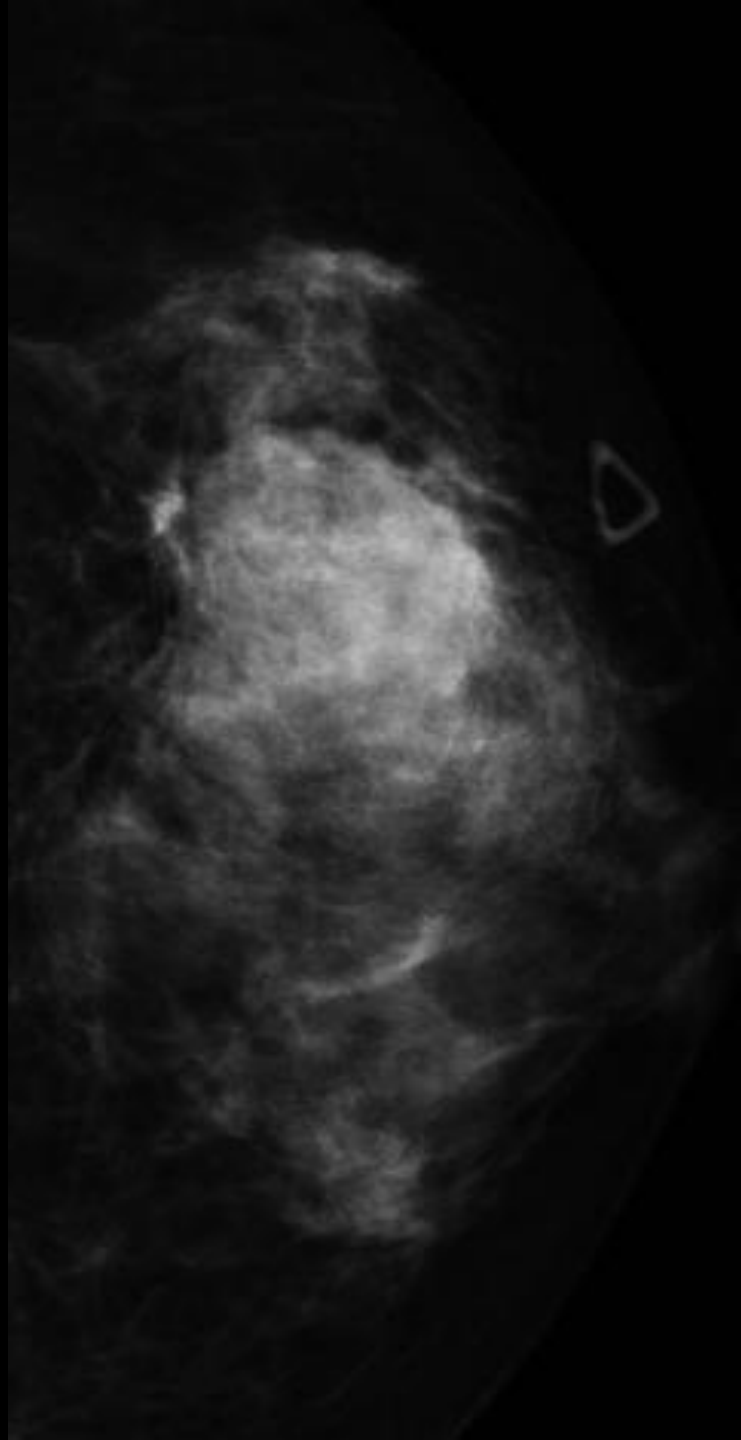
LCC



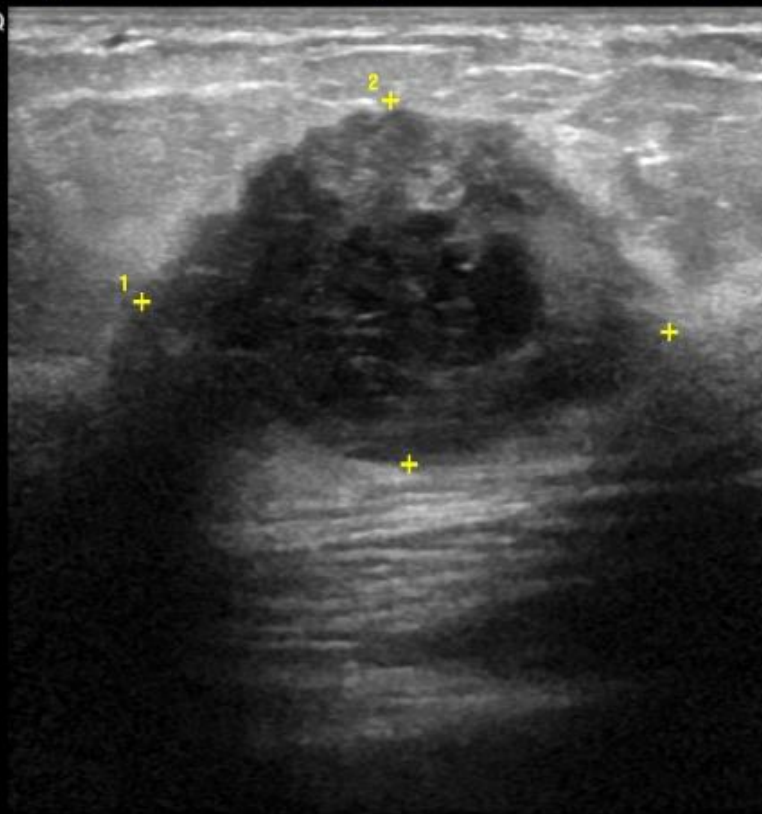
RMLO

LMLO





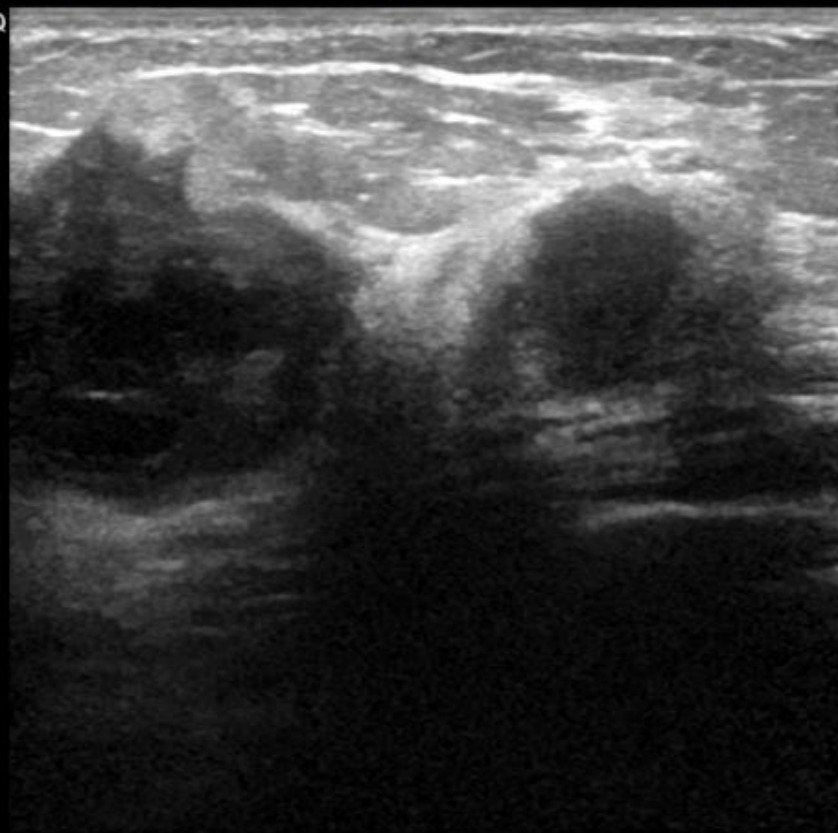
LOGIQ
E9



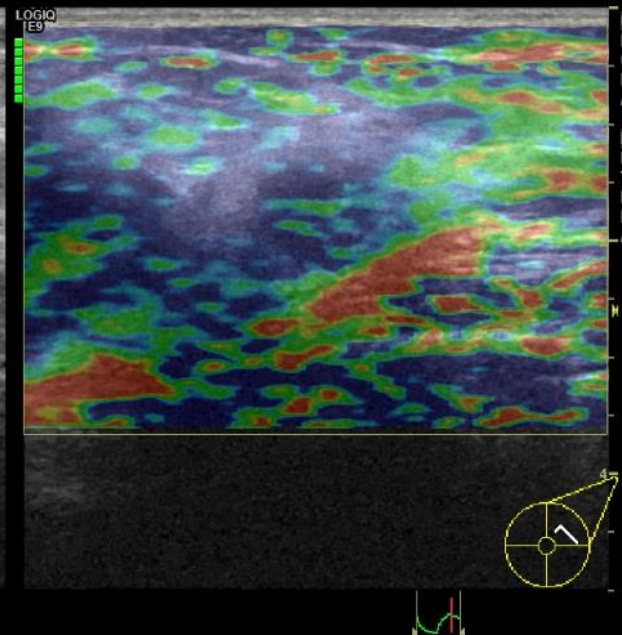
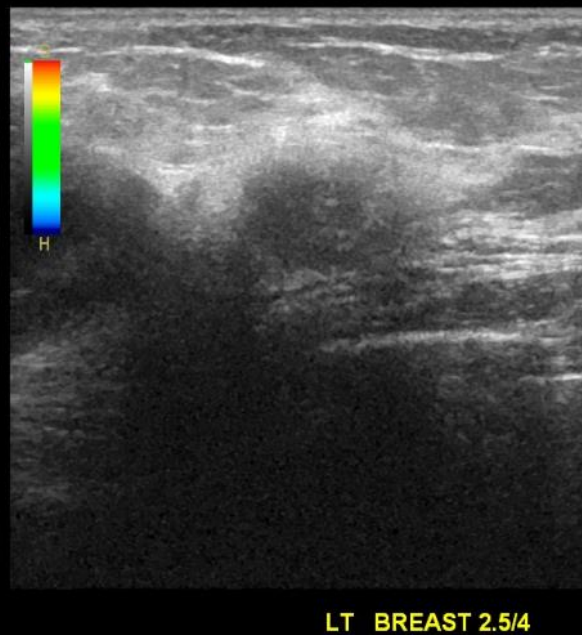
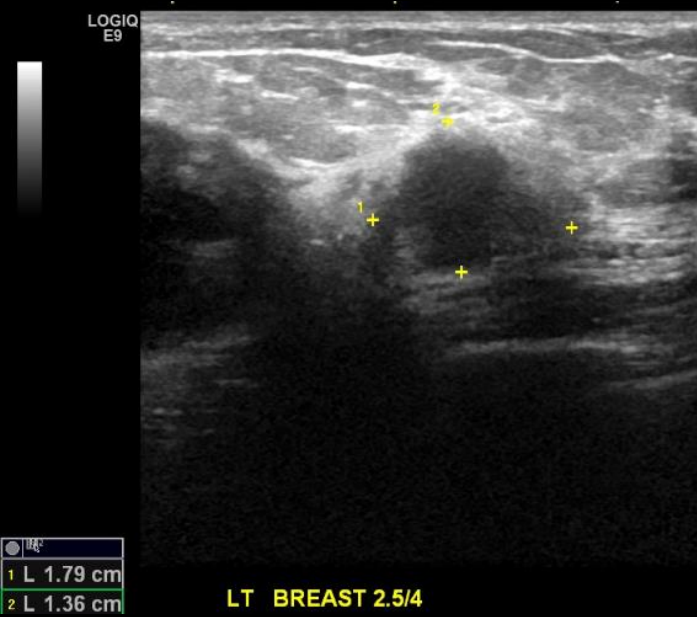
LT BREAST 1/4 AR

1 L 3.25 cm
2 L 2.24 cm

LOGIQ
E9



LT BREAST 2.5/4

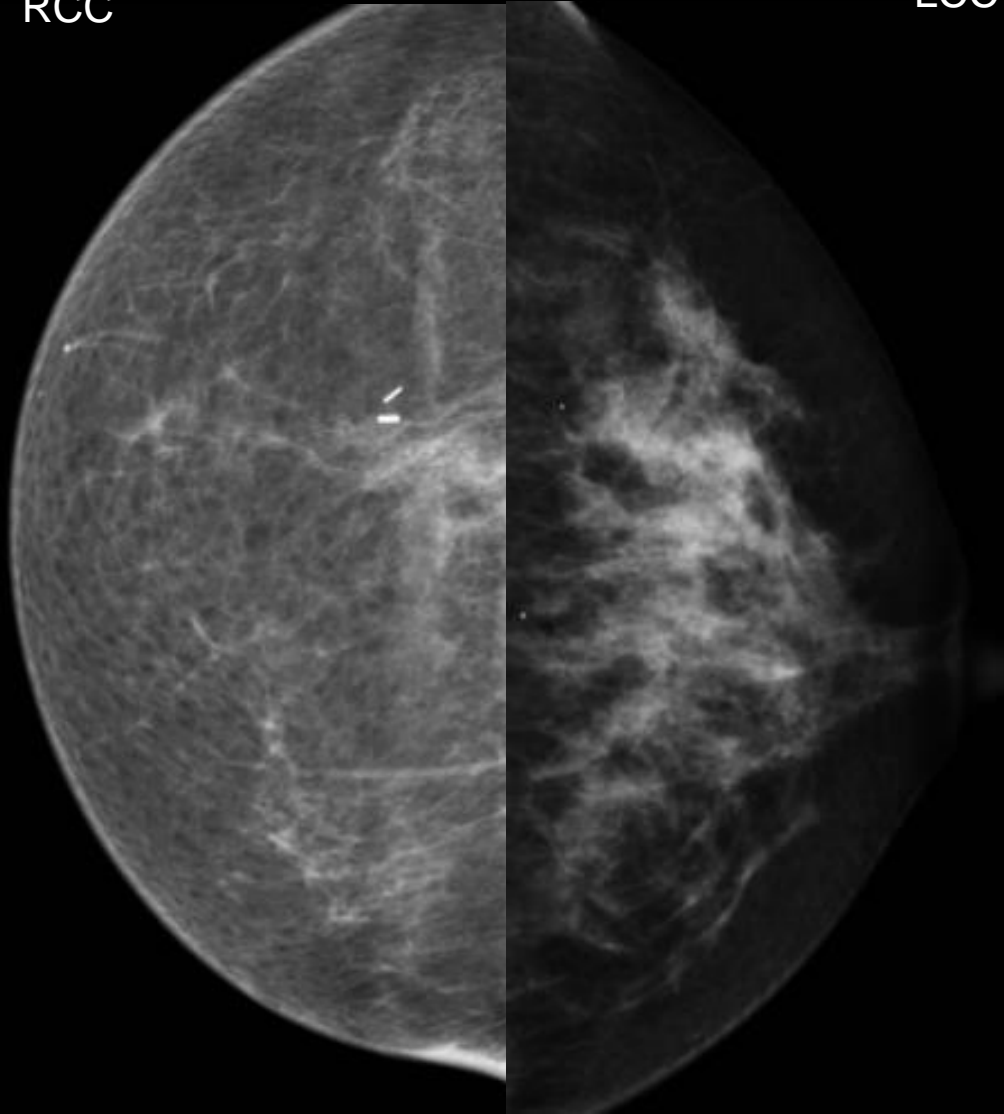


- Ans:
 1. BIRADS Category 5
 2. Breast cancer in LUOQ, (invasive ductal carcinoma)

Q49 44 y/o female, Post operation of right breast,
What is your BIRADS Category?

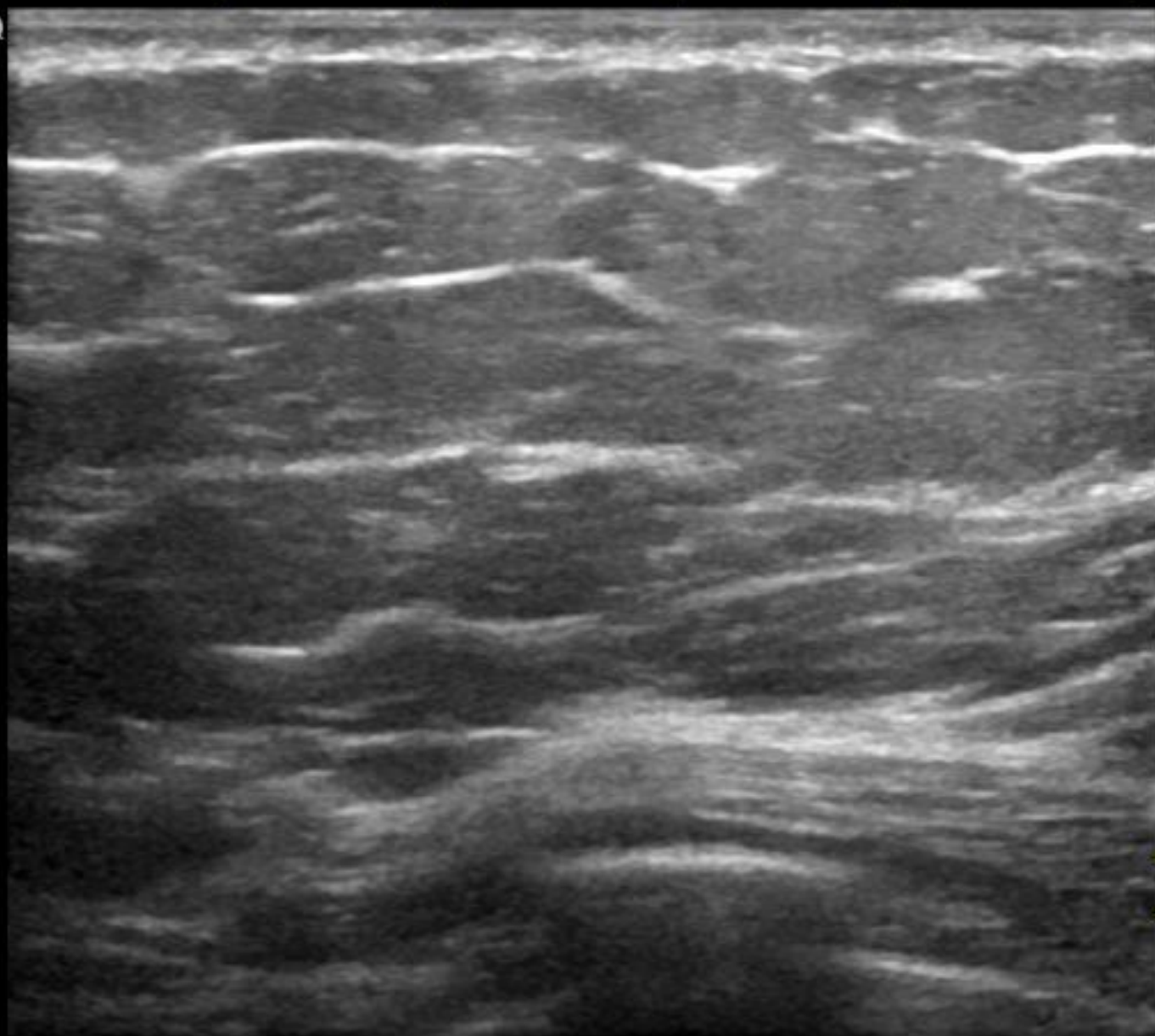
RCC

LCC



RMLO

LMLO



1-

2-

3-

4-

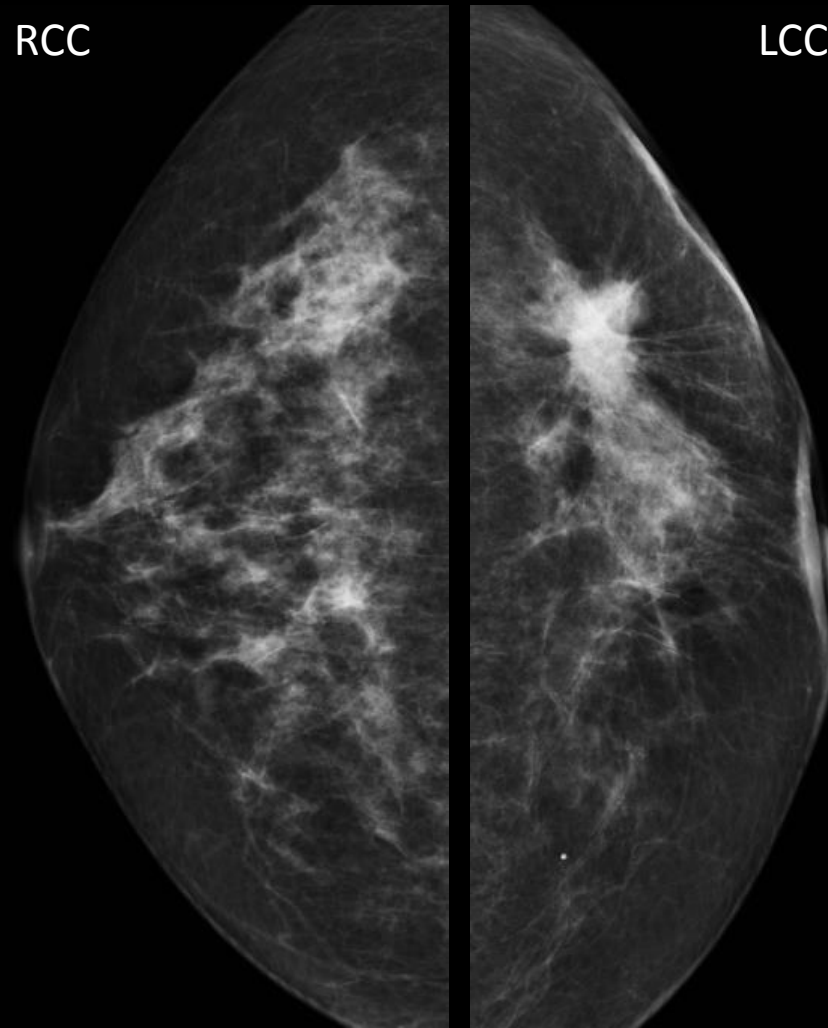
RT BREAST 8

Ans:

1. BIRADS Category 2
2. S/P reconstructive right breast surgery ,
(TRAM) flap surgery

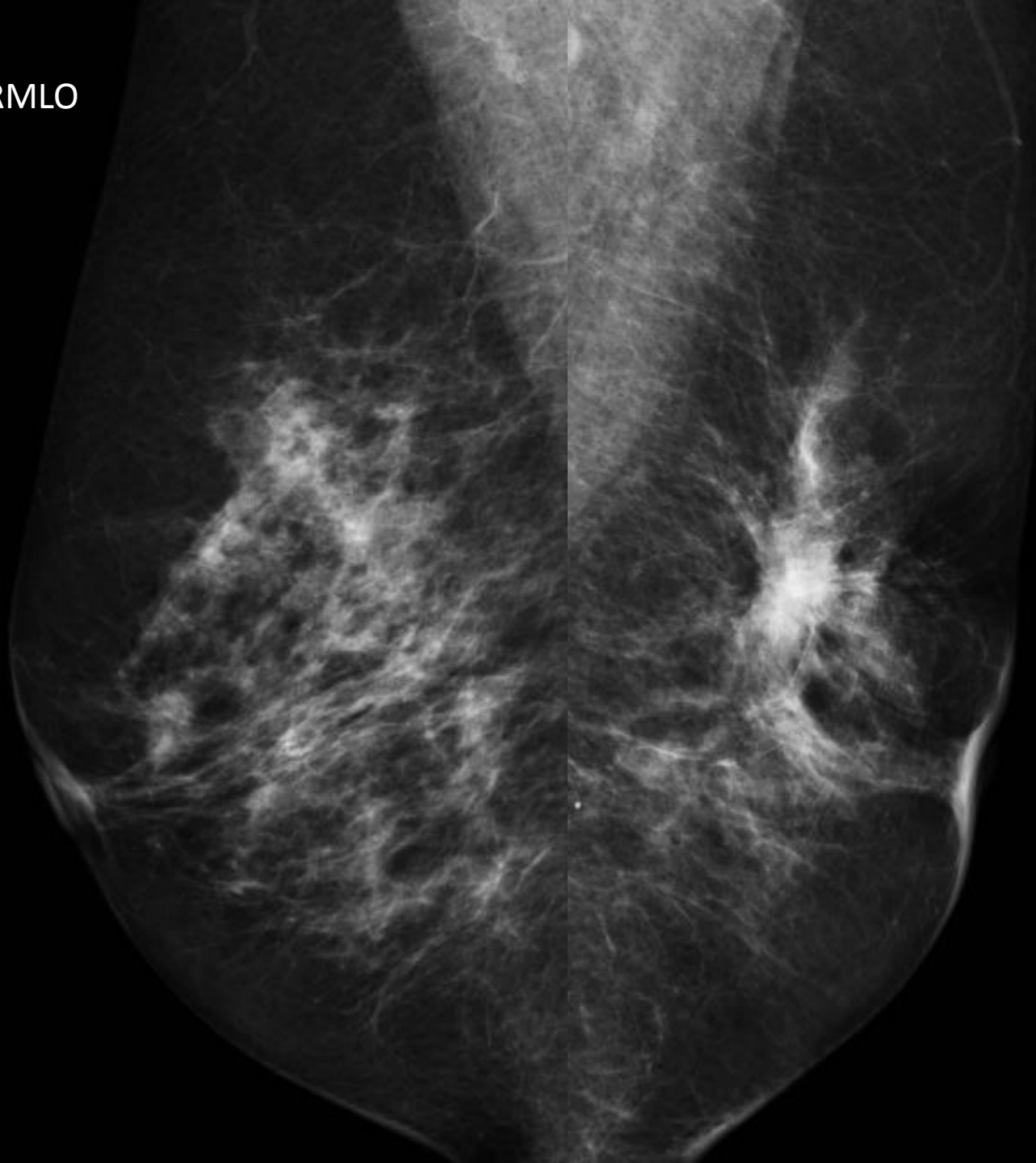
Q50

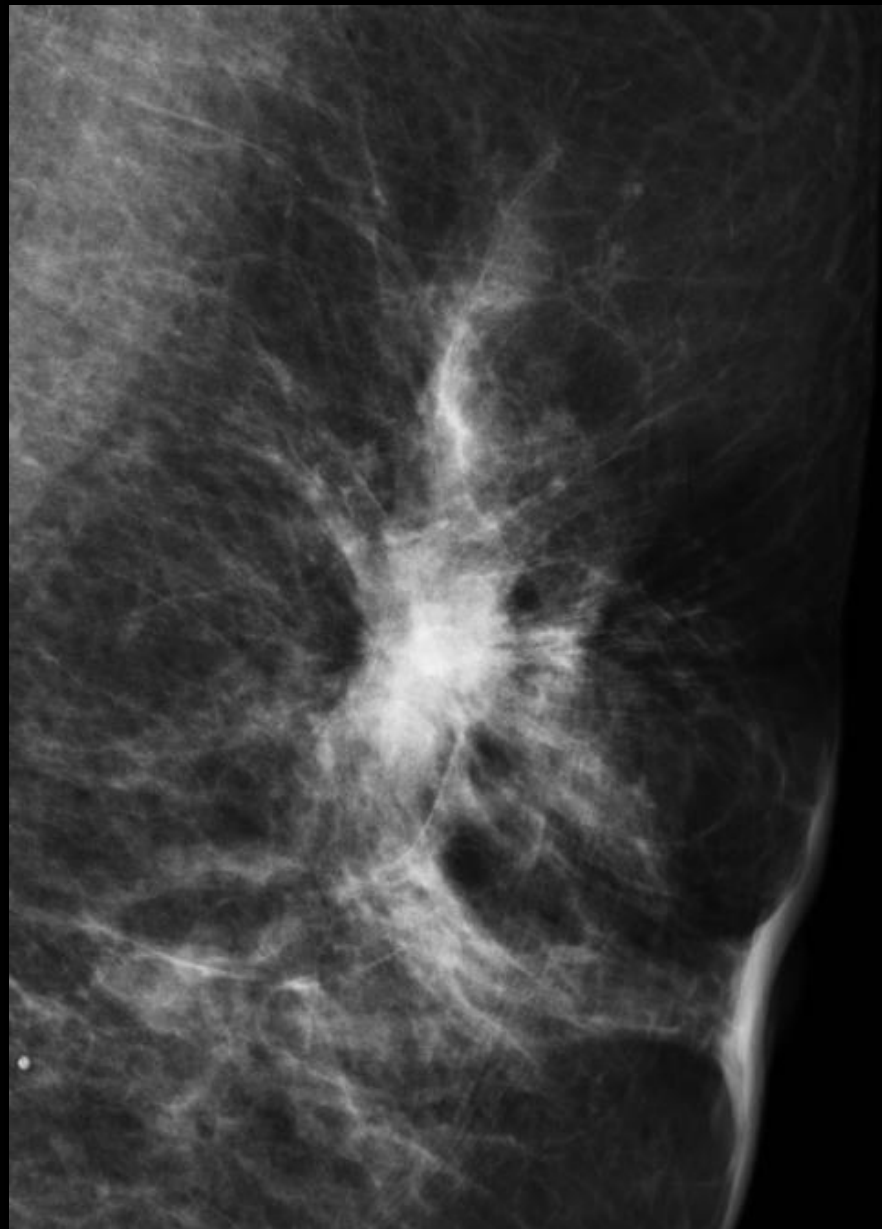
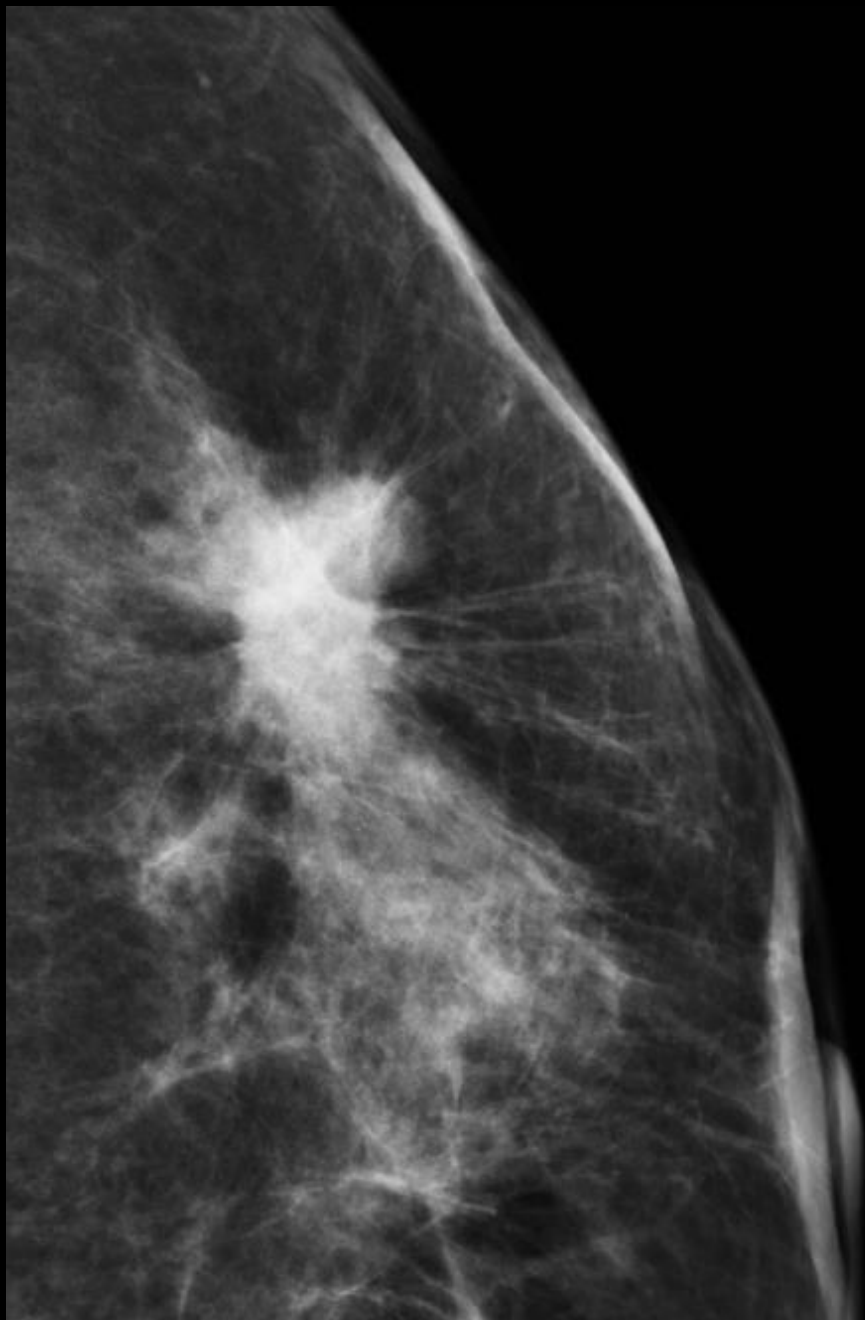
65 y/o female, Post operation with old incisional scar in LUOQ, What is your BIRADS Category?

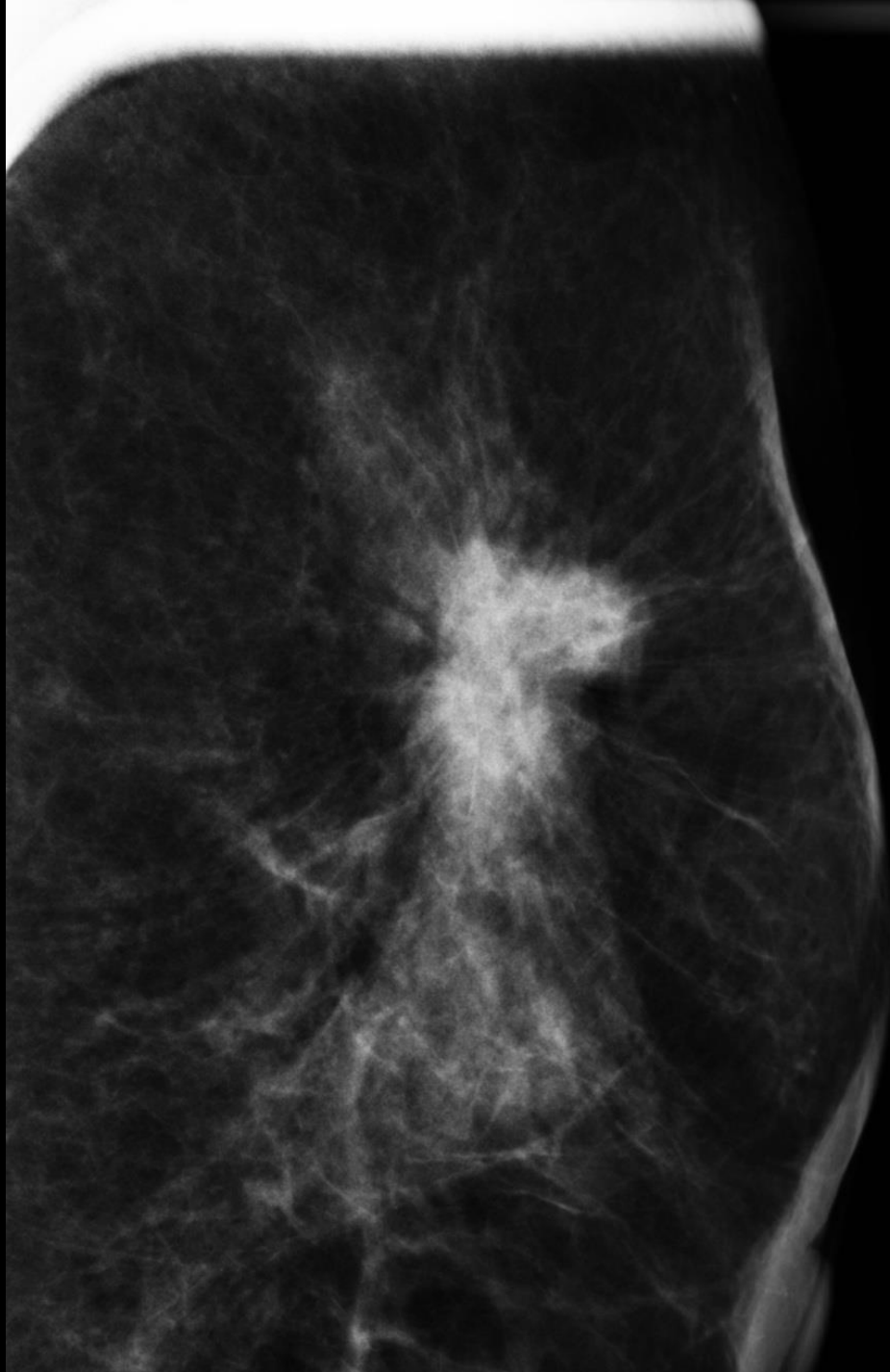

RMLO

LMLO







Answer:

1. BIRADS Category 5
2. Breast cancer in LUOQ (Invasive breast carcinoma)