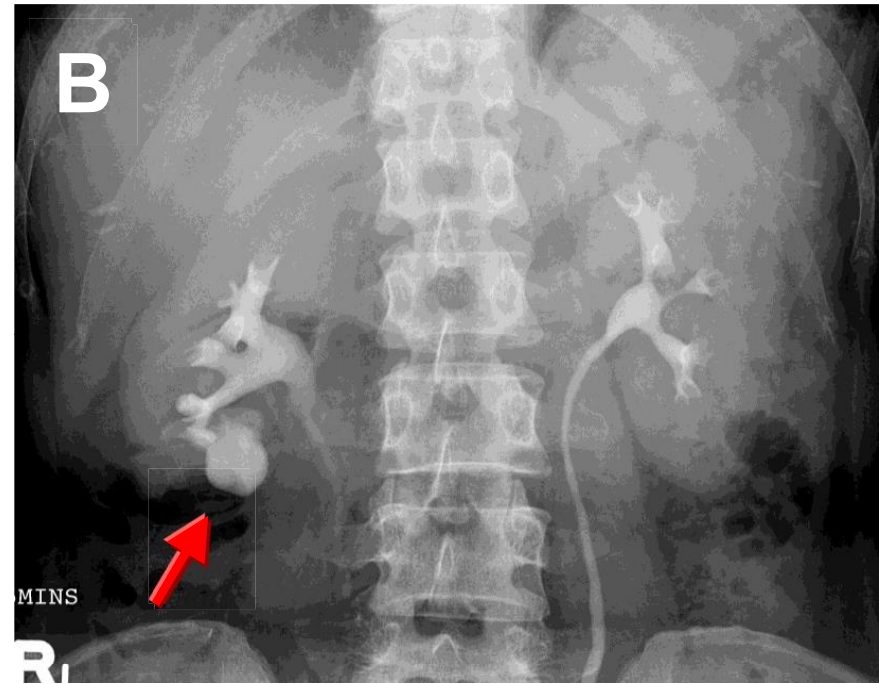
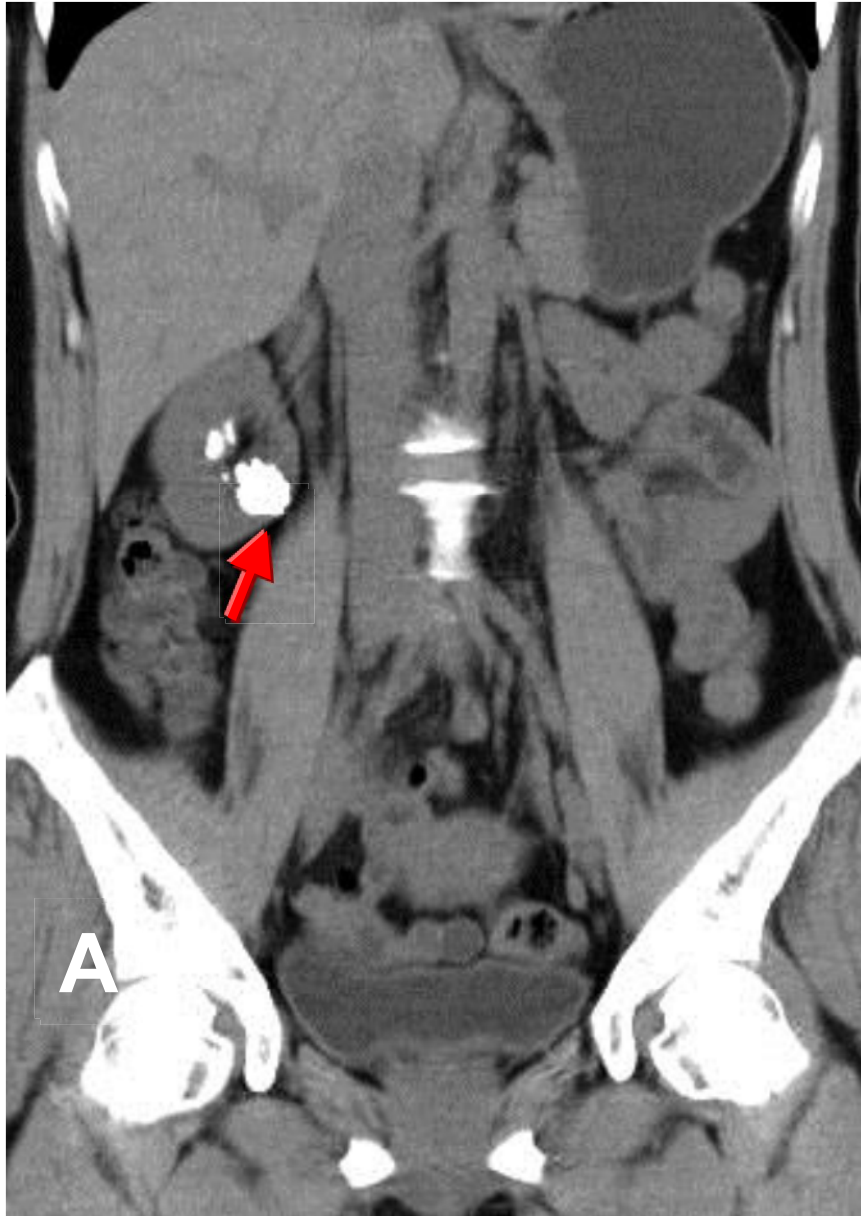


calyceal diverticular stones



The calyceal diverticular stones (arrow on A,B) in the right kidney can be mistaken for gallstones on plain film. There are two types of calyceal diverticula, type I communicate with a minor calyx with over 50% occurring in the upper one-third of the kidney, type II communicate with a major calyx or the renal pelvis itself, are much less common.