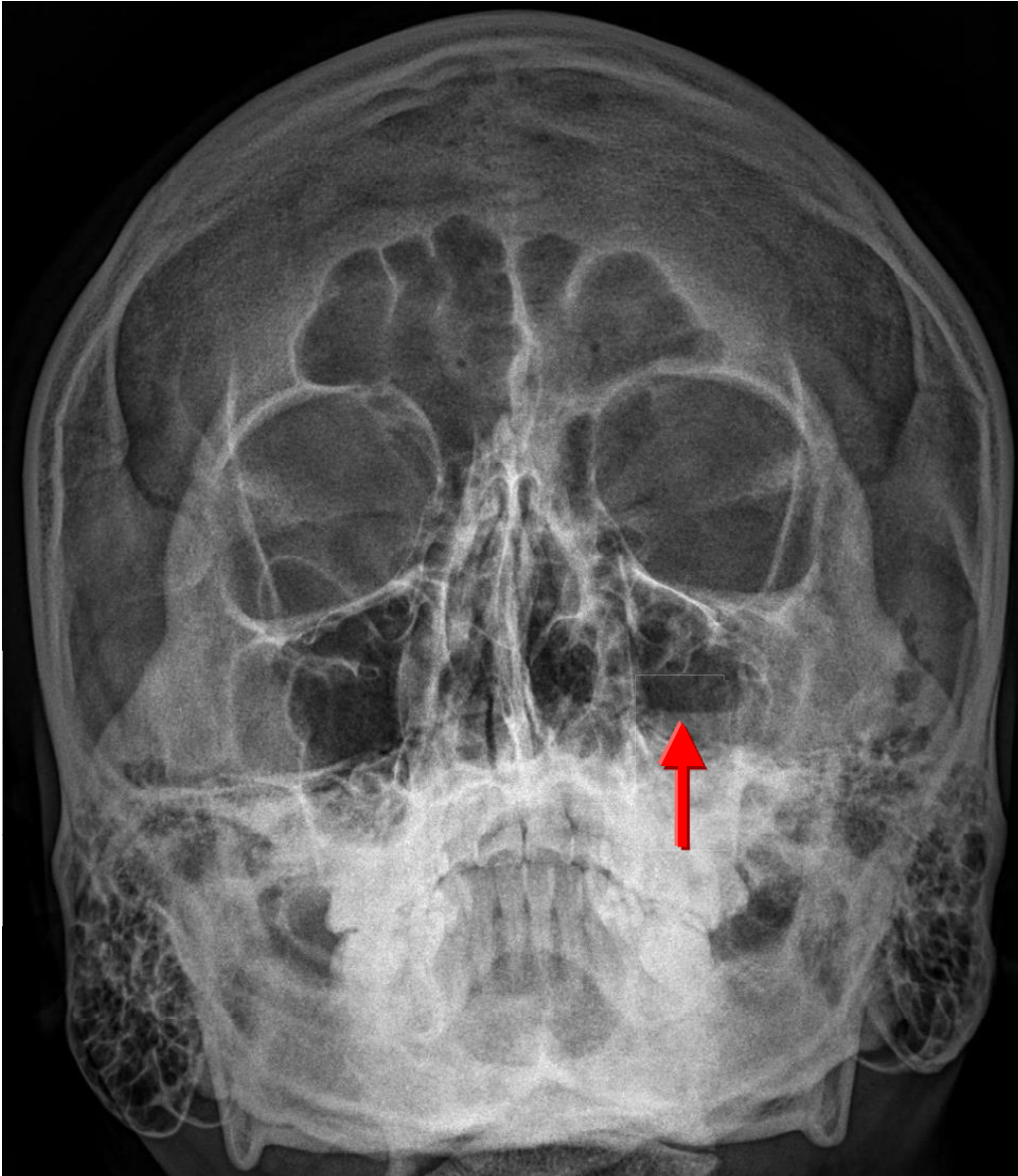


Ans: Paranasal sinusitis



Clinical:

Secondary to URI,
allergic rhinitis

Organism:

Staphylococcus,
Streptococcus,
Pneumococcus

X-ray findings:

Air-fluid level within
paranasal sinuses

Complication:

Epidural abscess,
subdural empyema,
cavernous sinus thrombosis,
meningitis, brain abscess