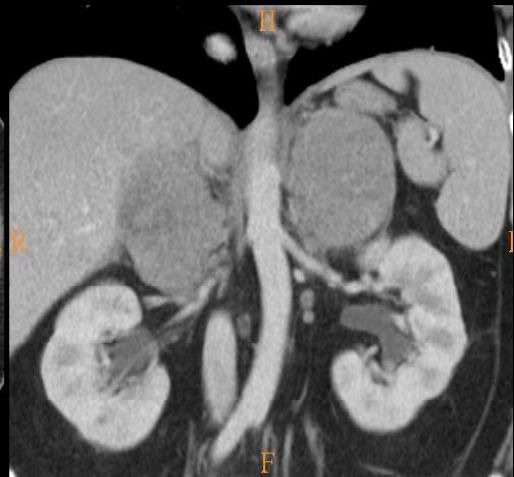
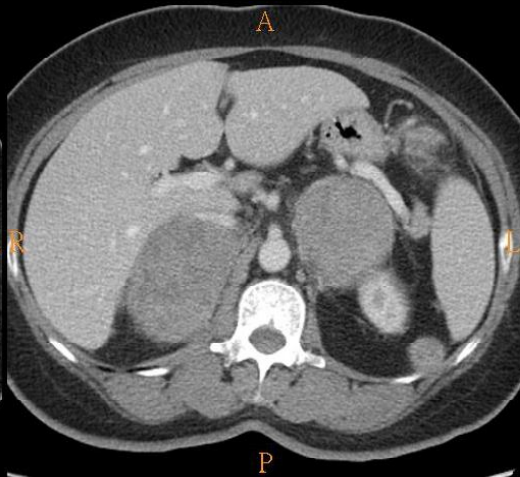
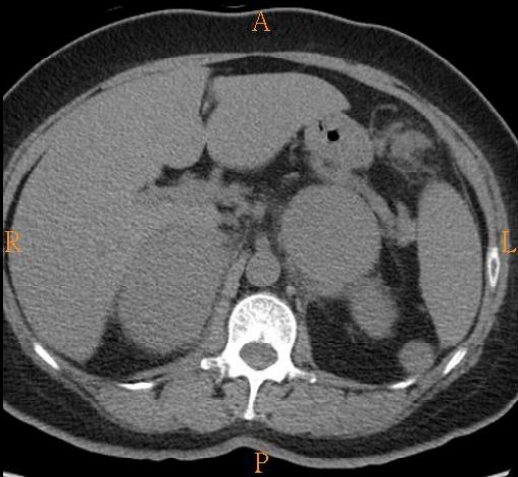


- 
- 57 year-old female
  - History:
    - Intermittent abdominal pain, mild fever and general malaise for months
  - Past history:
    - Diabetes mellitus
    - Hypertension



Primary (extremely rare)

- Less than 1% of non-Hodgkin's lymphoma
- 3% of extranodal lymphoma

Secondary

- 25% of non-Hodgkin lymphoma

- Large, soft tissue mass, tumor infiltration
  - Unilateral or bilateral
  - Preservation of the native triangular appearance of the normal adrenal gland
  - May manifest necrotic, cystic, heterogeneous and enhancing components → difficultly differentiate
- 
- Without nodal involvement
  - No evidence of disease elsewhere after diagnosis