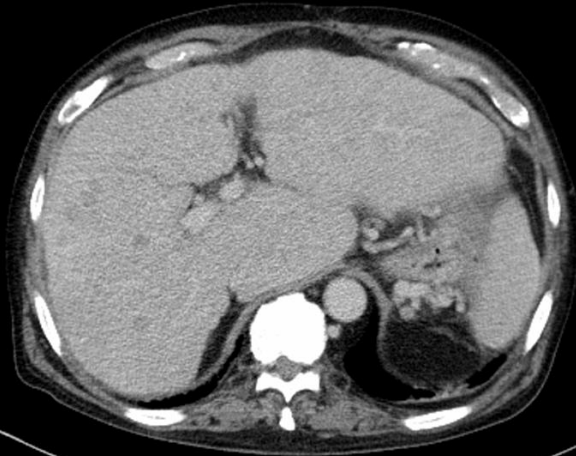
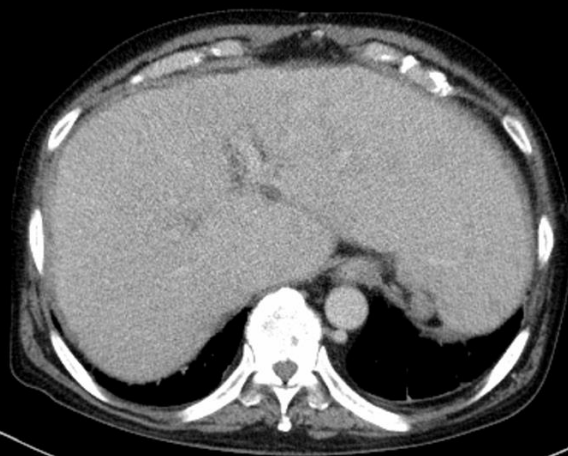
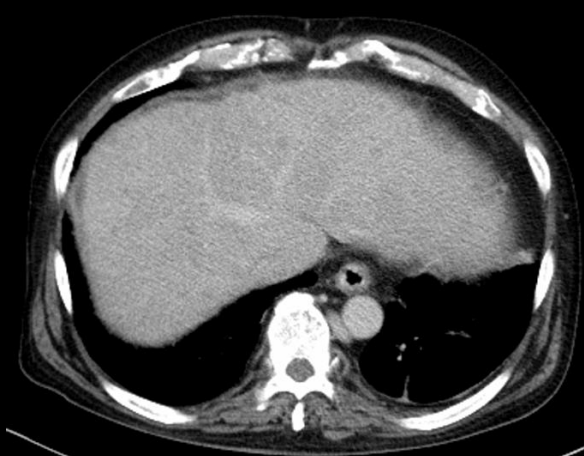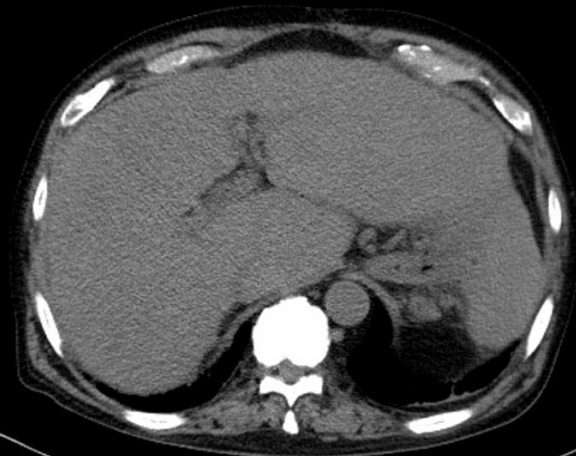
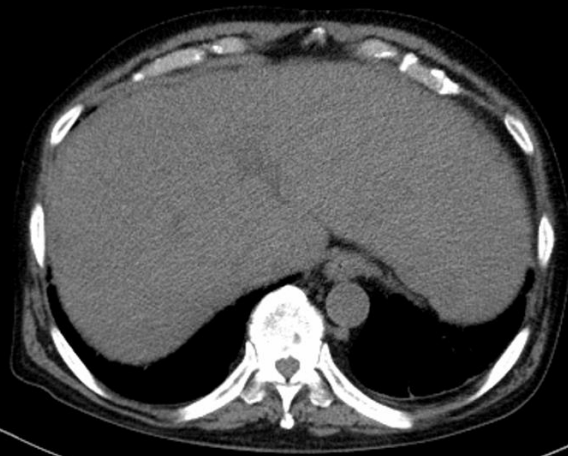
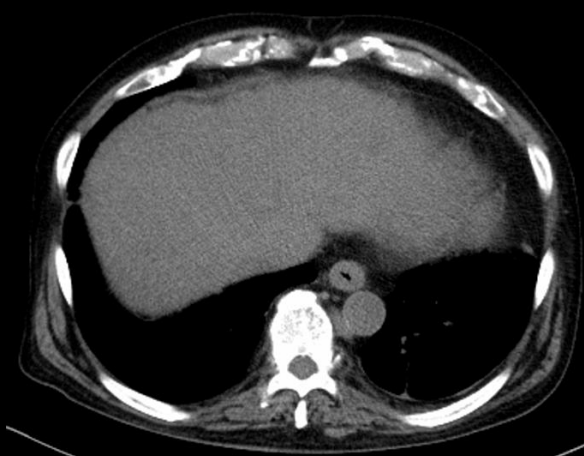


# CASE 5

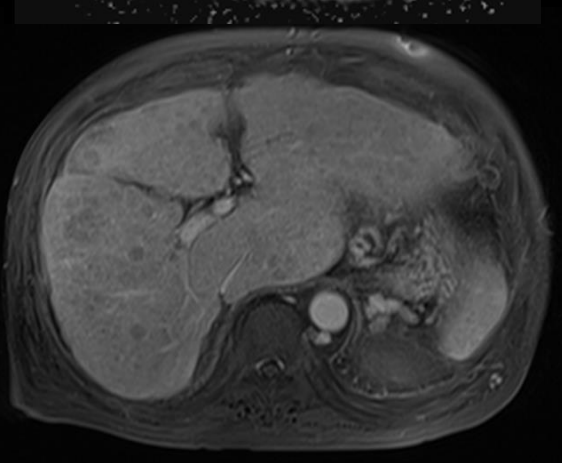
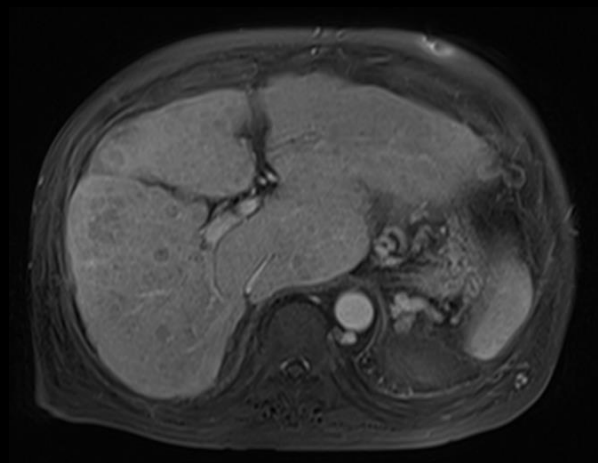
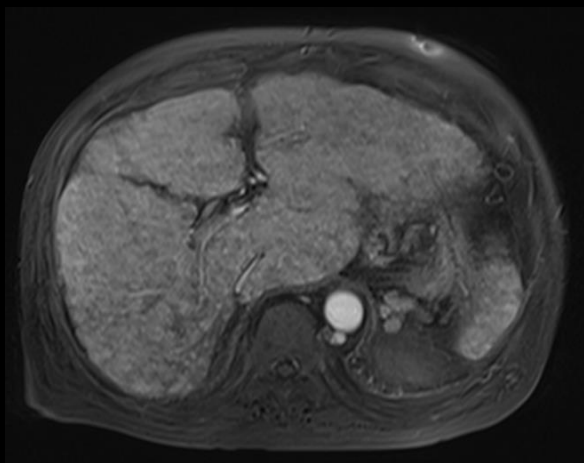
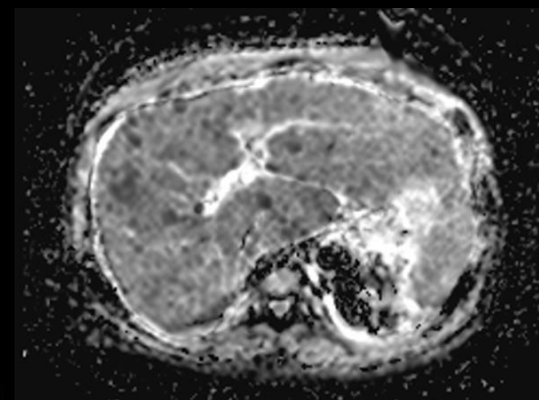
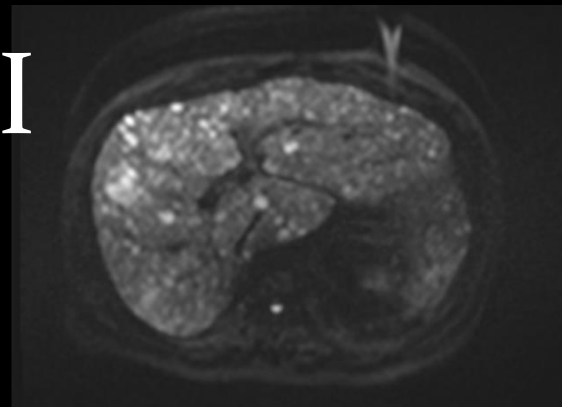
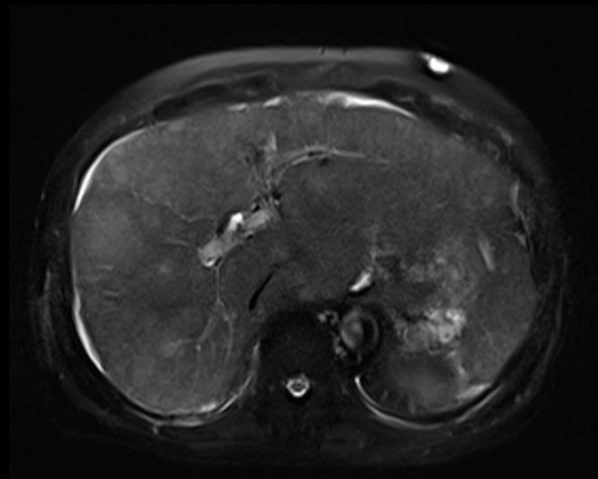
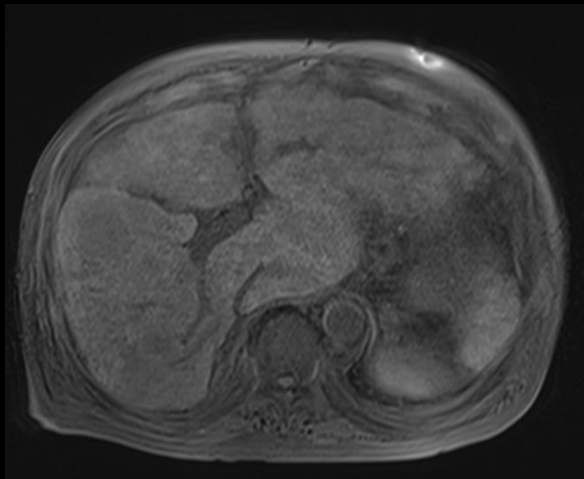
# Case 5

- 67M
- PHx: right renal RCC s/p cryoablation in 2020-10-12
- S: for follow up
- 2021-01-23 CT
- 2021-02-09 MRI

2021-01-23 CT



2021-02-09 MRI



# DDx

- HCC
- RCC metastasis