

**CASE 2**

**52 Y WOMAN**

**PSEUDOTUMOR OF THE NASOPHARYNX**

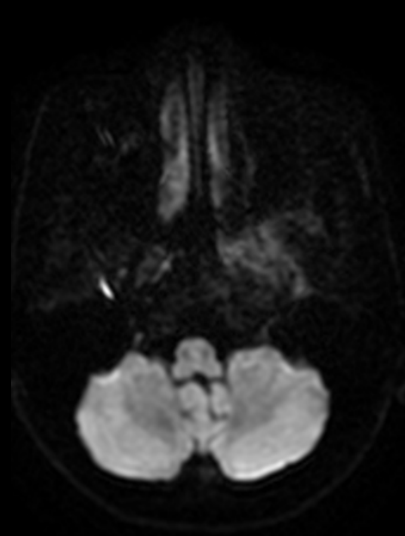# Brief history

- 52 years old woman
- Chief complain:
  - Headache for 2 weeks, left ear spreading to left whole face, persistent.
- PHx:
  - HBV
  - Remove left wisdom tooth last week
  - Left otitis media s/p ventilation tube insertion 2016

# Imaging

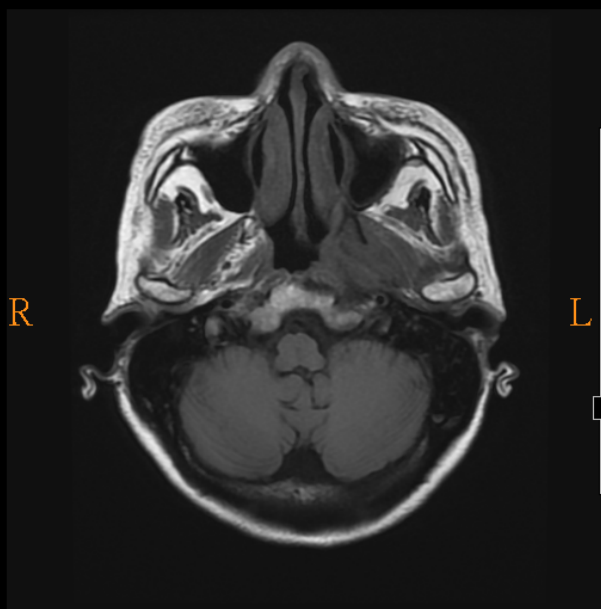
- 2017-03 Brain MRI +C

# Imaging findings



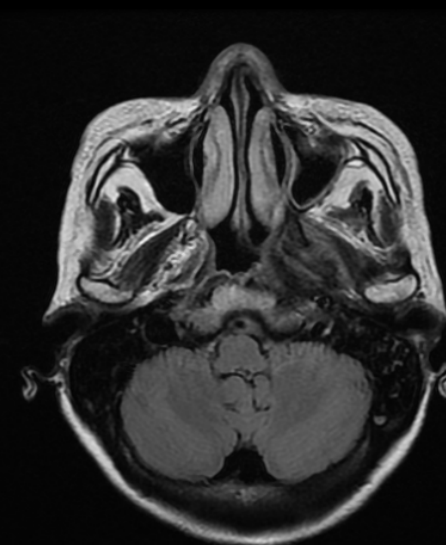
P  
A

L R

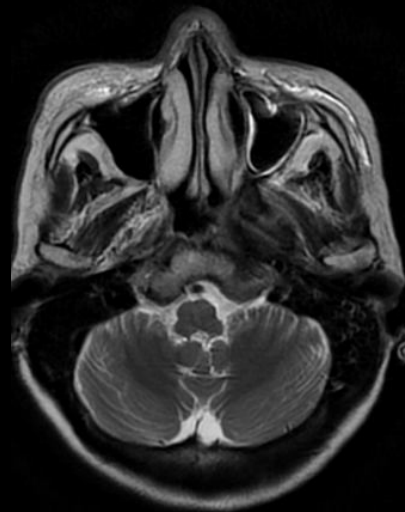


P  
A

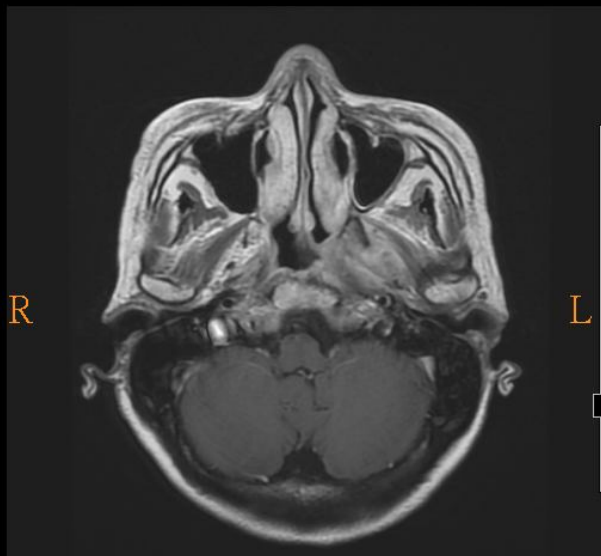
L R



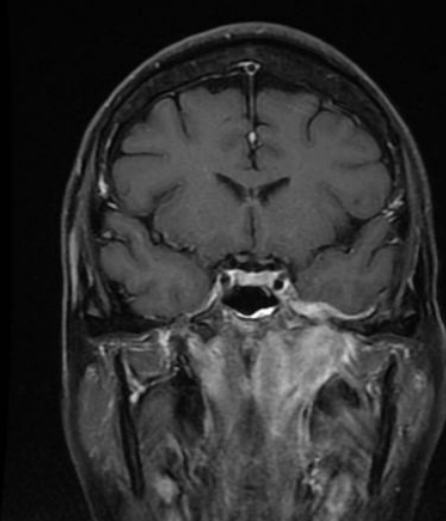
P



L R



L R



# Diagnosis

- To rule out malignency=>
- 2017-04 Biopsy
  - Pathology: chronic inflammation and fibrosis
- Diagnosis:
  - Fibrosing inflammatory pseudotumor of the nasopharynx

# Fibrosing inflammatory pseudotumor of the nasopharynx

- idiopathic, inflammatory lesions
  - Location: orbit, larynx, the paranasal sinuses, skull base.
  - can be locally aggressive and mimics a malignant lesion.
- Very rare
- Difficult to differentiate with malignency without biopsy
  - Some MRI characters of pseudotumor:
    - hypointensity on T2-weighted images.
    - relatively weak enhancement.
    - no significant regional lymphadenopathy
    - good-response to steroid therapy.