

**CASE 4**

**83 Y WOMAN**

**INTRAVASCULAR LYMPHOMA**

# Brief history

- 83 years old woman.
- Chief complain
  - Had common cold recently. After taking medication, urine incontinence and poor response, general weakness is noted.
- PHx:
  - Follicular lymphoma s/p treatment with complete remission 4 years ago.

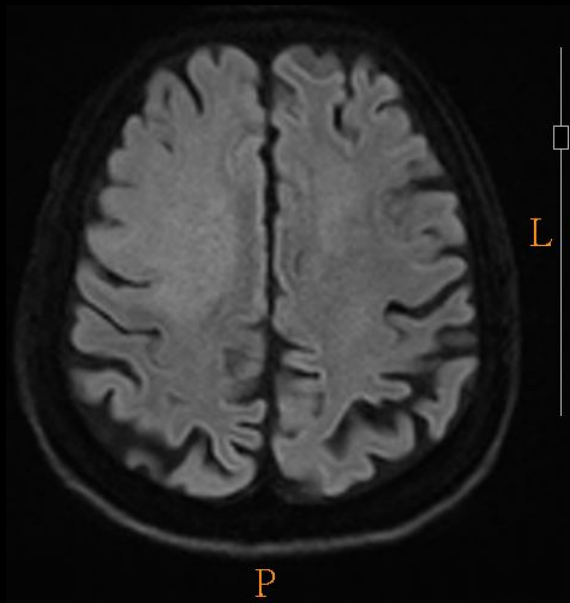
# Imaging

- 2017-12 Brain CT No C
- 2017-12 Brain MRI +C

-----

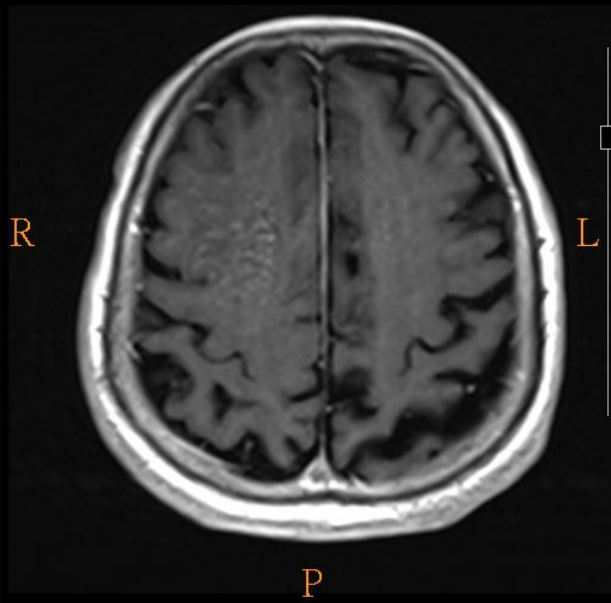
- Recent follow-up
- 2018-02 Brain MRI +C
- 2018-03 Brain CT NoC

# Imaging findings



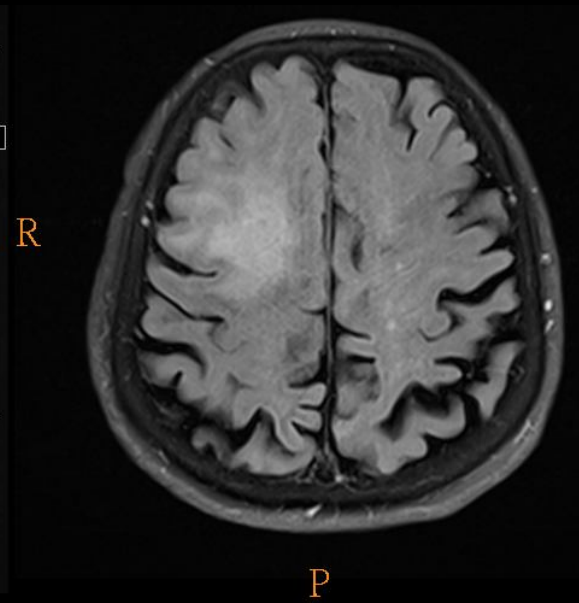
L R

P  
A

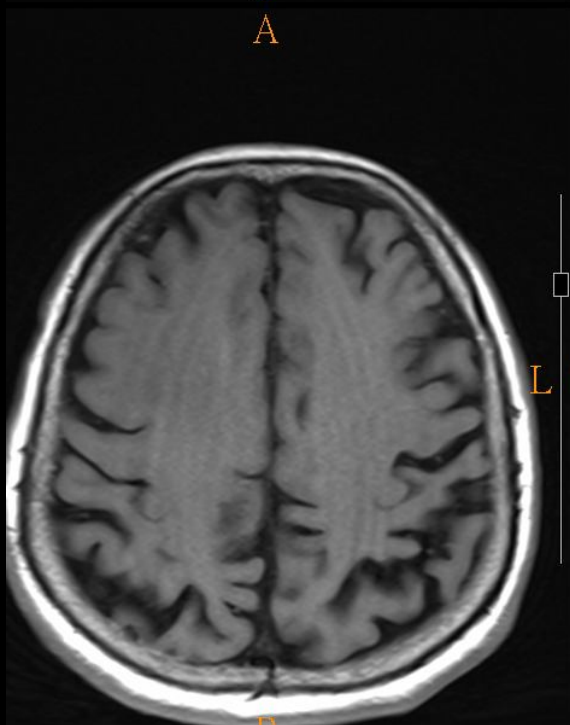


L R

P  
A

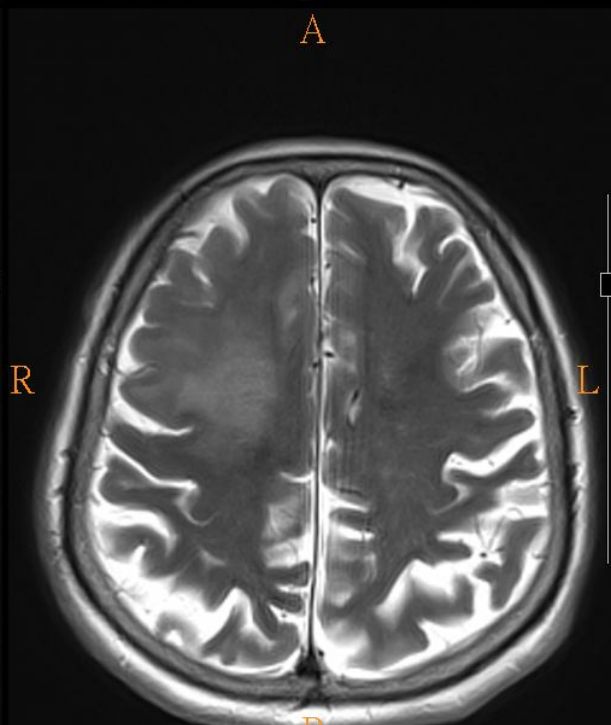


P  
A



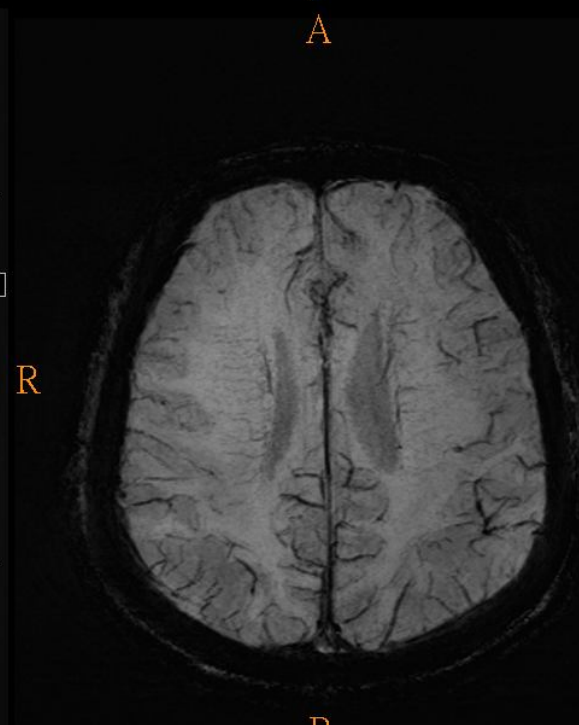
L R

P  
A



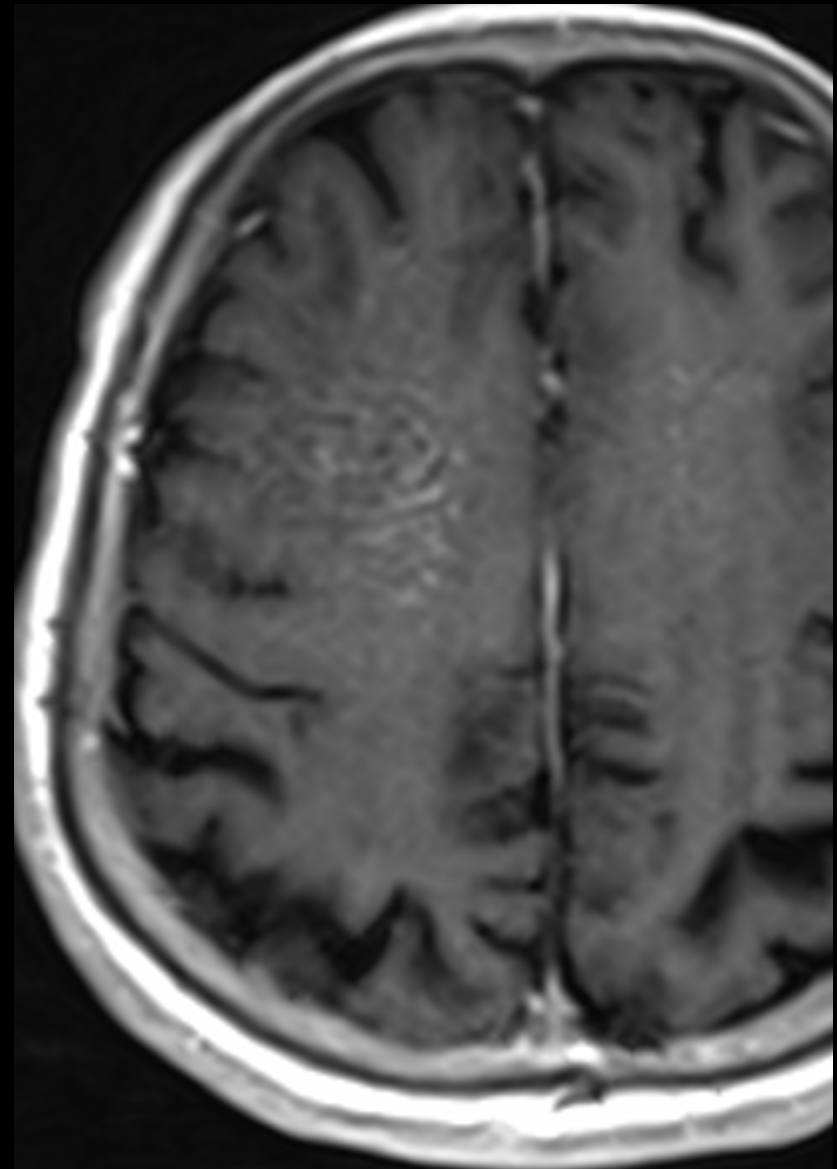
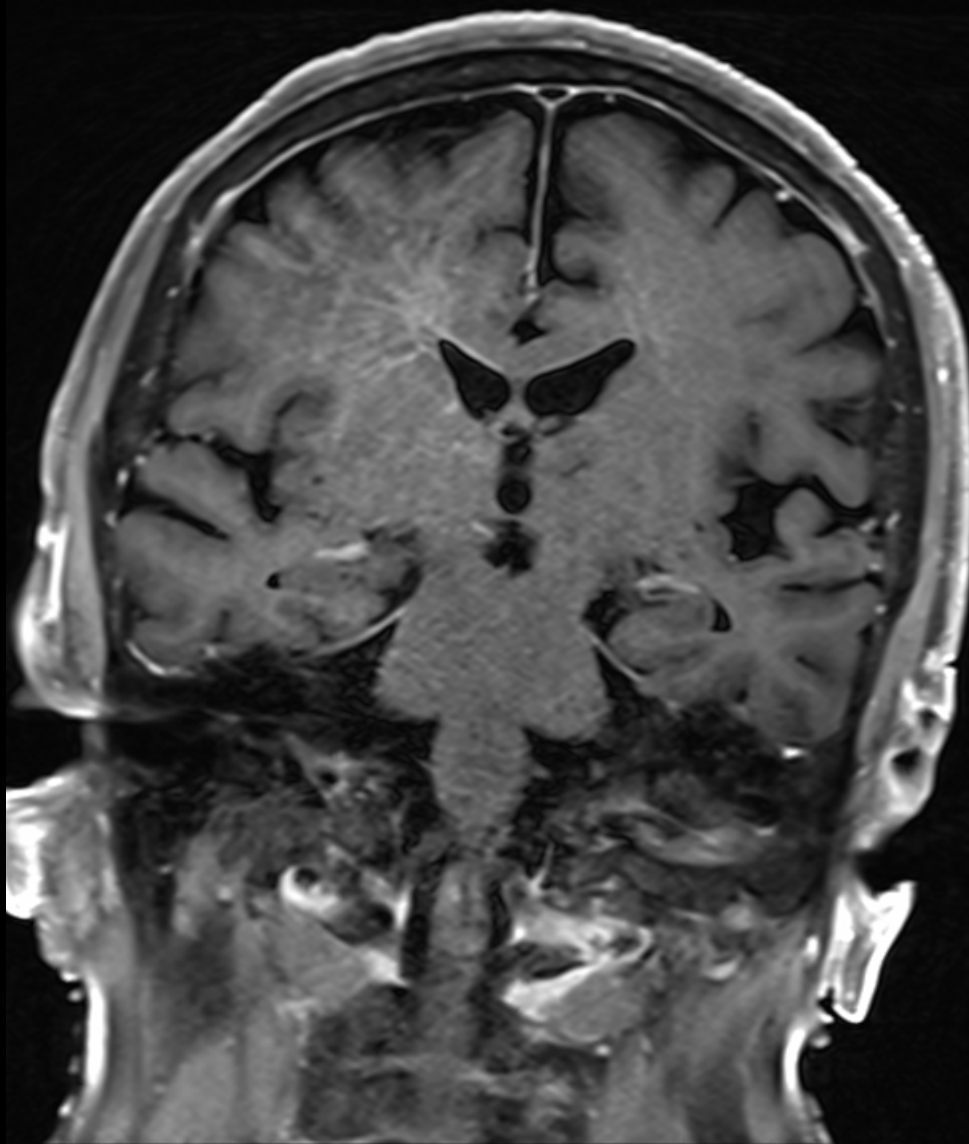
L R

P  
A



P  
A

T1+ C



# Diagnosis

White matter lesion...

With linear enhancing inside

- ADEM ? => post IVIG, no improve, lesion still exist after 2 months
- Progressive multifocal leukoencephalopathy ?
- Tumefactive demyelinating lesion ?
- Intravascular lymphoma ?

# Intravascular lymphoma

- Intravascular lymphoma
  - rare subtype of extranodal diffuse large B-cell lymphoma
  - proliferation of clonal lymphocytes within small vessels with relative sparing of the surrounding tissue.
  - 5th-7th decades; mean: 60-65 years
  - Common involve organ
    - Brain, skin
    - Skin changes: Raised plaques or nodules over abdomen and thighs (50%)
    - Rare, diagnosis often made postmortem

# Intravascular lymphoma

- Intravascular lymphoma
  - No malignant cells in peripheral blood smear or bone marrow
  - Absence of lymphadenopathy is typical
  - Mean survival: 7-13 months
  - Mortality rate: > 80%



# Clinical course

- No significant improvement after IVIG.
  - Dysphagia developed
- => Aspiration pneumonia