

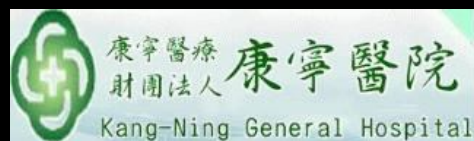---

# 與大師對談

康寧醫院 許居誠教授

---

莊凱壹 醫師(R4) 賴欣宜 醫師



# 規則

---

- 依照臨床時序，請大師模擬一線放射科醫師；於未知診斷，或者有限度臨床線索之情形下，進行閱片及解讀
- 鑑別診斷為主要，確定診斷為次要
  - 目的在於學習大師之影像判讀邏輯思考
- 探討乳房影像
- 大師評論本院影像品質建議及改進

# Case 1

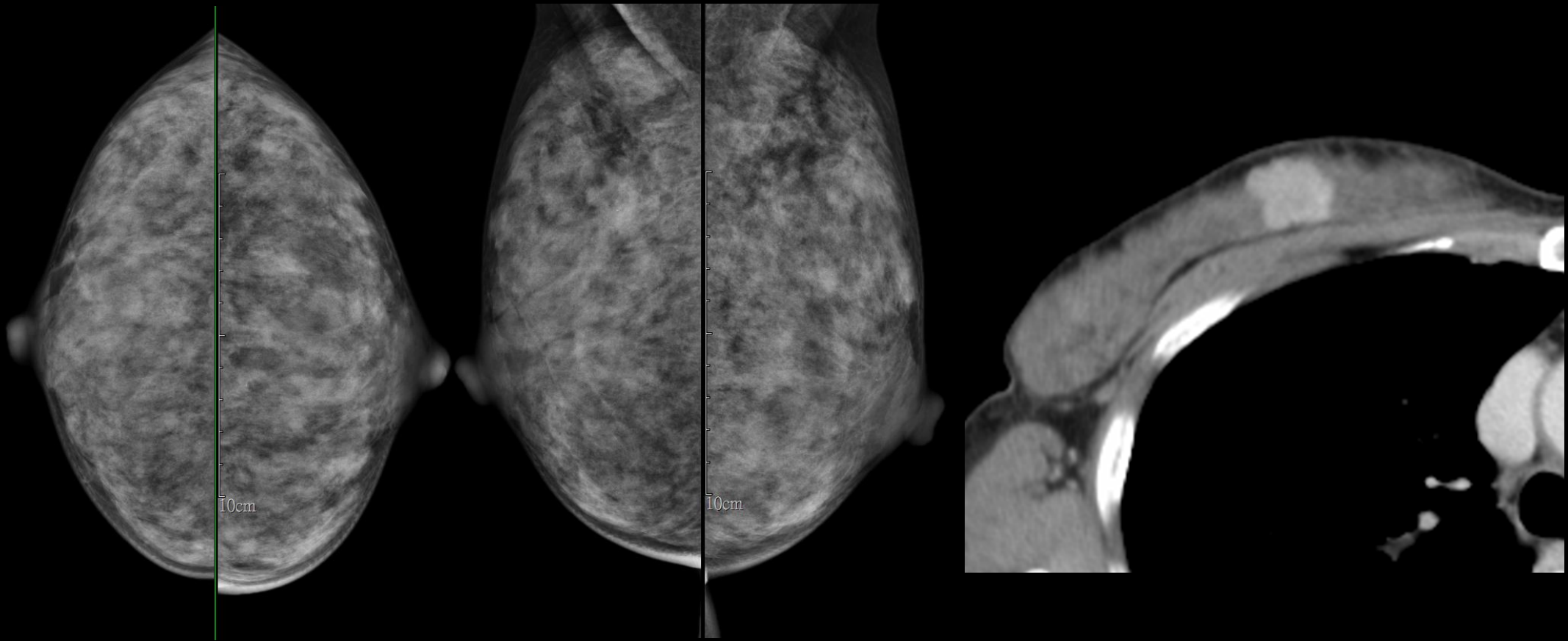
44F

Breast mass was found for 1.5 years

# Images

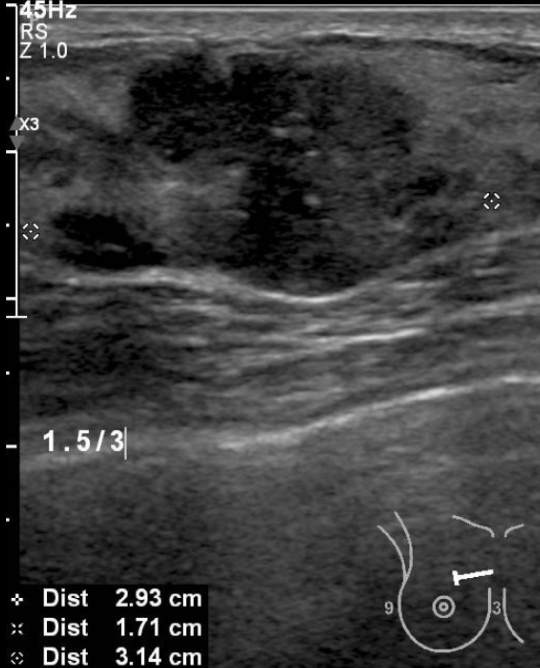
---

- 2019-02-12 Mammography
- 2019-01-23 Breast sonography
- 2019-02-11 Chest CT

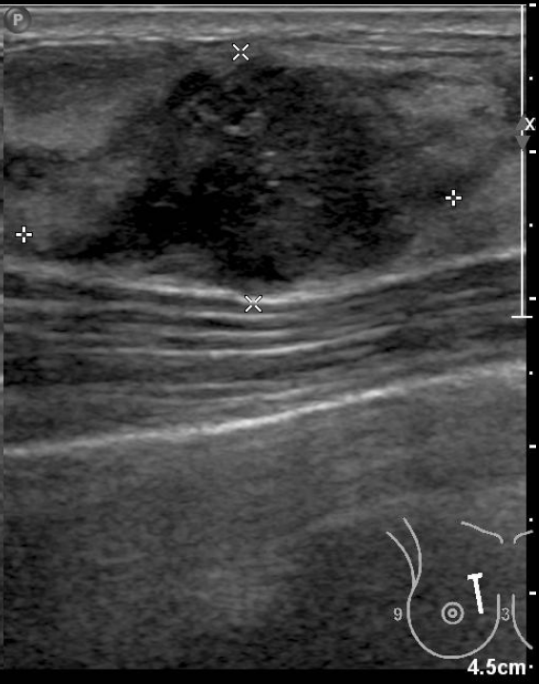

2.2 cm lobulated nodule with local hyperenhancement foci in UIQ of right breast

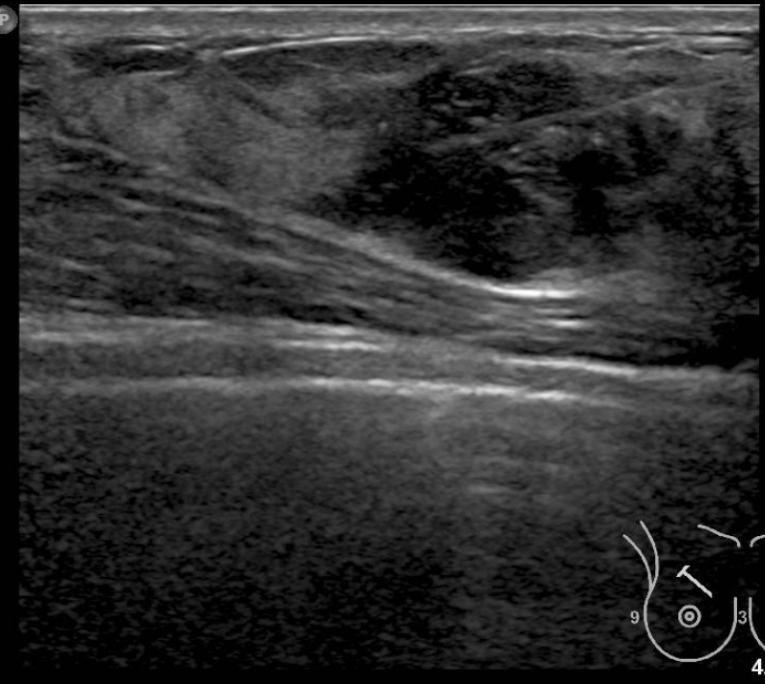
DR WANG  
L12-5  
45Hz  
RS  
Z 1.0  
x3  
1.5/3  
+ Dist 2.93 cm  
x Dist 1.71 cm  
◇ Dist 3.14 cm




1150.0 MI 0.8



DR WANG  
L12-5  
30Hz  
RS  
2D  
43%  
Dyn R 61  
P Low  
Res  
TAC1



1150.0 MI 0.7



# Pathology

---

- Breast, right, partial mastectomy, invasive ductal carcinoma
- Lymph node, axilla, sentinel, right, biopsy, no metastasis (0/3)