

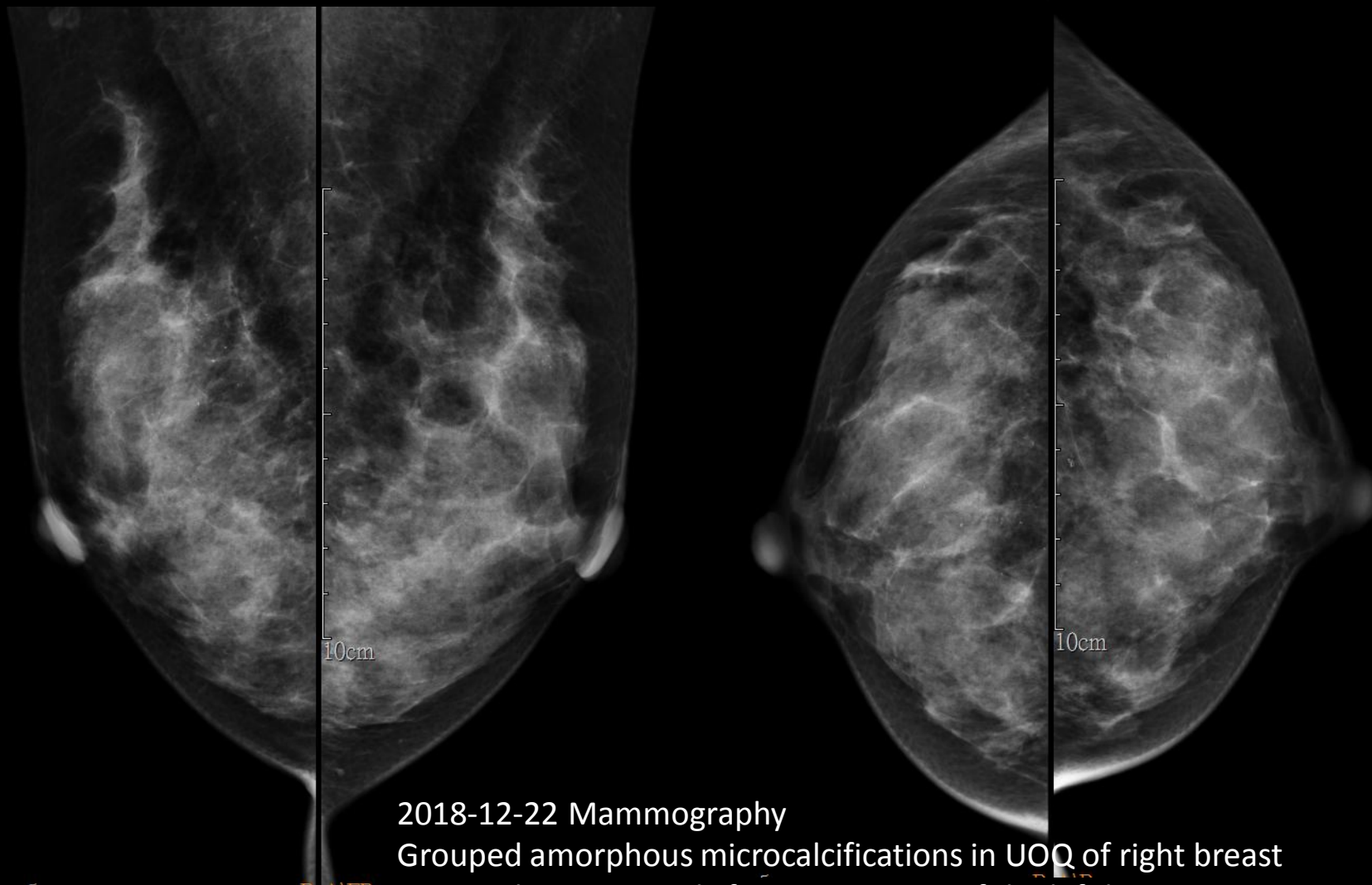
Case 3

43F

Screening mammography

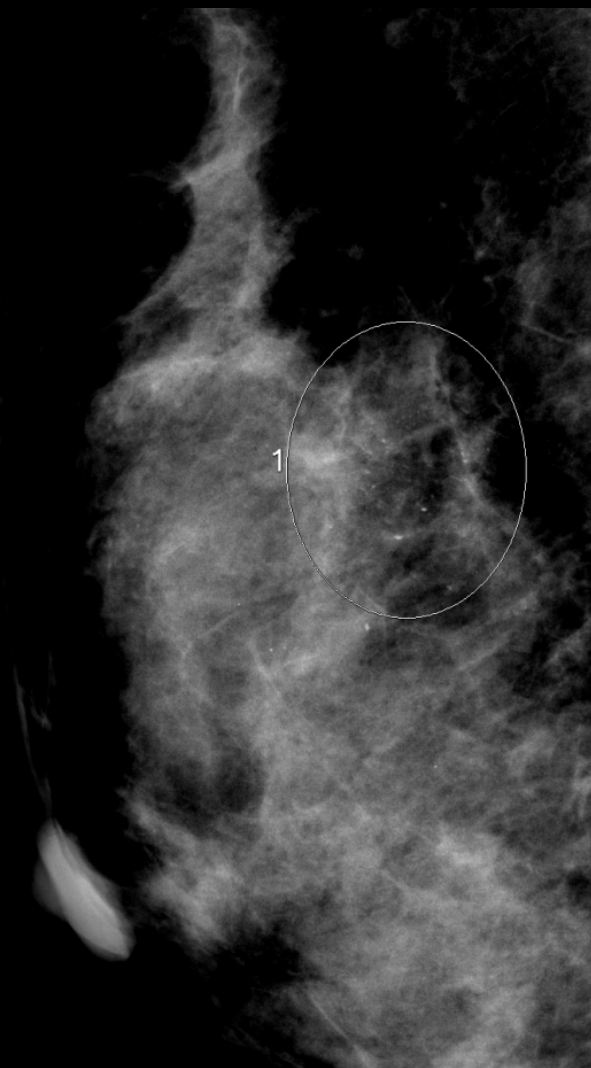Images

- 2018-12-22 Mammography
- 2019-01-10 Mag Mammography

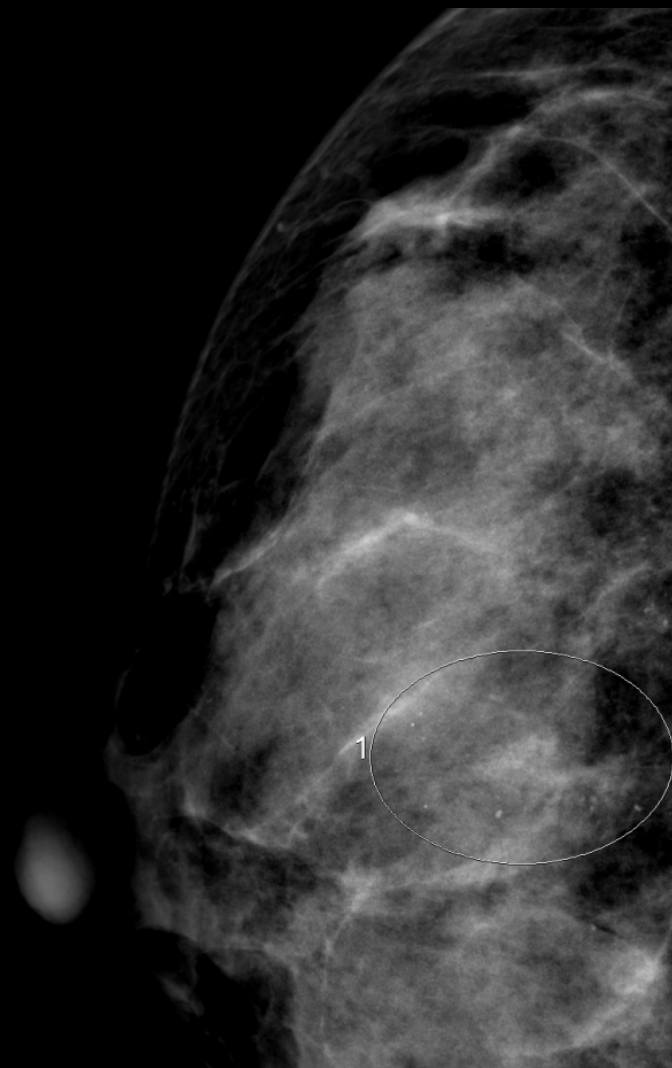


2018-12-22 Mammography
Grouped amorphous microcalcifications in UOQ of right breast
Grouped punctate calcifications in LOQ of the left breast

R
MLO



R
CC



Pathology

- Localization: DCIS
- Partial mastectomy: DCIS

R
CC

