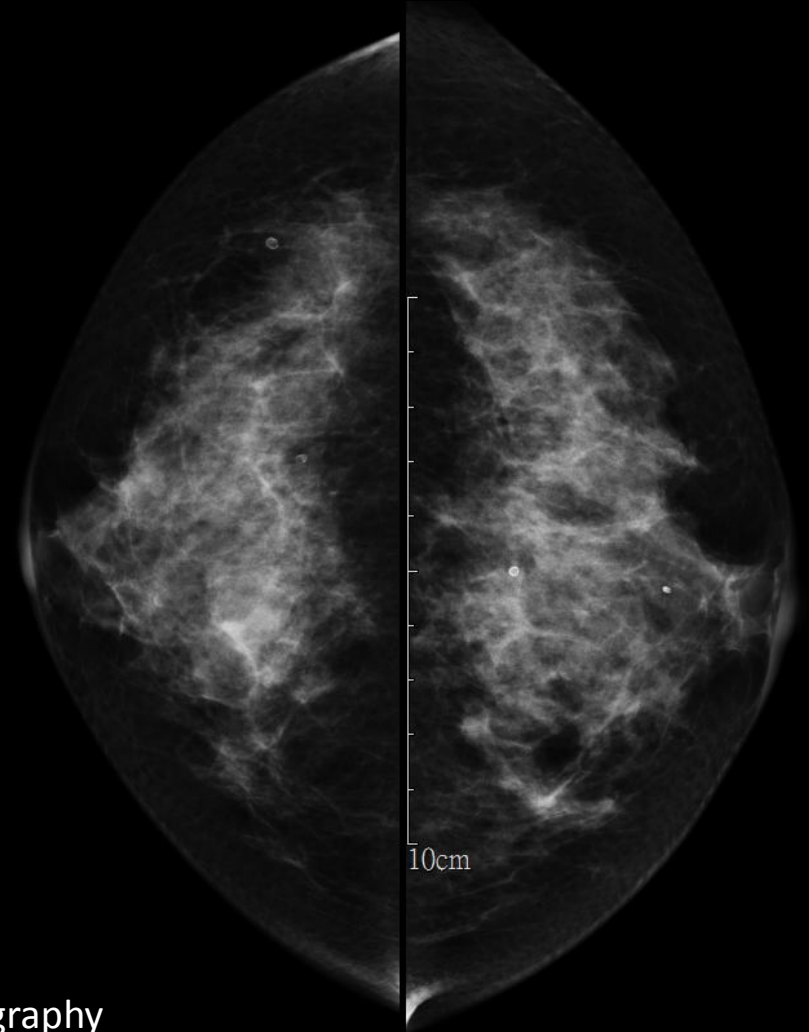
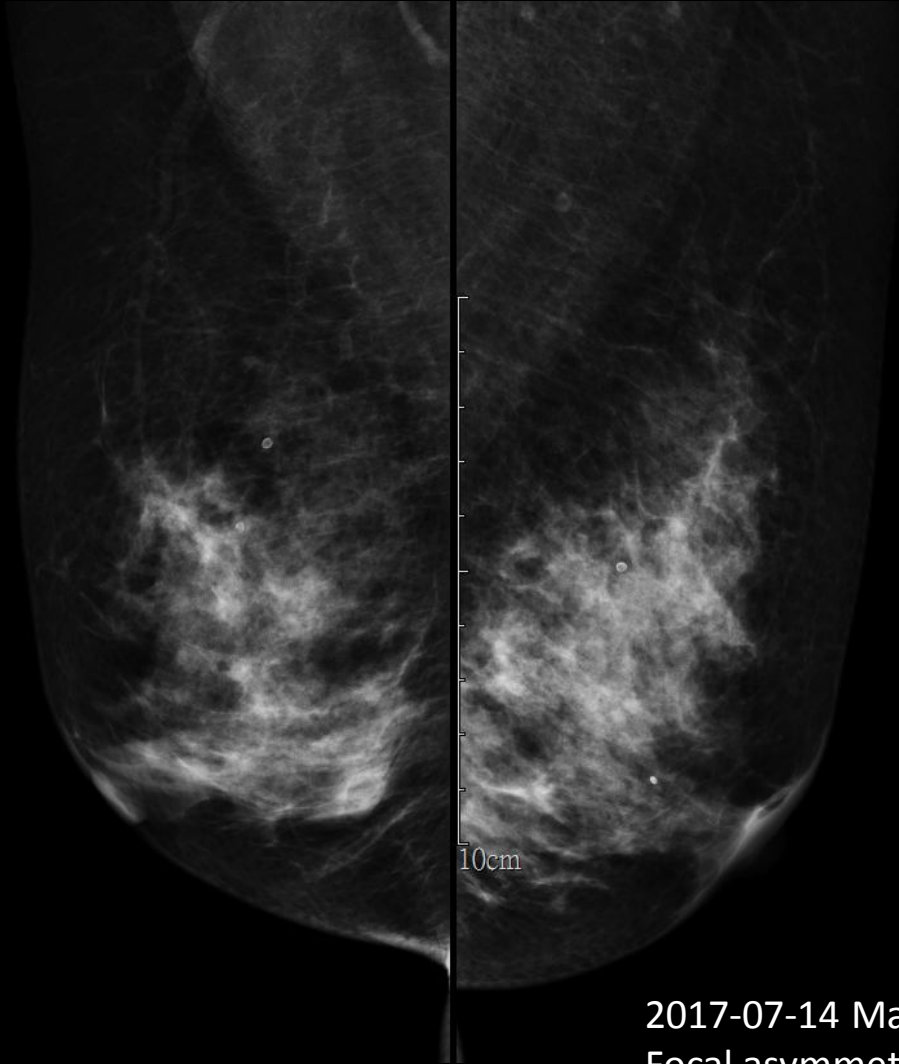


Case 6

58F

Images

- 2017-07-14 Mammography
- 2017-06-15 Breast sonography

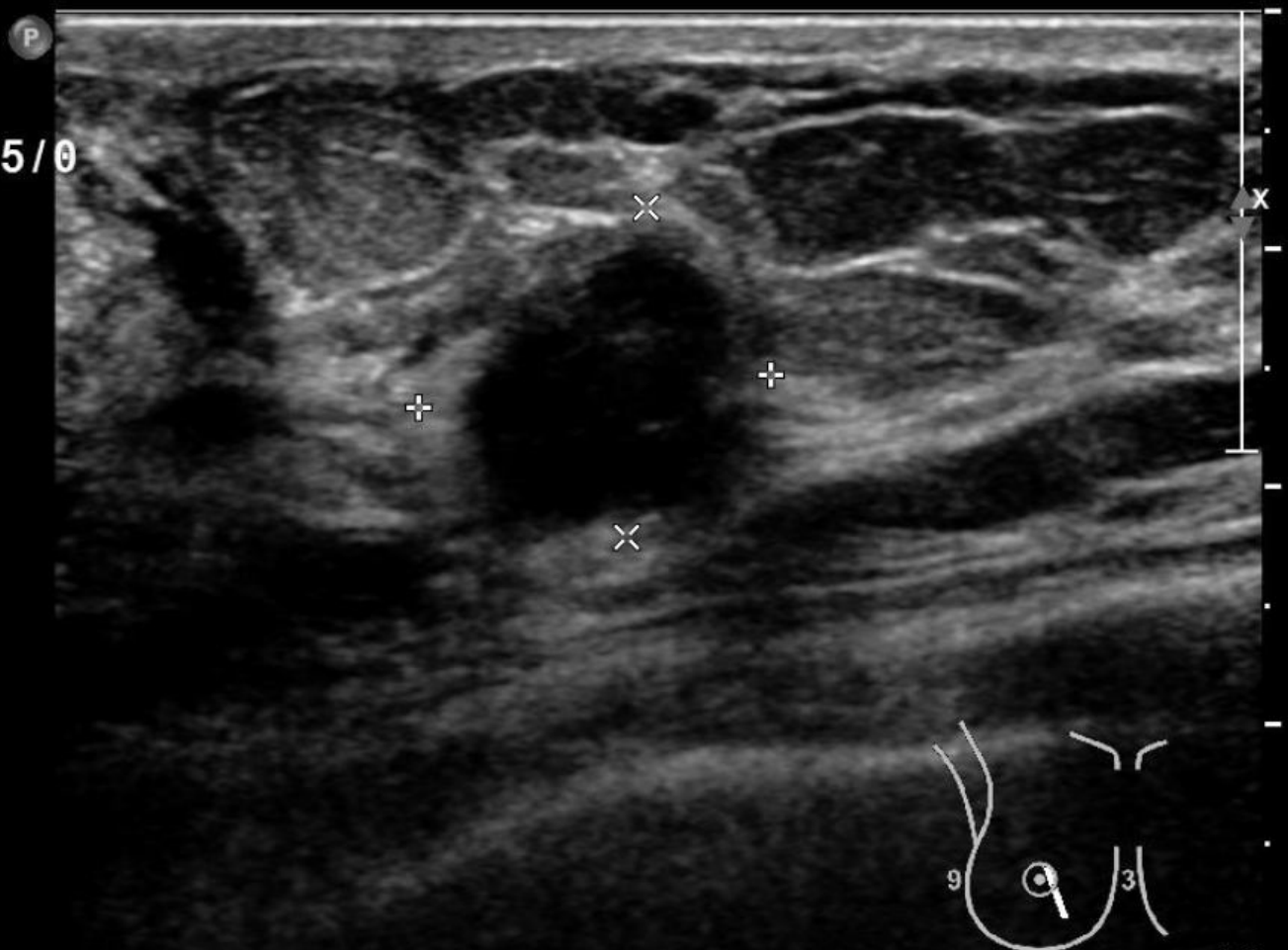


2017-07-14 Mammography
Focal asymmetry in LIQ portion of the right breast

FR 42Hz
RS

2D
64%
C 50
P Med
Gen
TAC1

5 / 0

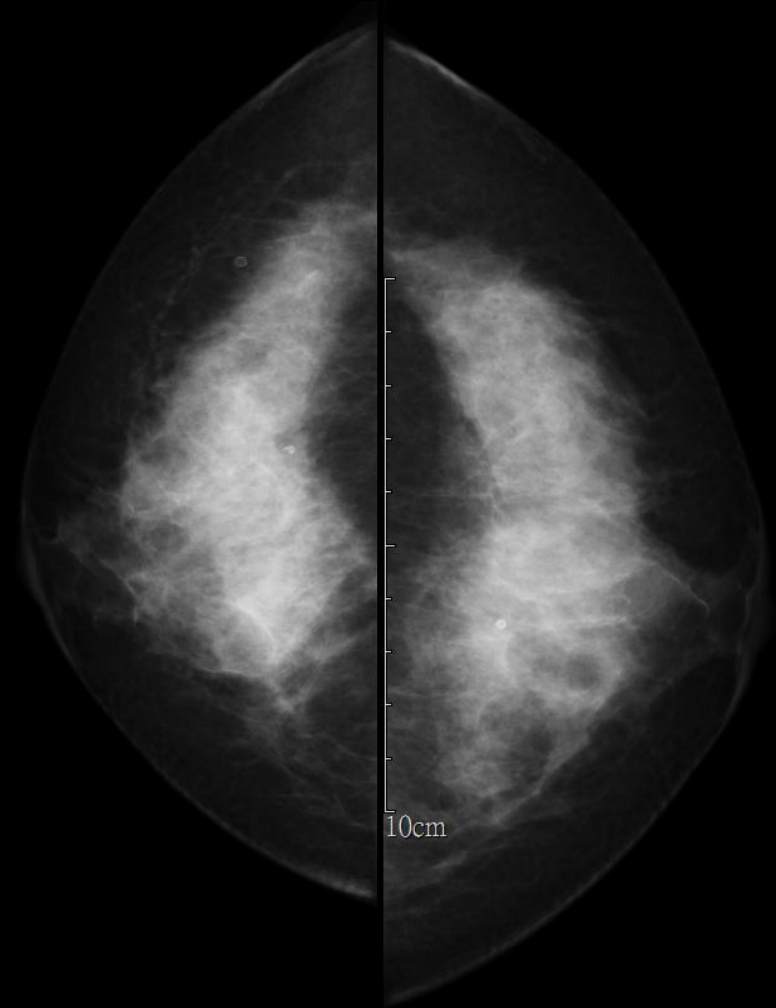
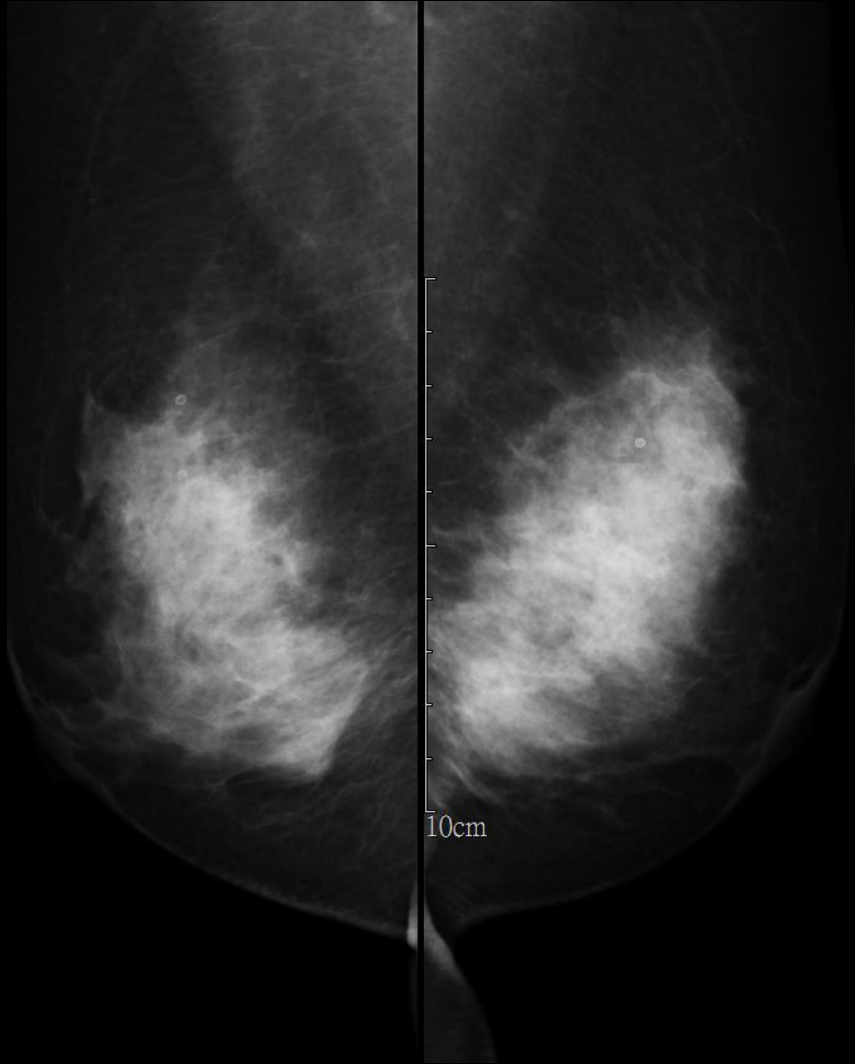


+ Dist 1.49 cm

x Dist 1.39 cm

Images

- 2013-09-13 Mammography



Pathology

- Breast, 5/1 cm, right, core needle biopsy, adenoid cystic carcinoma
- Breast, right, simple mastectomy, adenoid cystic carcinoma (pathologic stage: T1N0; Stage Groupings: Stage IA)
- Lymph node, axillary, sentinel, right, intraoperative biopsy, no metastasis (0/1)