

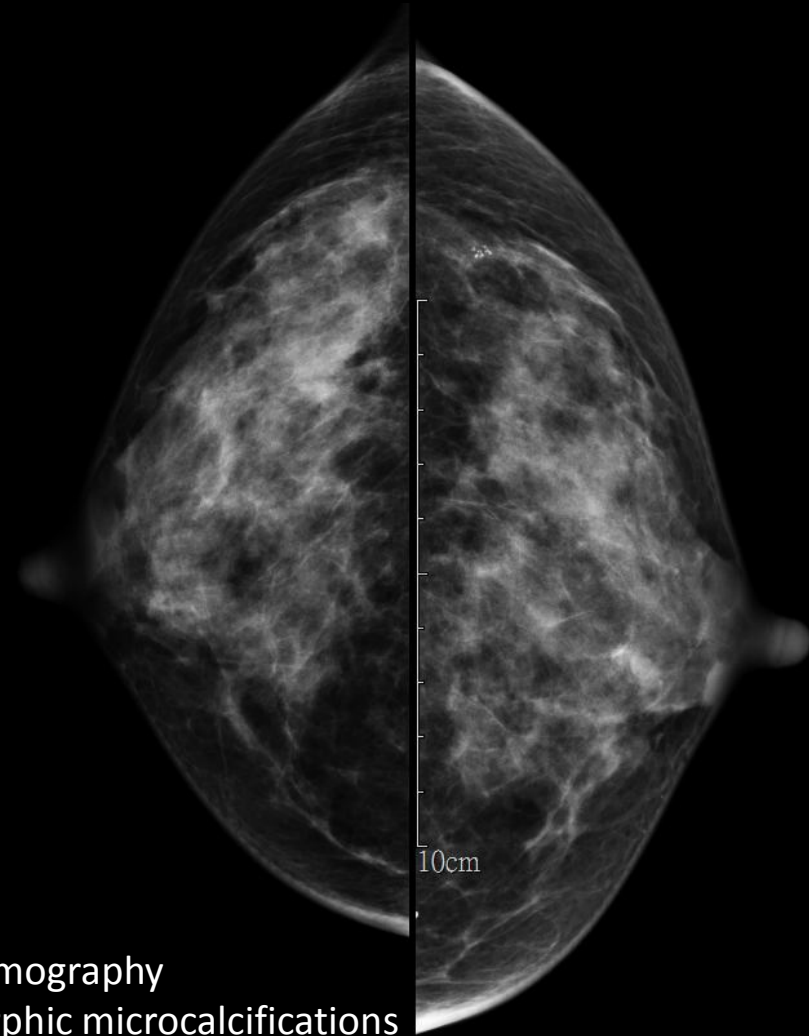
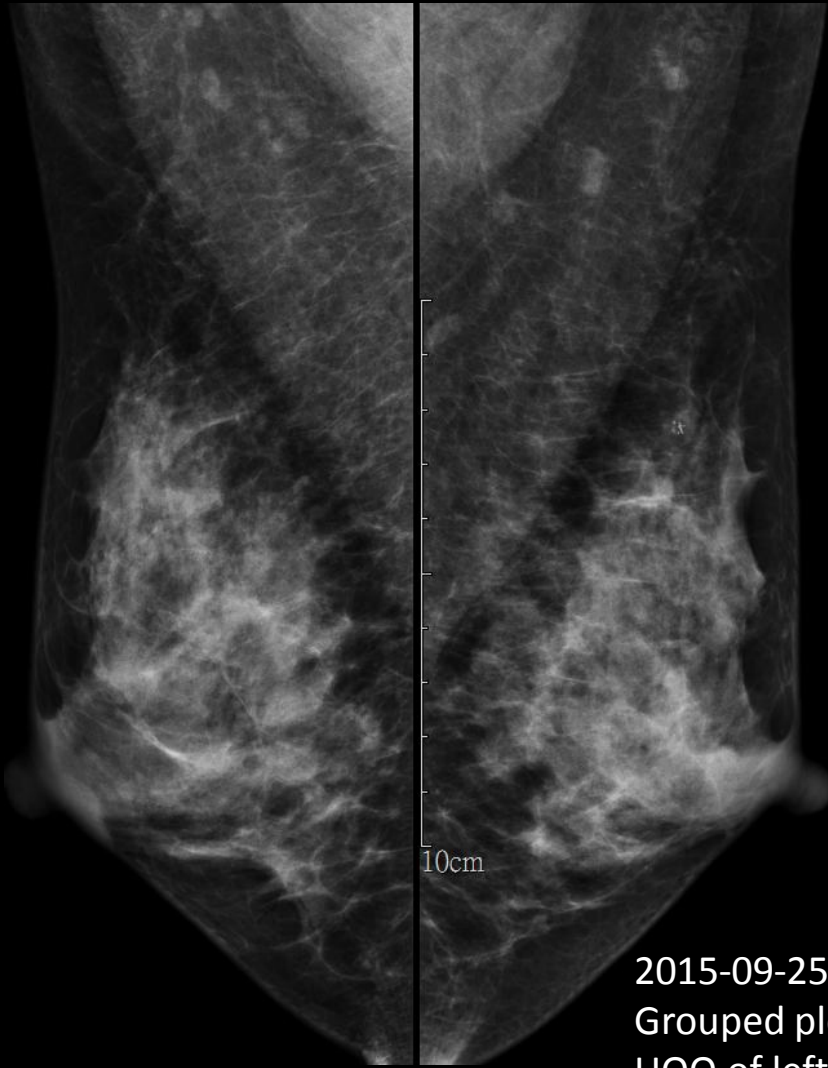# Case 8

47F

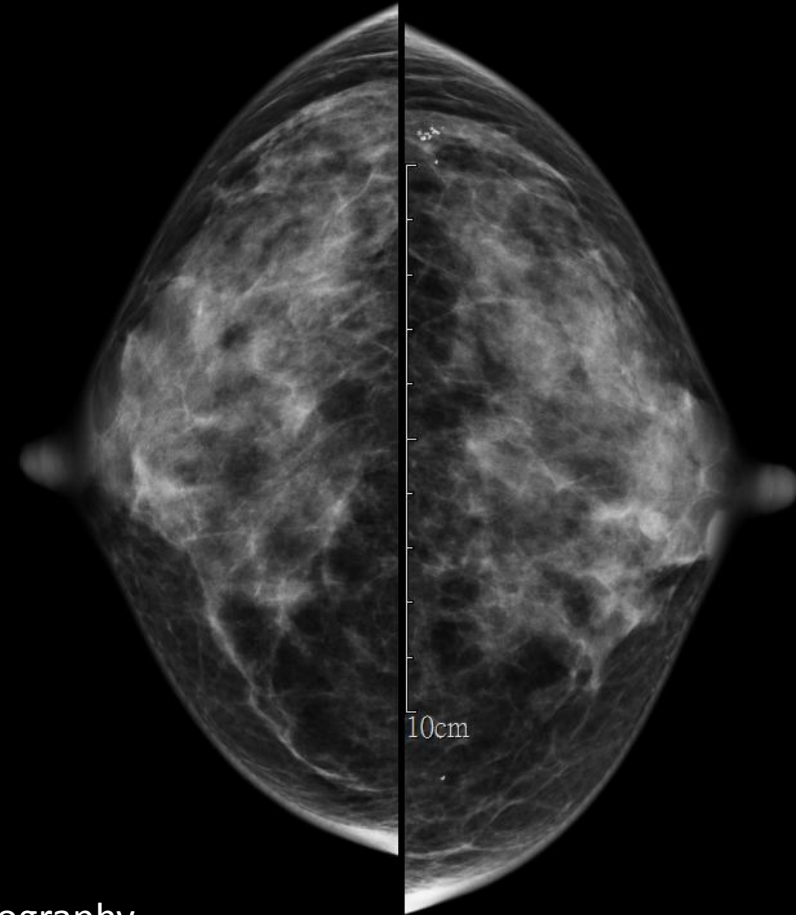
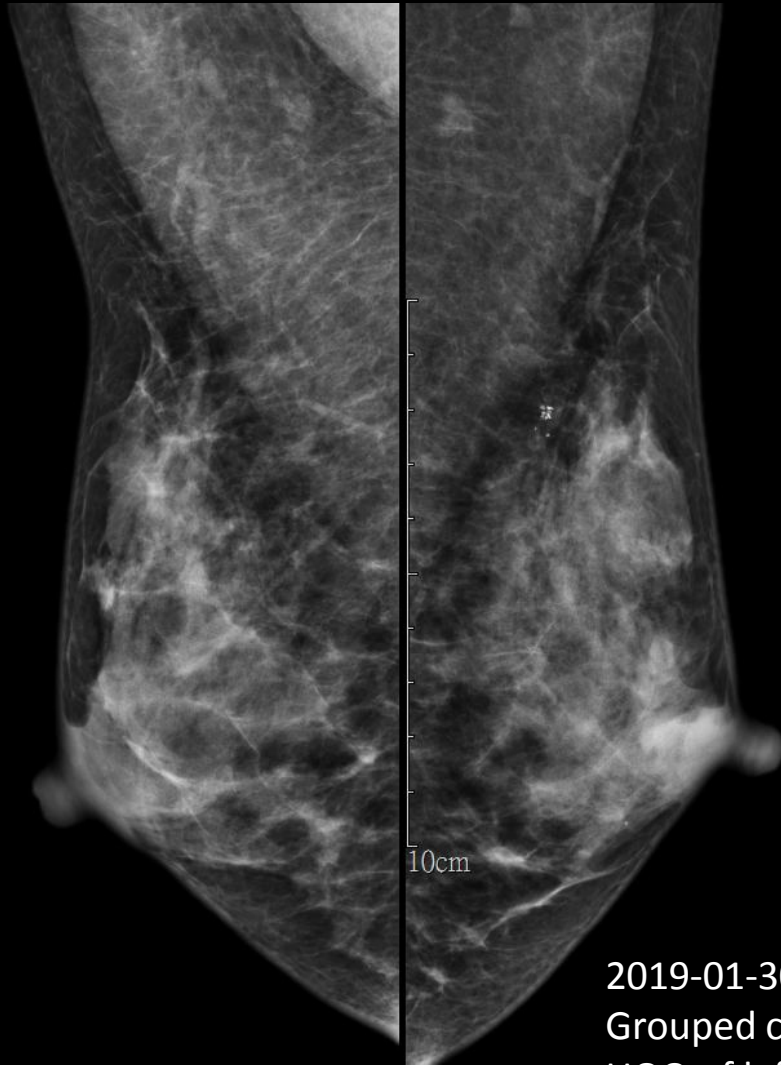# Images

---

- 2015-09-25 Mammography
- 2019-01-30 Mammography



2015-09-25 Mammography  
Grouped pleomorphic microcalcifications  
UOQ of left breast



2019-01-30 Mammography  
Grouped coarse heterogeneous microcalcifications  
UOQ of left breast, no pathology

---

# Thanks for your attention

---

莊凱壹 醫師(R4) 賴欣宜 醫師