

Case2

76 Y/O WOMAN

CRYPTOCOCCUS PNEUMONIA

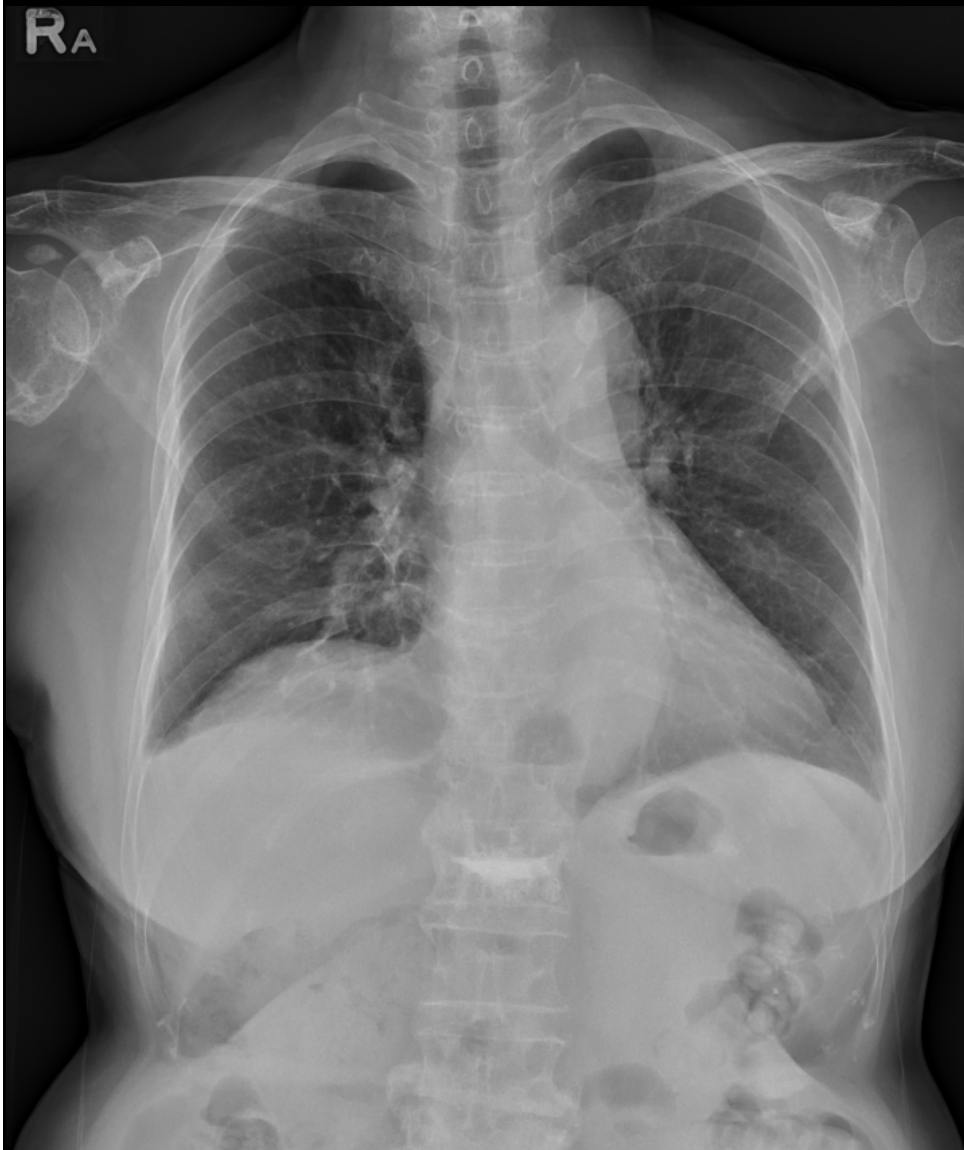
Brief history

- 76 y/o woman
- PH:
 - Multiple myeloma s/p chemotherapy
 - Diabetes mellitus
- Chief complain
 - Cough, dizziness and headache for 3 days.

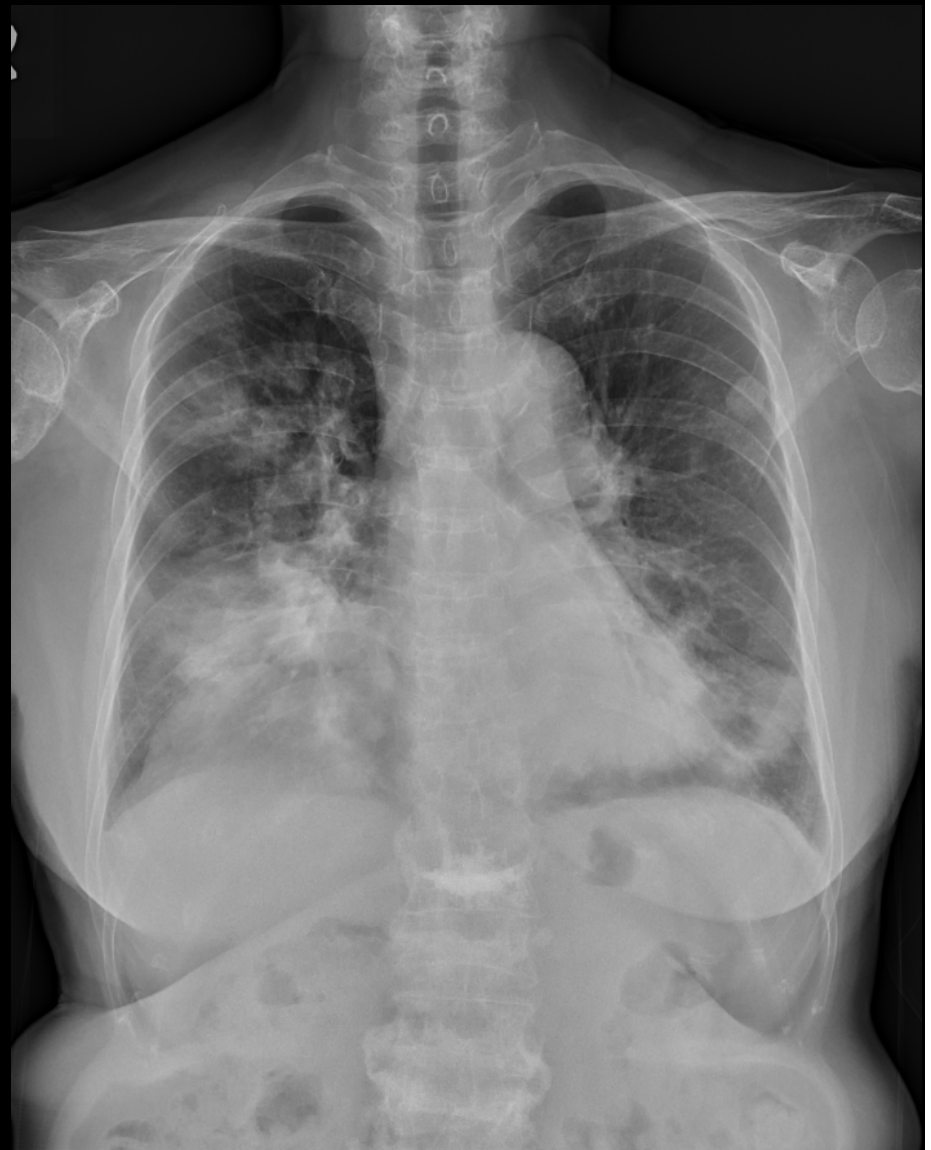
Imaging

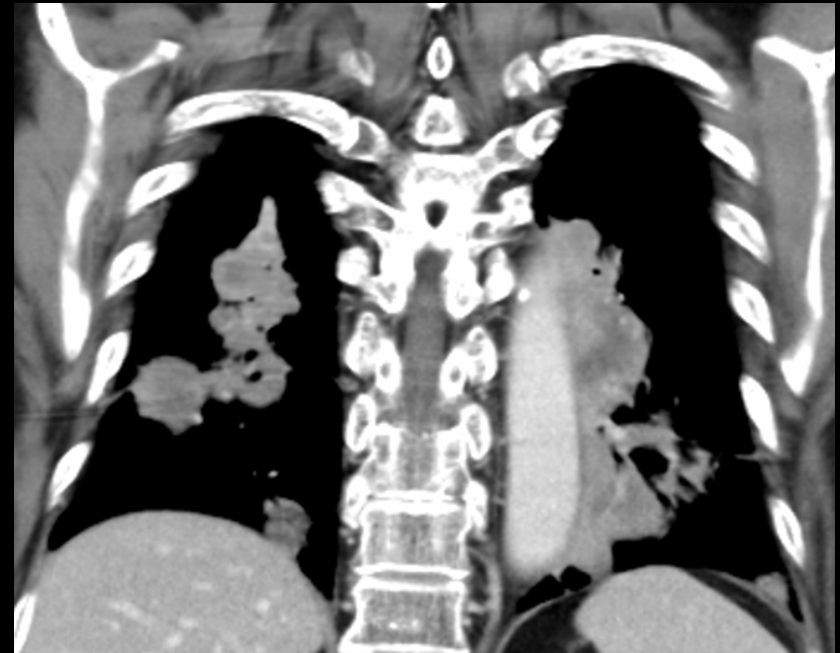
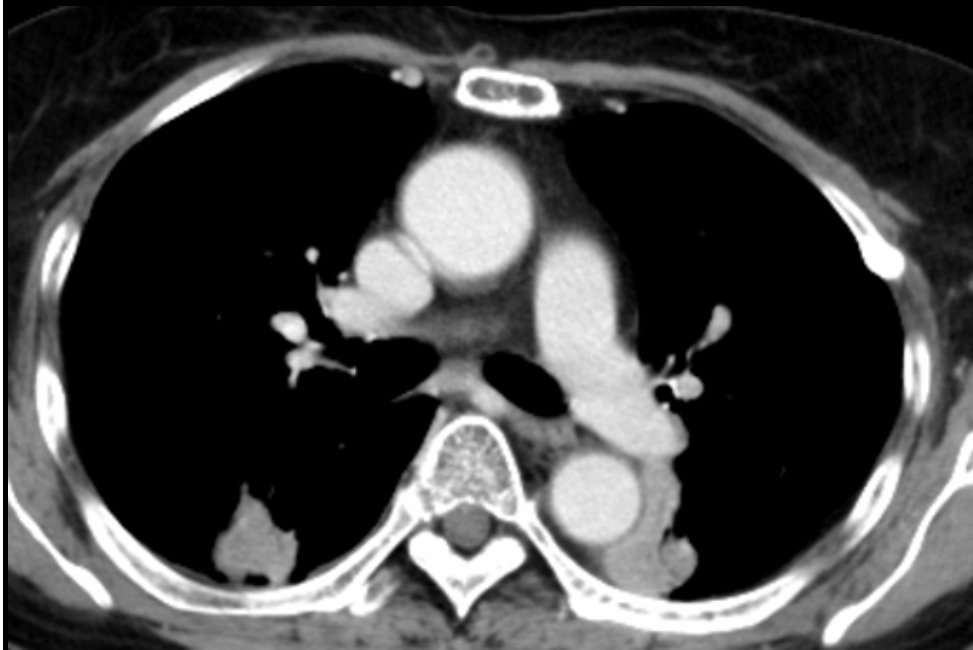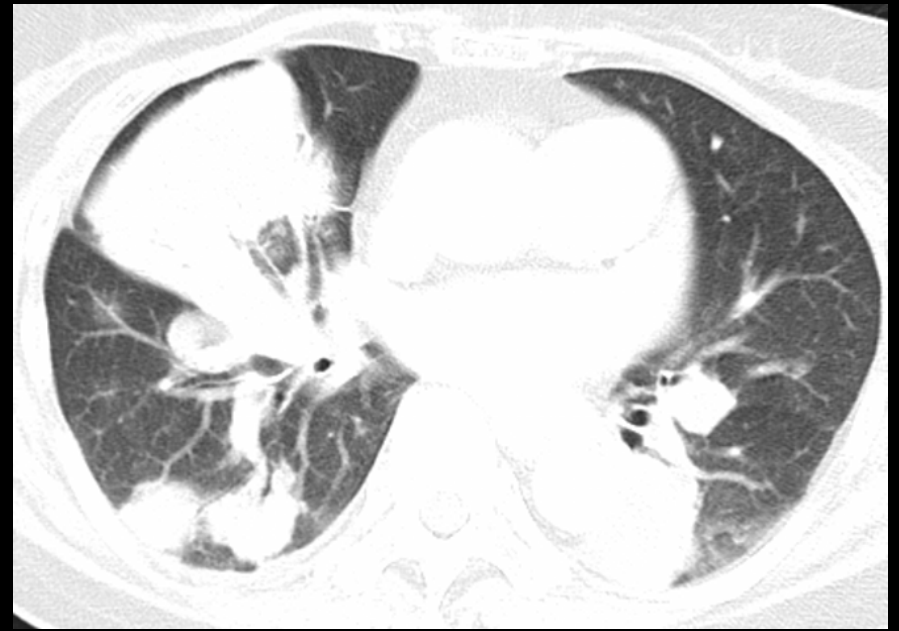
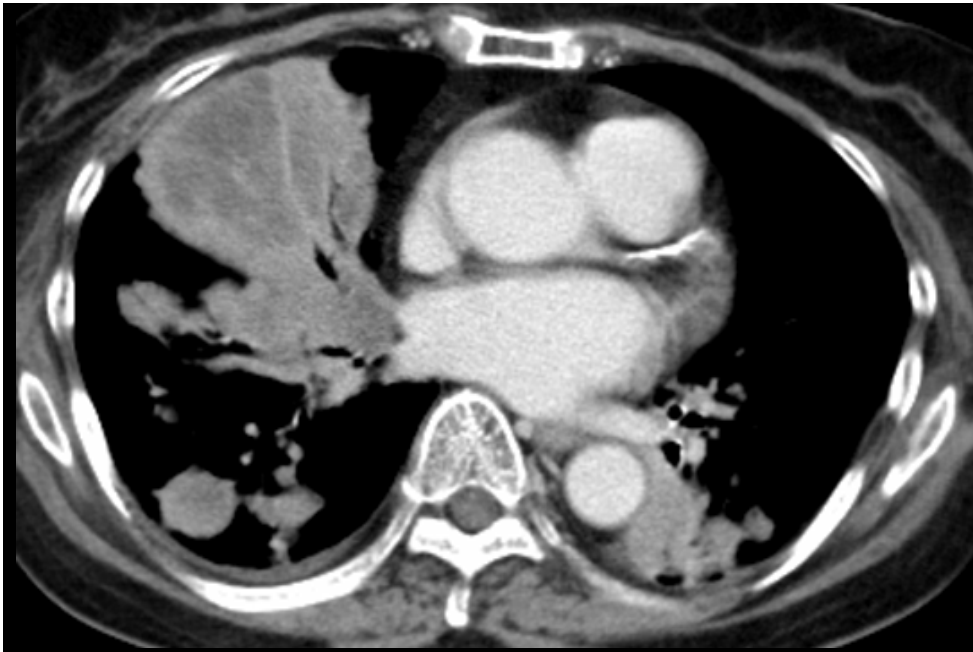
- CXR
- Chest CT

Last year



Now



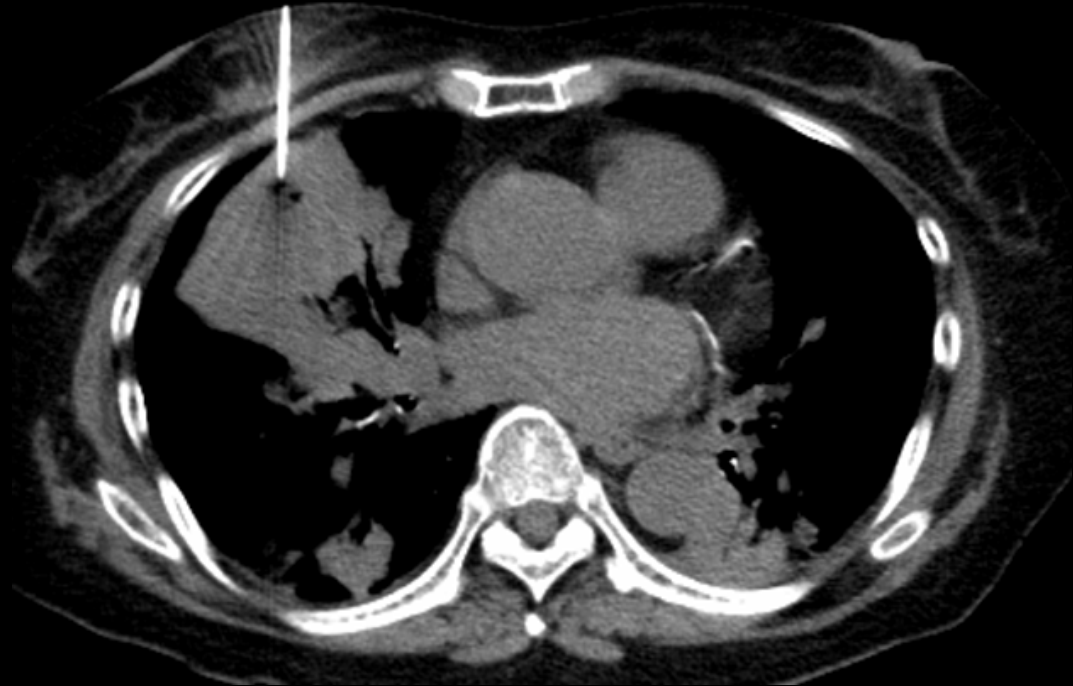
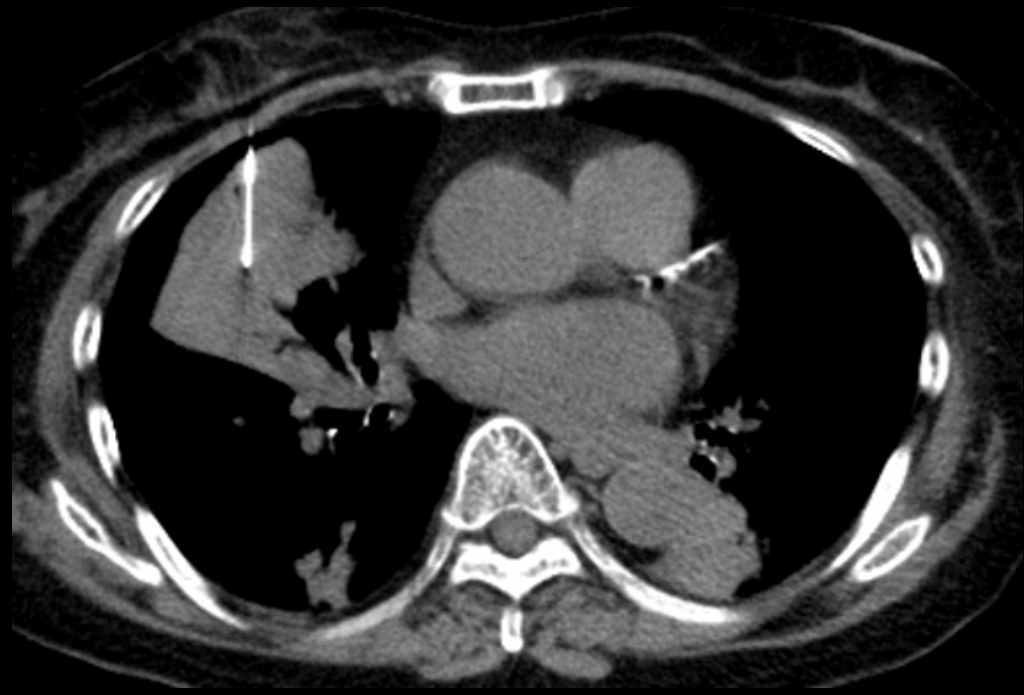
DDx:

- Lung cancer
- Metastasis
- Other

Clinical course

- Arrange CT-guide biopsy



Final diagnosis

- Lung cancer
- Metastasis
- **Cryptococcus infection**