

**CASE 4**

**60 Y/O MAN**

# Brief history

- **Past history**

- hypertension
- duodenal ulcer
- chronic smoker (1PPD for 40 years)

- **Chief complain**

Incidental finding of a pulmonary lesion during health check-up months ago at an outside clinic

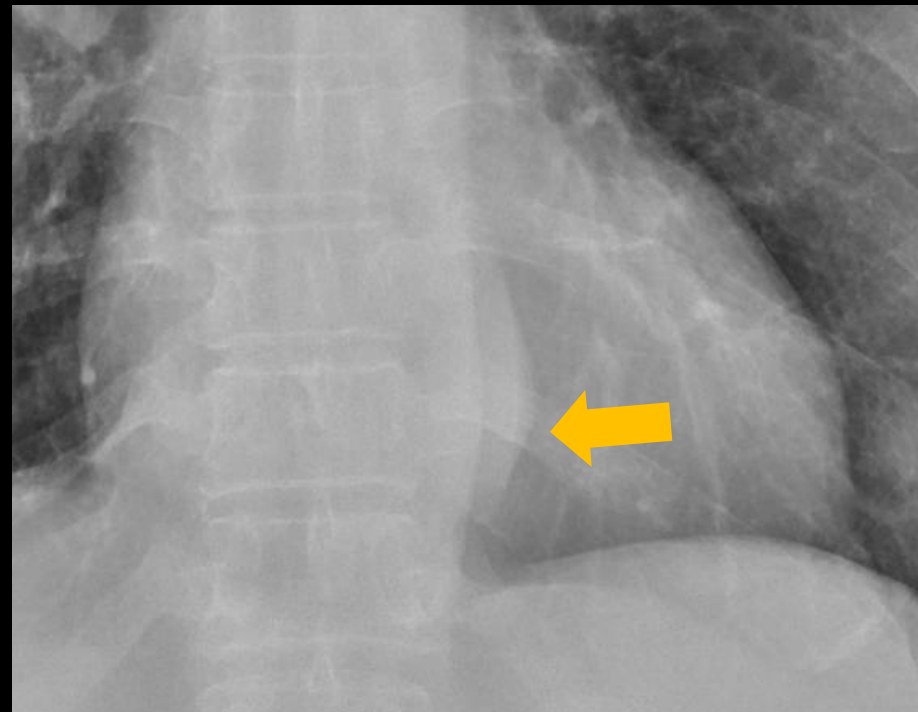
# Imaging studies

CXR

Chest CT +C

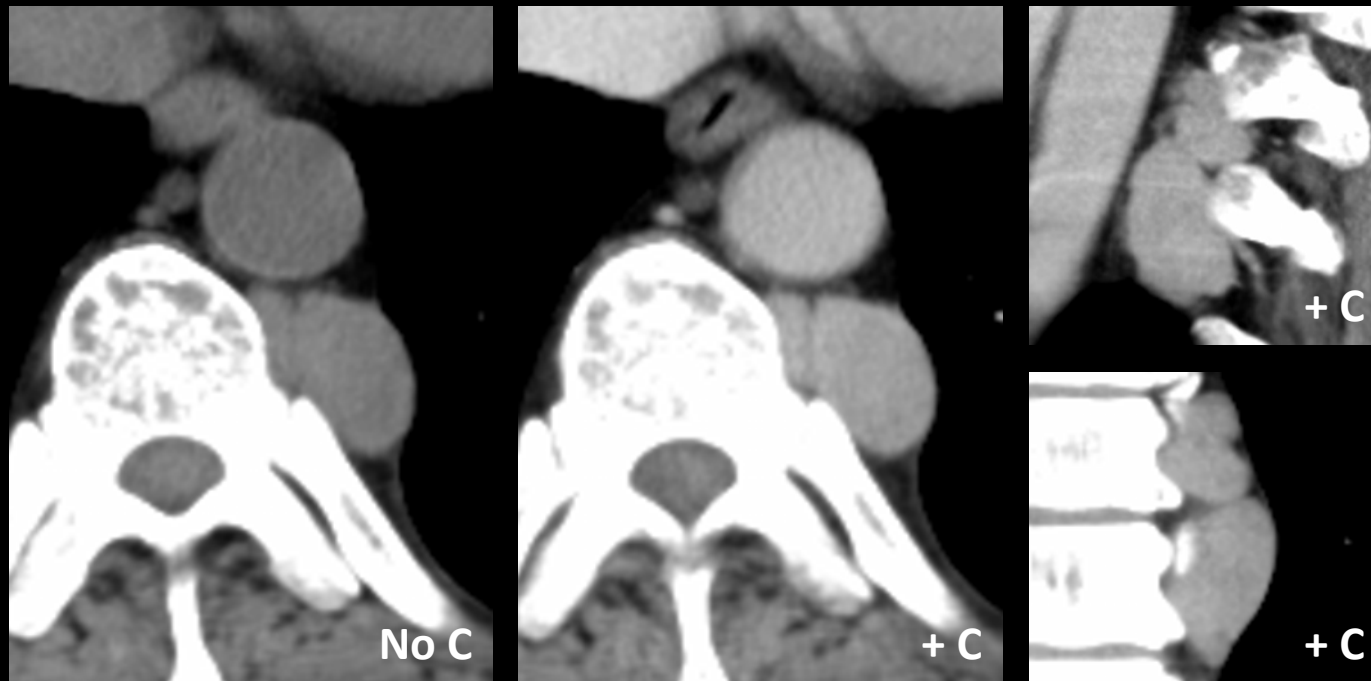# CXR

- ✓ Focal bulging density with clear margin at the left inferior mediastinum and T9-10 paraspinal region
- ✓ Suggestive of a posterior mediastinal lesion or neurogenic tumor



# CECT of chest

- ✓ A well-enhanced mass (about 2.2 cm in diameter and 4.8 cm in length) in left lower para-vertebral region, suggestive of posterior mediastinal tumor.
- ✓ Splenomegaly, about 14.5 cm in length



# Differential Diagnoses

- **Neurogenic tumor**
  - ✓ Ganglioneuroma
  - ✓ Schwannoma
  - ✓ Neurofibroma
- **Paraspinal metastasis**
- **Pott's disease (Tuberculous spondylitis)**
- **???**

# VATS excisional biopsy

- **Pathological diagnosis**  
Extramedullary hematopoiesis with erythroid hyperplasia

# Extramedullary hematopoiesis

- Ectopic hematopoietic response to insufficient erythropoiesis in the bone marrow
- Chronic anemic states
  - ✓  $\beta$ -thalassemia
  - ✓ Sickle cell anemia
  - ✓ Polycythemia vera etc.
- More common in spleen, liver and LNs
- May present as **posterior mediastinal masses** (Bilateral > Unilateral)



# Extramedullary hematopoiesis

