

CASE 3

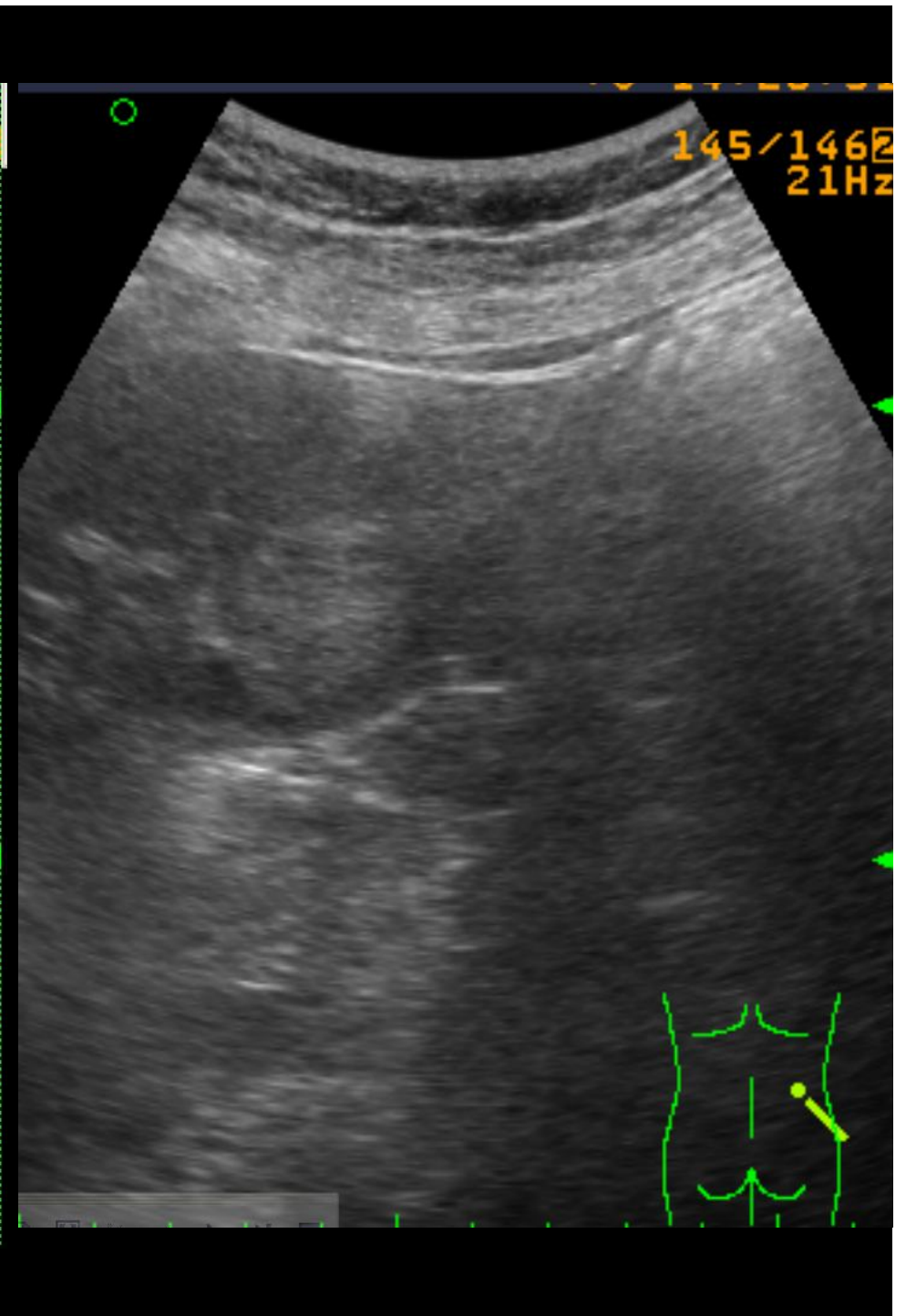
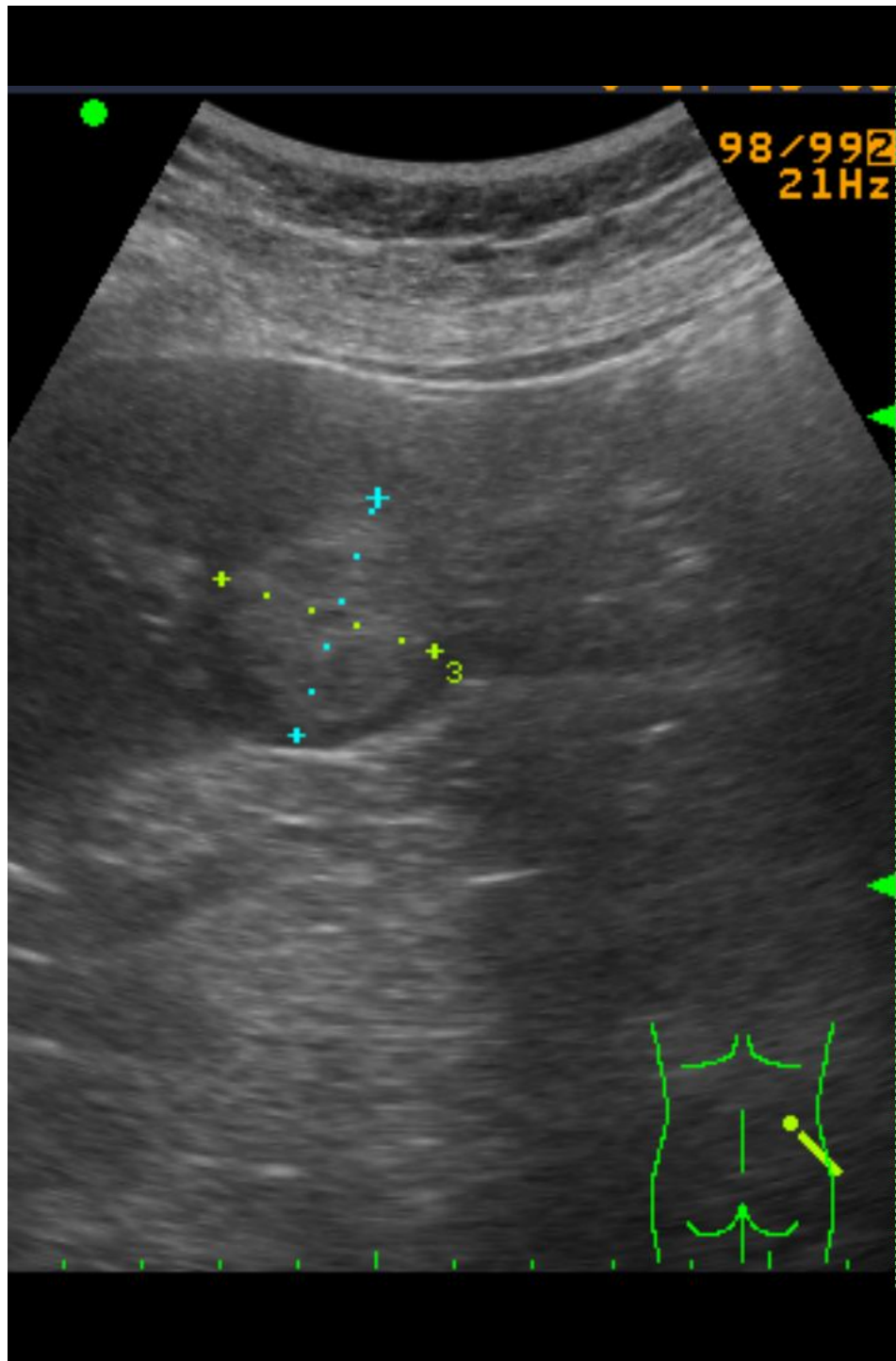
52 Y/O WOMAN

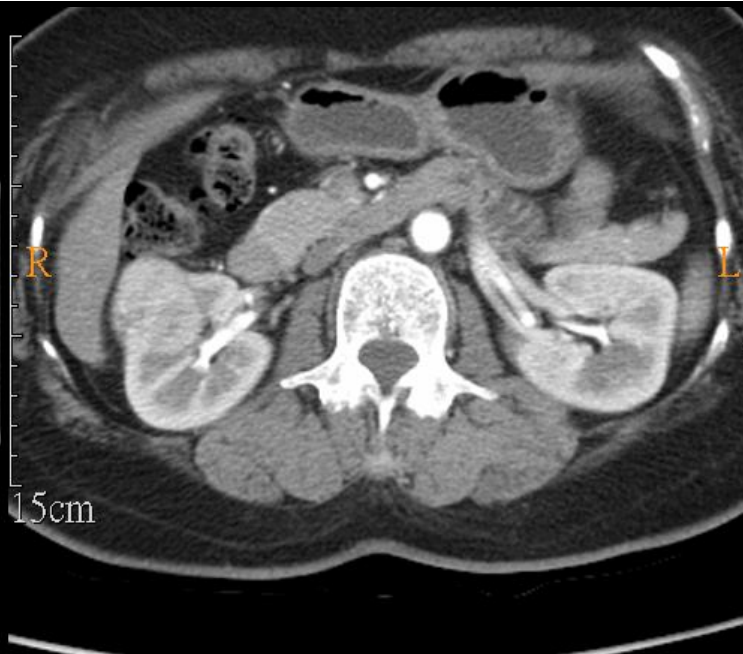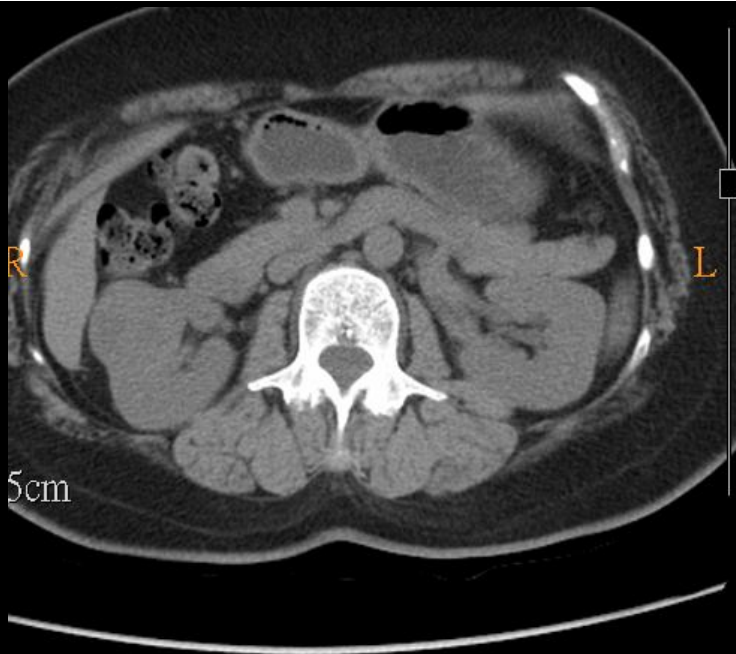Brief history

- 52 years old woman
- PHx: HBV carrier
- Chief complain :
 - Right renal mass accidentally found during abdominal ultrasound exam at other hospital.

Imaging study

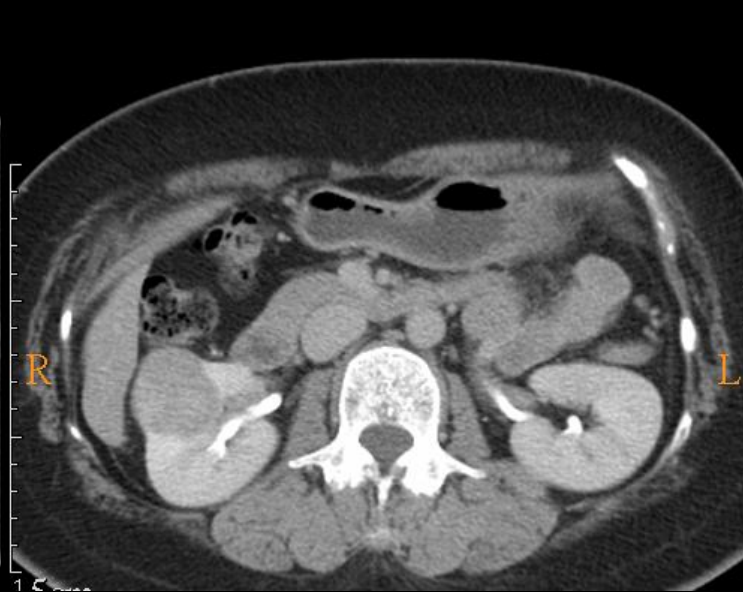
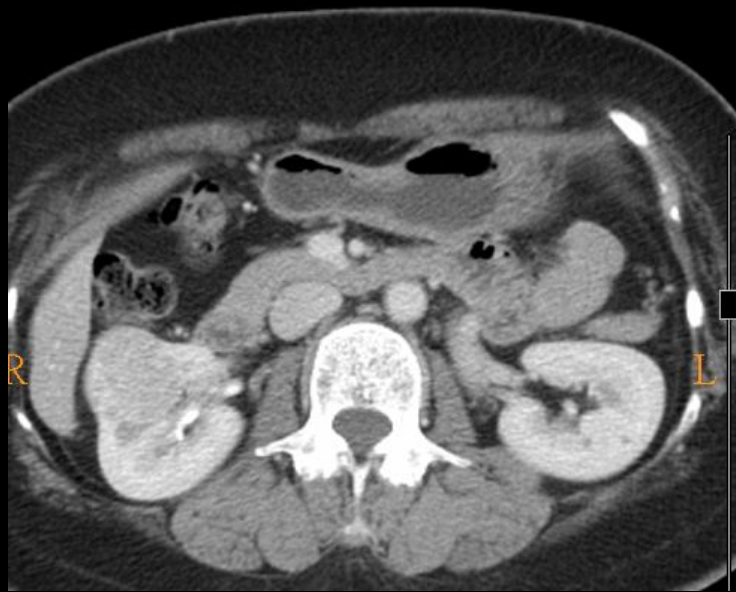- sonography
- abdominal CT





P
A 10cm

P
A 10cm

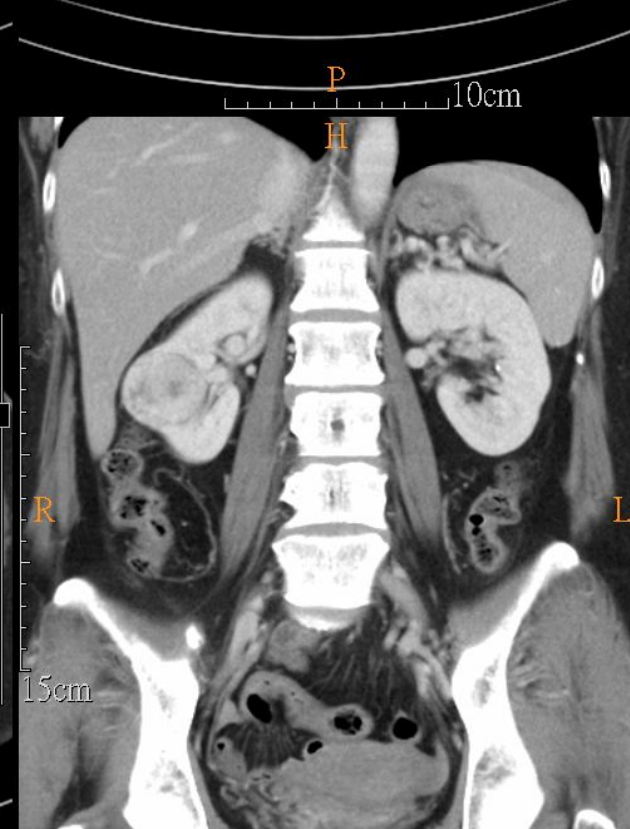
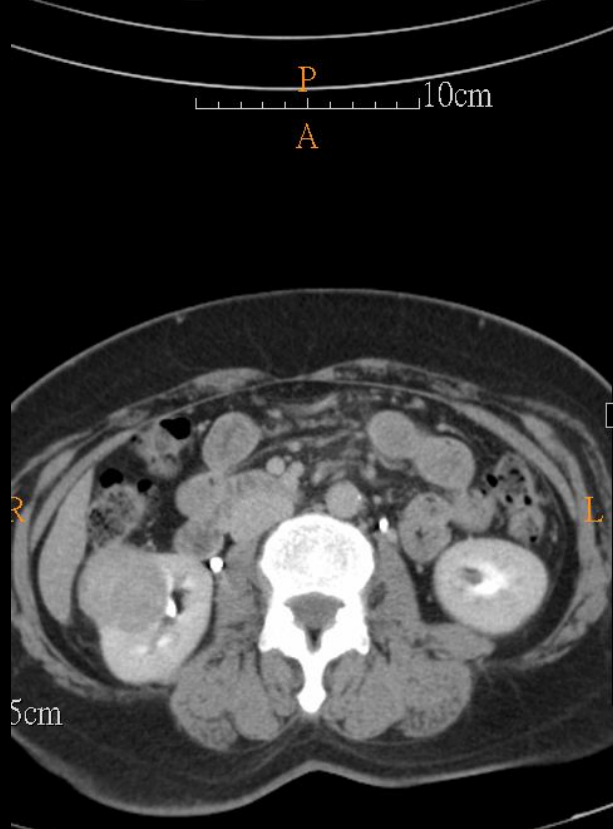
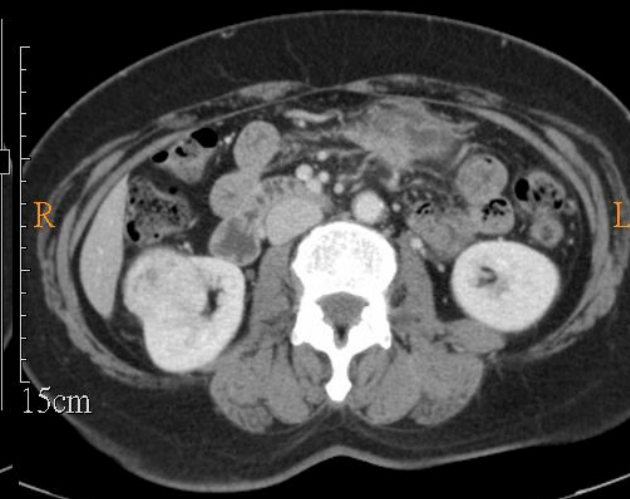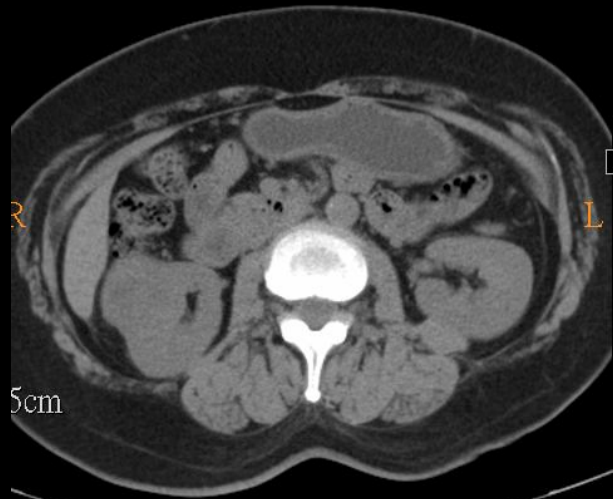


15cm

DDx:

- Renal cell carcinoma (RCC)
- Transitional Cell Carcinoma
- Renal Metastases
- Lymphoma
- **Oncocytoma**

1 year follow



- END