

CASE 3

14 M/O BOY

Brief history

- **Past history**

Denied

- **Chief complain**

Bleeding from right ear twice in two days

Imaging studies

H&N CT (no C) (2015.01.06)

Brain MRI (+ C) (2015.01.30)

Imaging findings

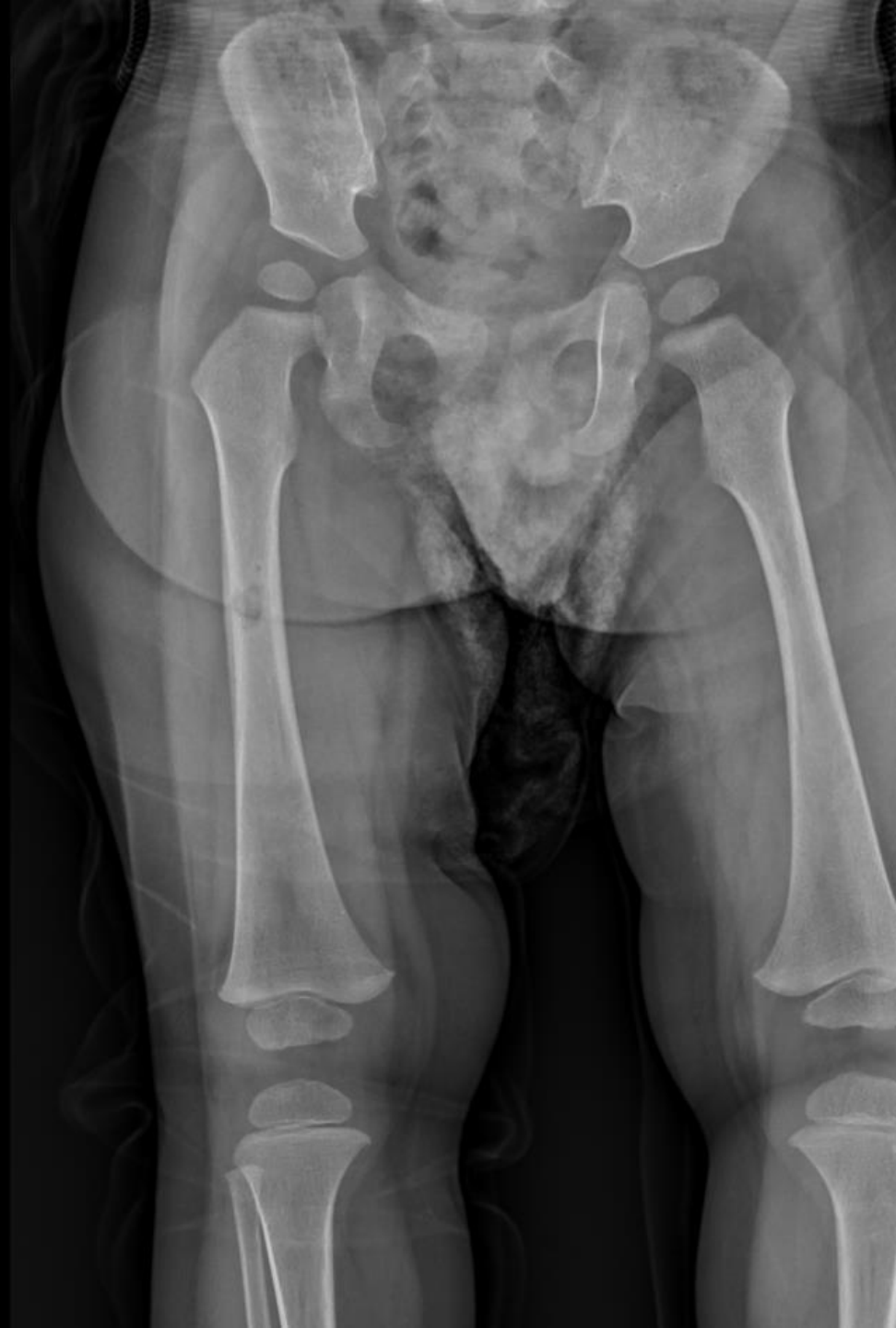✓ CT :

- **Large soft tissue masses** over the right pre-auricular and temporal region with adjacent bone destruction
- **Right external auditory canal filled with soft tissue** and is poorly recognized

• MRI :

- **Two enhancing & expansile bony soft tissue masses** in the right anterior mastoid and temporal bones & left sphenoid body
- **Enlarged lymph nodes in bilateral upper neck** in the jugulodigastric chains at **level IIb**

Imaging findings



Differential Diagnoses

- Langerhan's cell histiocytosis
(Hand-Schuller Christian's disease)

→ Pathology report

Langerhan's cell histiocytosis

Hand-Schüller-Christian Disease

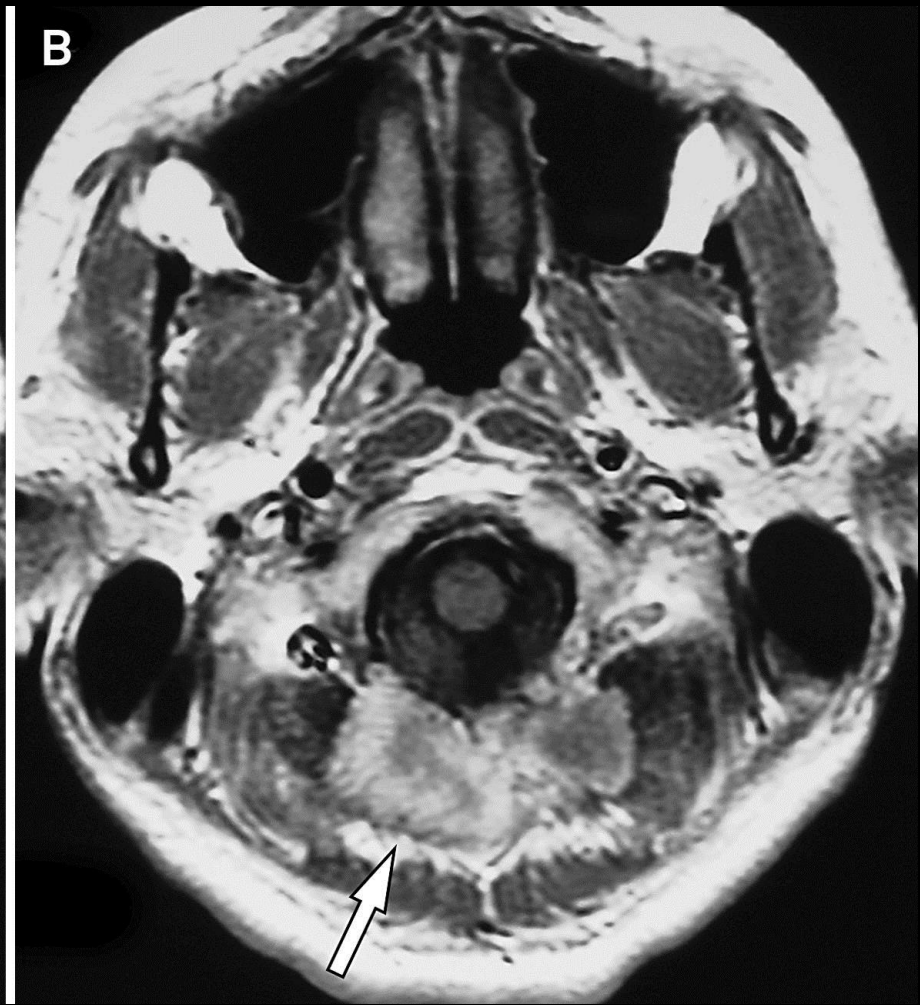
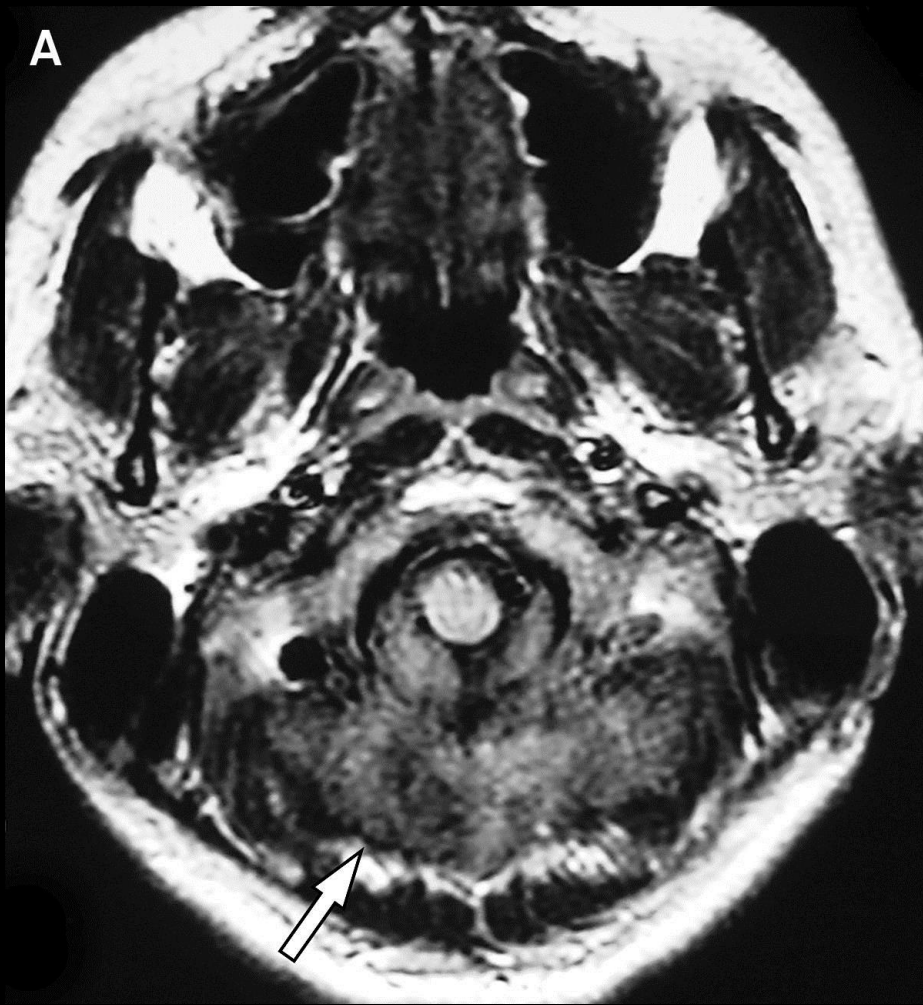- **Chronic multifocal Langerhans cell histiocytosis**
- **Dysregulated proliferation of Langerhans cells** and subsequent multifocal, chronic organ involvement
- **Genetic mutation in the MAPKinase pathway** that occurs during early development
- One of four types of **Langerhans cell histiocytosis (LCH)** :
 - Eosinophilic granuloma
 - Congenital self-healing reticulohistiocytosis
 - Hand-Schüller-Christian disease
 - Letterer-Siwe disease
- **Proptosis, lytic bone lesions, diabetes insipidus**

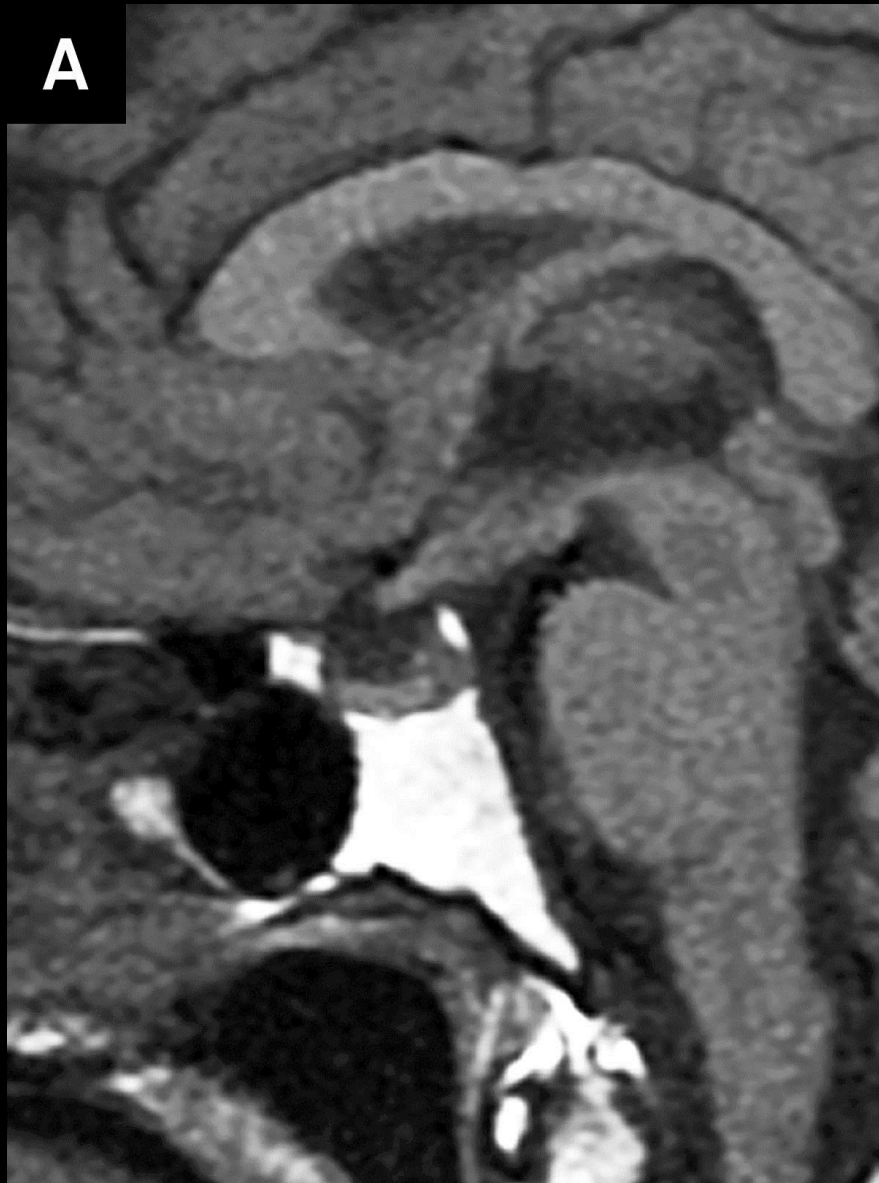
Hand-Schüller-Christian Disease

- **Chronic multifocal Langerhans cell histiocytosis**
- **Dysregulated proliferation of Langerhans cells** and subsequent multifocal, chronic organ involvement
- **Genetic mutation in the MAPKinase pathway** that occurs during early development
- One of four types of **Langerhans cell histiocytosis (LCH)** :
 - Eosinophilic granuloma
 - Congenital self-healing reticulohistiocytosis
 - Hand-Schüller-Christian disease
 - Letterer-Siwe disease
- **Proptosis, lytic bone lesions, diabetes insipidus**

Hand-Schüller-Christian Disease

- **Wide spectrum of cranial and intracranial findings :**
 - **osseous lesions** in the craniofacial bones and/or skull base with or without soft-tissue extension
 - **intracranial, extra-axial changes** (involvement of hypothalamic-pituitary region, meninges, and other circumventricular organs, including the pineal gland, choroid plexus, and ependyma)
 - **intra-axial parenchymal changes** (white matter and gray matter)
 - **cerebral atrophy**



A**B**