

CASE 5

6 Y/O BOY

Brief history

- **Past history**

Facial asymmetry and plagiocephaly

- **Chief complain**

Asymmetrical head position

Imaging studies

Cervical plain films (2020.06.15)

C-spine CT (no C) (2020.06.12)

C-spine MRI (no C) (2020.06.15)

Imaging findings

✓ Radiographs :

- **Suspect C1-C2 instability**

• MRI :

- **Increased atlantodens interval** with minimal joint effusion collection
- **Abnormal fusion of atlas and occipital skull** (more on R't side)
- - **Rotational subluxation**

Differential Diagnoses

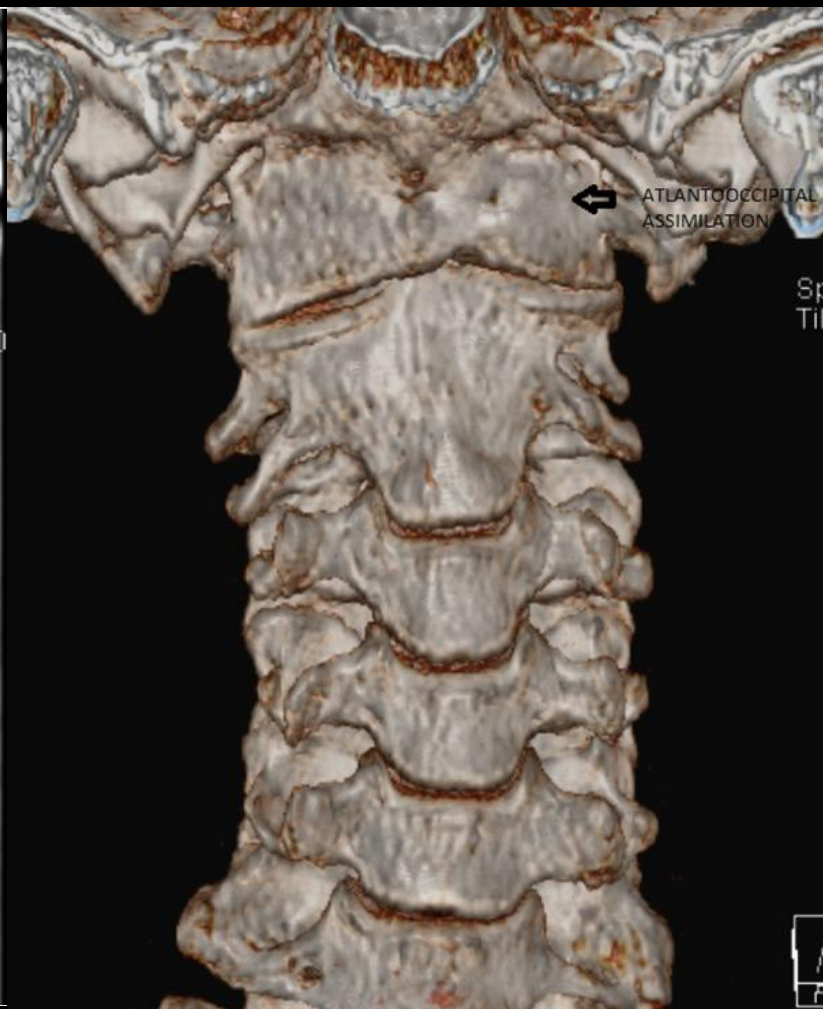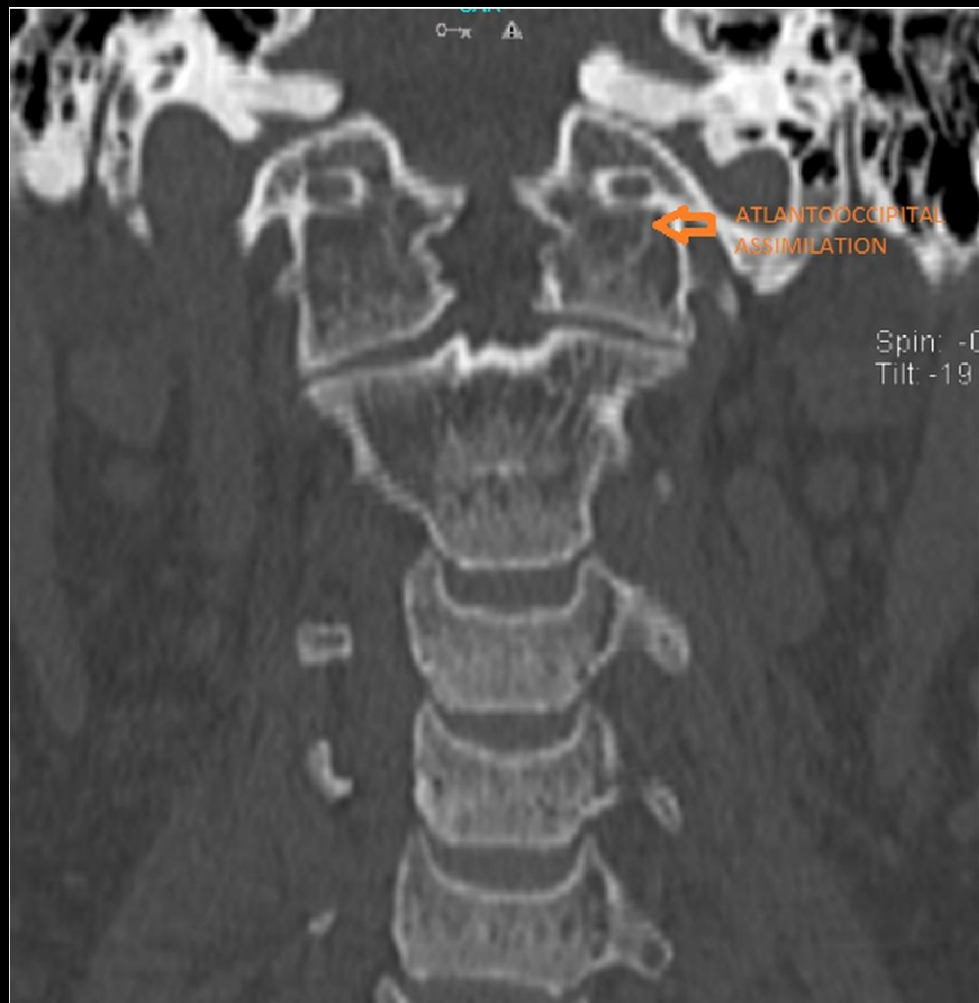
Incomplete atlanto-occipital assimilation

Atlanto-occipital assimilation

- Fusion of the atlas (C1) to the occiput
- One of the most common osseous anomalies observed at the craniocervical junction
- **Complete:** C1 not identifiable
- **Incomplete:** C1 partially identifiable
- Other findings :
 - **Fusion of C2 and C3** (occurs in 50% of cases)
 - **basilar invagination: type 1**
 - **cleft palate**
 - **cervical ribs**

Atlanto-occipital assimilation

- **Fusion of the atlas (C1) to the occiput**
- **One of the most common osseous anomalies** observed at the craniocervical junction
- **Complete:** C1 not identifiable
- **Incomplete:** C1 partially identifiable
- Other findings :
 - **Fusion of C2 and C3 (occurs in 50% of cases)**
 - **basilar invagination: type 1**
 - **cleft palate**
 - **cervical ribs**



Thank you for your attention