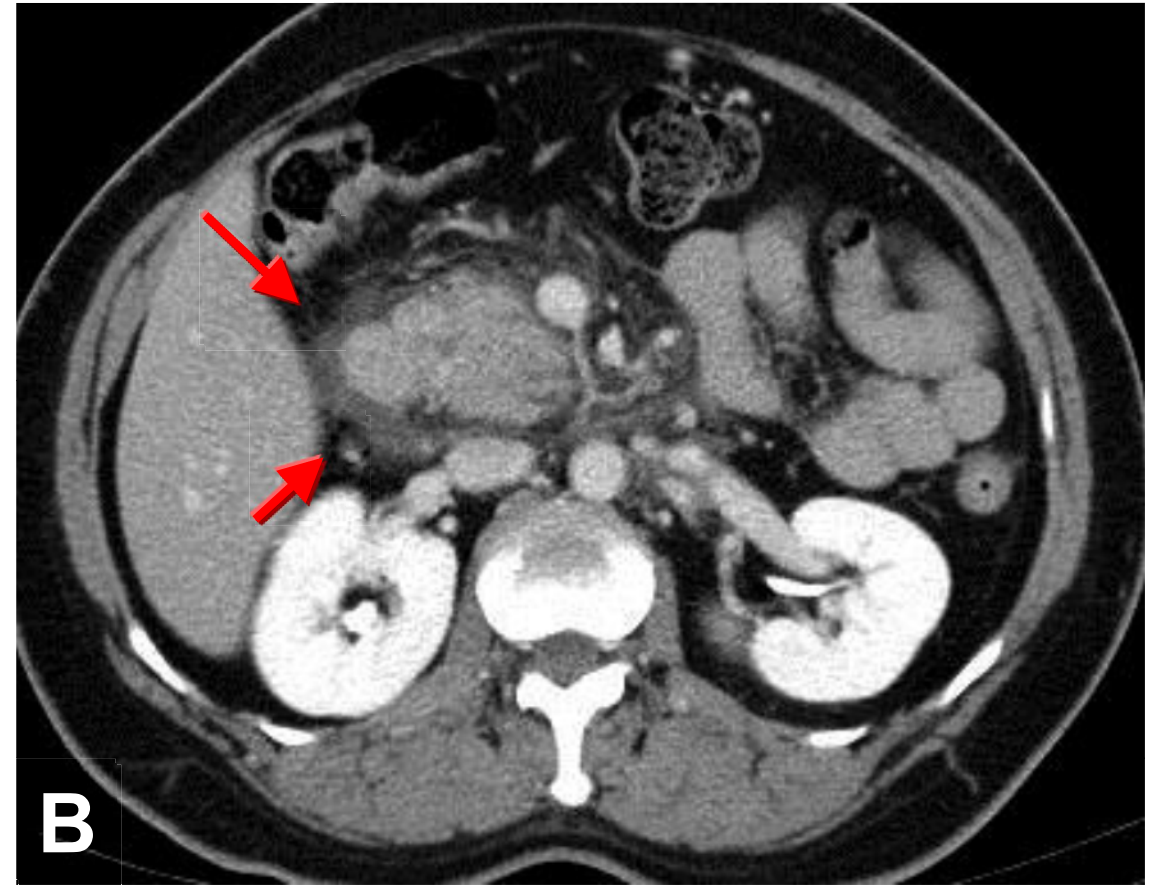
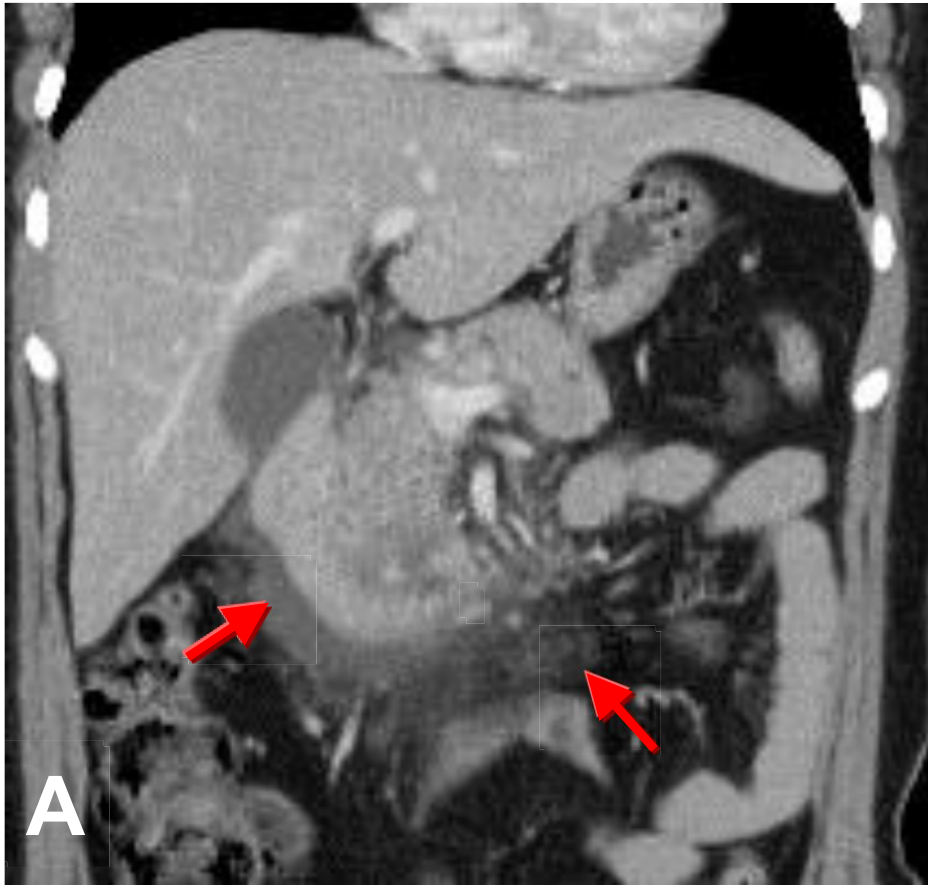

Acute pancreatitis



Axial (A) & coronal (B) enhanced upper abdominal CT shows Acute pancreatitis presenting with swelling of pancreas with peripancreatic fluid accumulation (arrows in A & B) causing adynamic ileus of duodenum (sentinal loop).