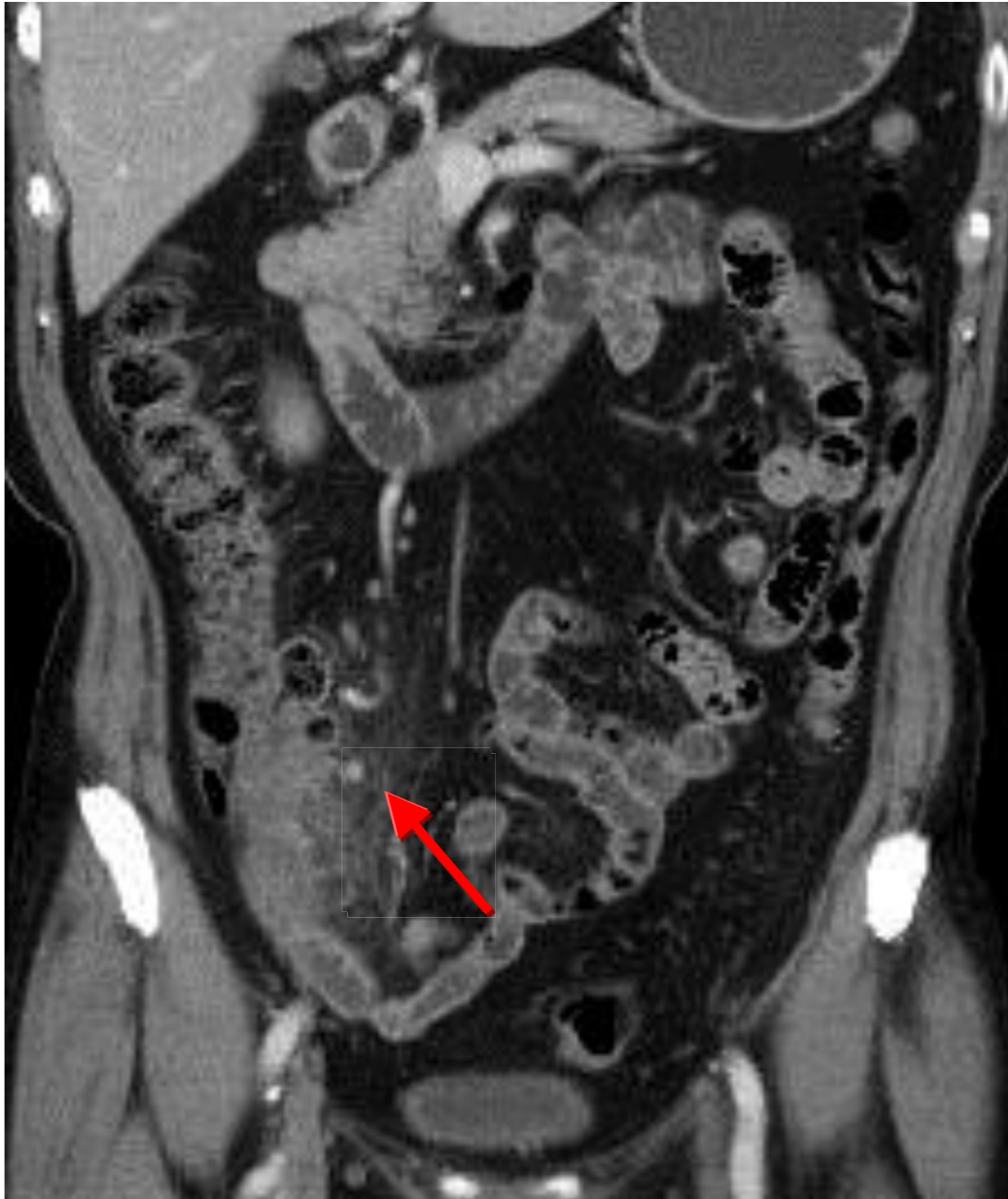


Diverticulitis



Several diverticula in cecum with dirty fat in pericecal region(arrow)

Diverticulitis results from macroperforation of the bowel within the diverticulum.

Patients with diverticulitis are initially managed with broad spectrum antibiotics, nasogastric suction if ileus or obstruction are present, and fluid replacement if the patient does not respond to conservative medical management or if complications such as intraabdominal or pelvic abscess occur surgical intervention may be necessary.