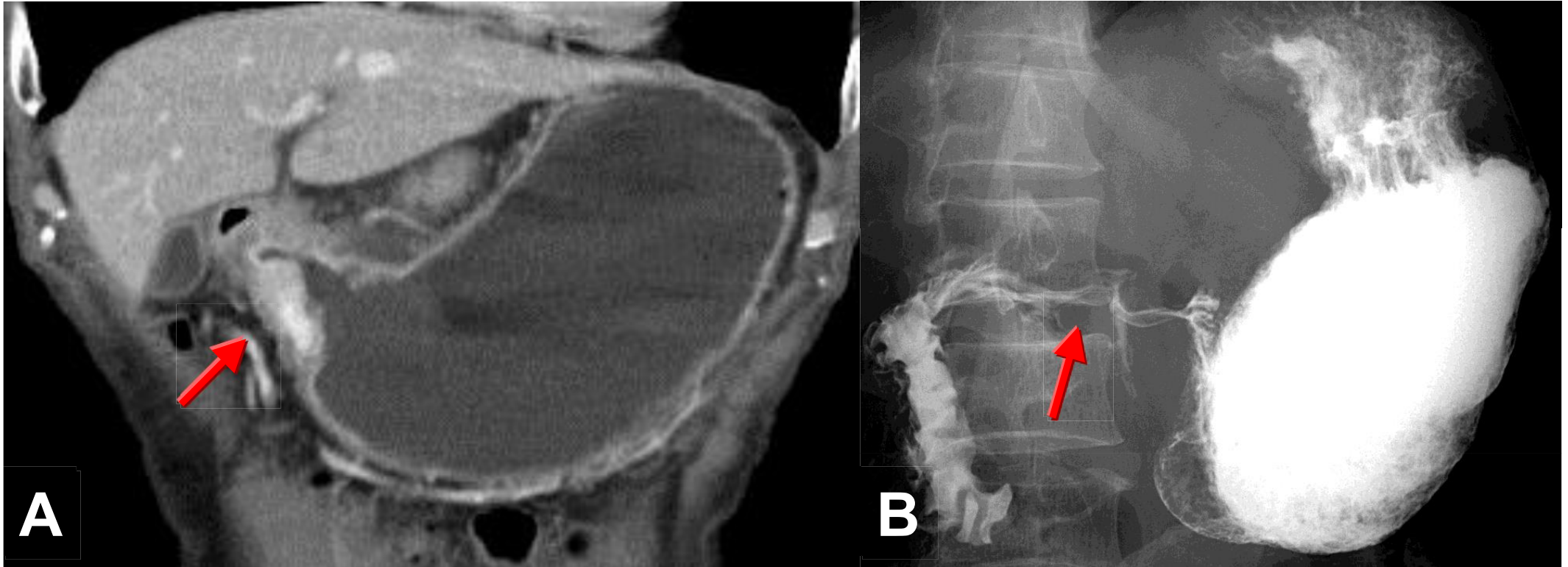


Gastric outlet obstruction



Gastric outlet obstruction could be due to mechanical origin such as peptic ulcer with scar, neoplasm or foreign bodies or functioning origin such as aging process. An annular mass in antrum of stomach is shown on CT with well enhancement (arrow in A) & a long segment of irregular stenosis in antrum of stomach on UGI Barium study(arrow in B).