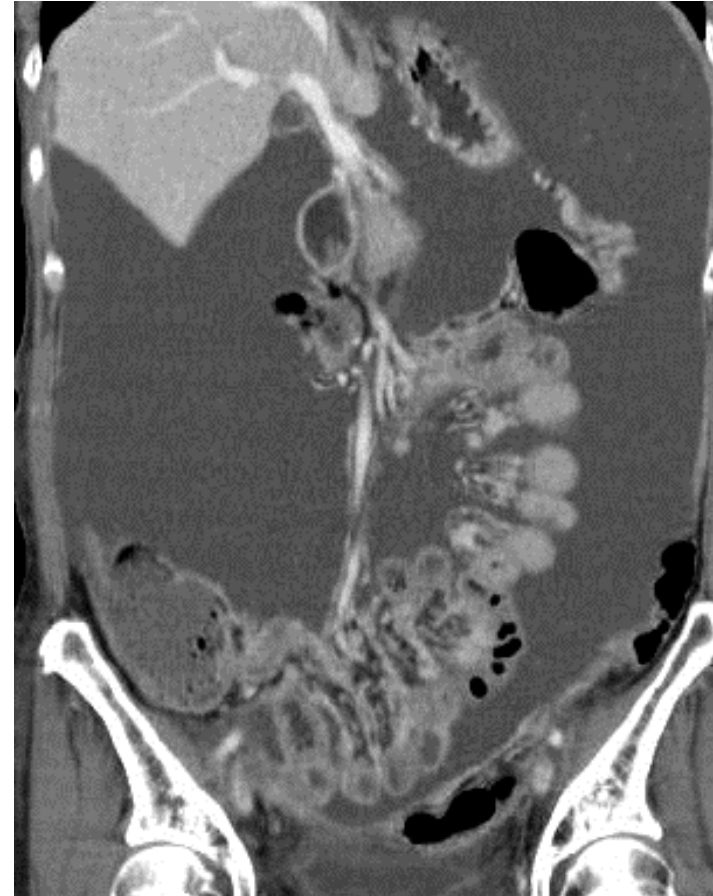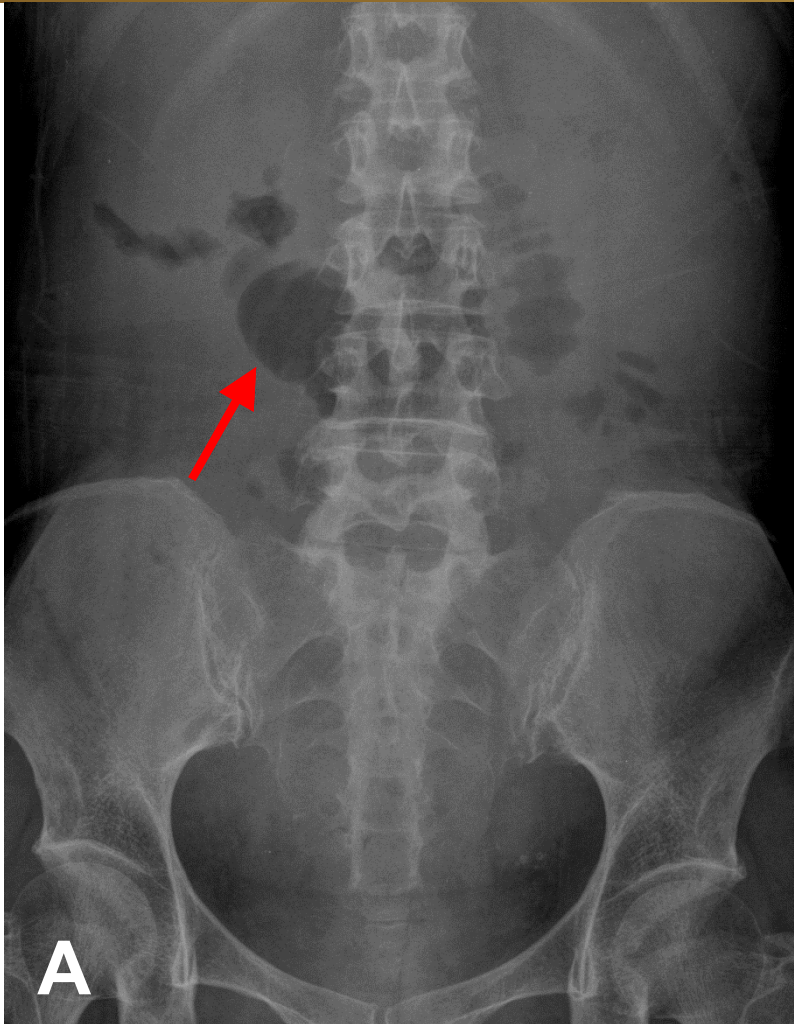


Liver cirrhosis with ascites



Generalised hazy density of the entire abdomen & pelvis with loss of all landmarks in plain abdomen, & centrally floating several dilated loops of bowel gas (arrow in A), small liver with massive ascites showed on CT(B) due to liver cirrhosis with portal hypertension