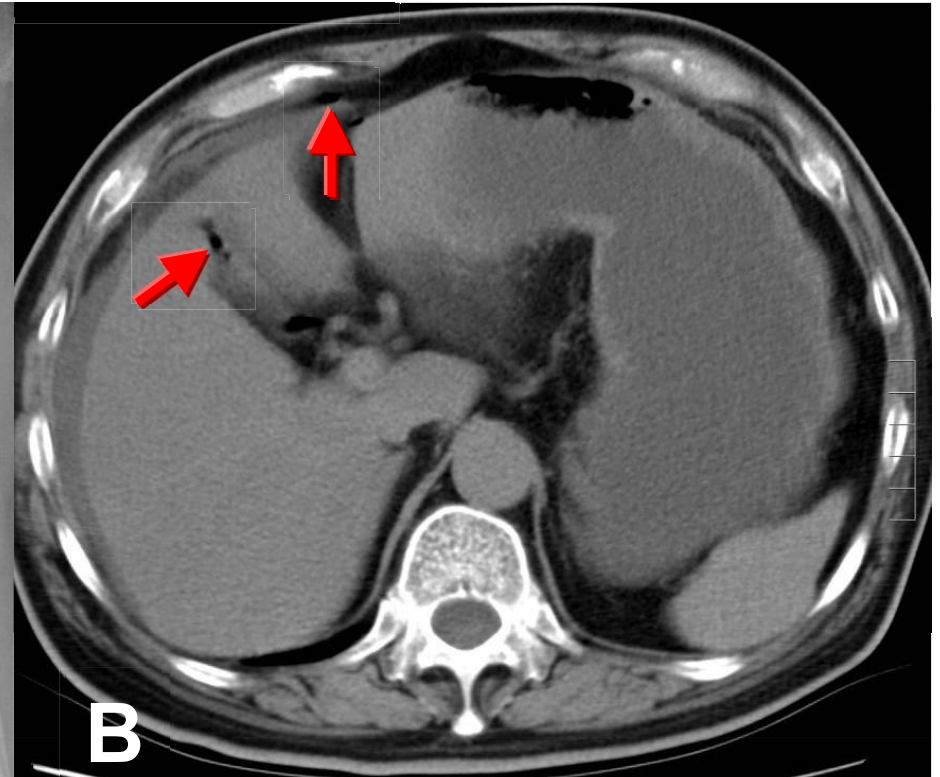
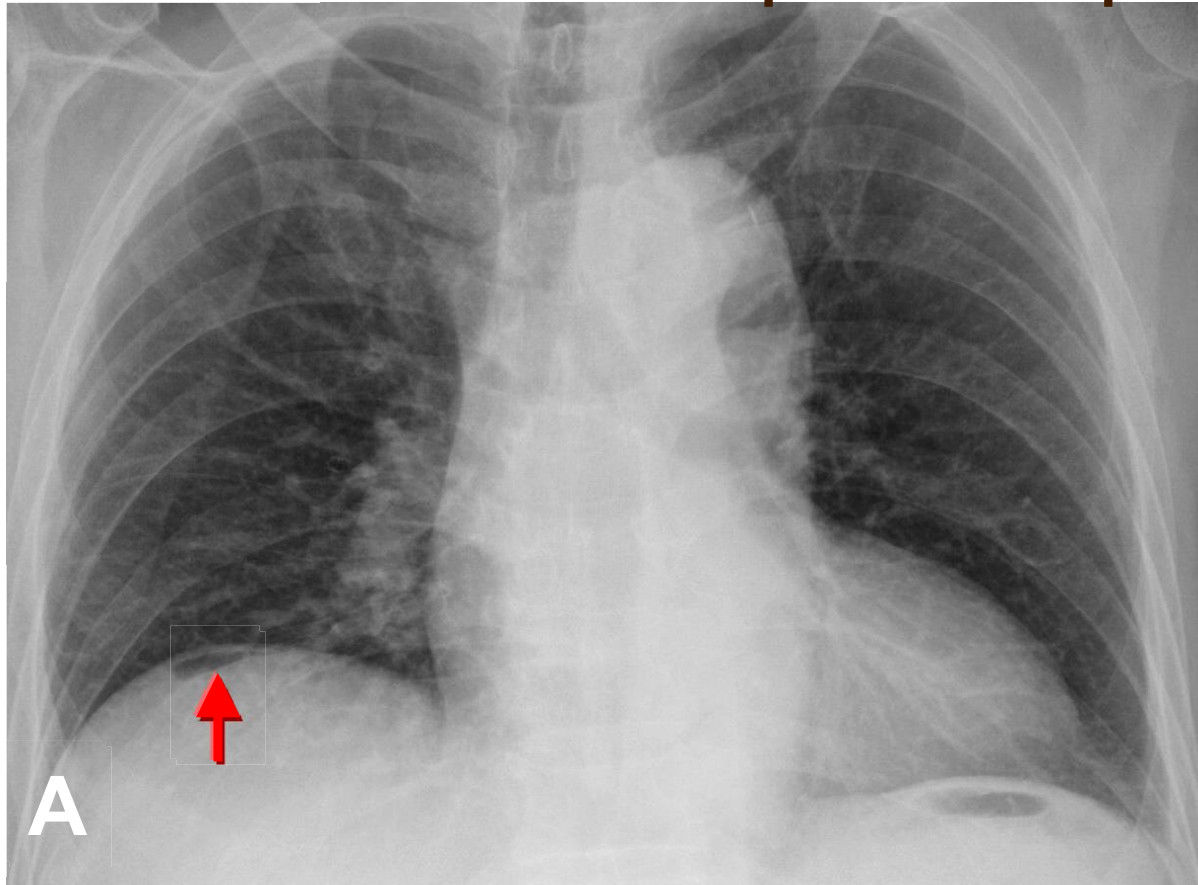


PPU with pneumoperitoneum



The pneumoperitoneum refers to the presence of air within the peritoneal cavity. The most common cause is GI tract perforation including a perforated ulcer, a tumor or trauma. The free air (**dome sign**) located right subphrenic region (arrow in A) is more well demonstration by CXR than standing abdominal radiography. CT is the most sensitive imaging modality for demonstration of the free air (arrows in B).