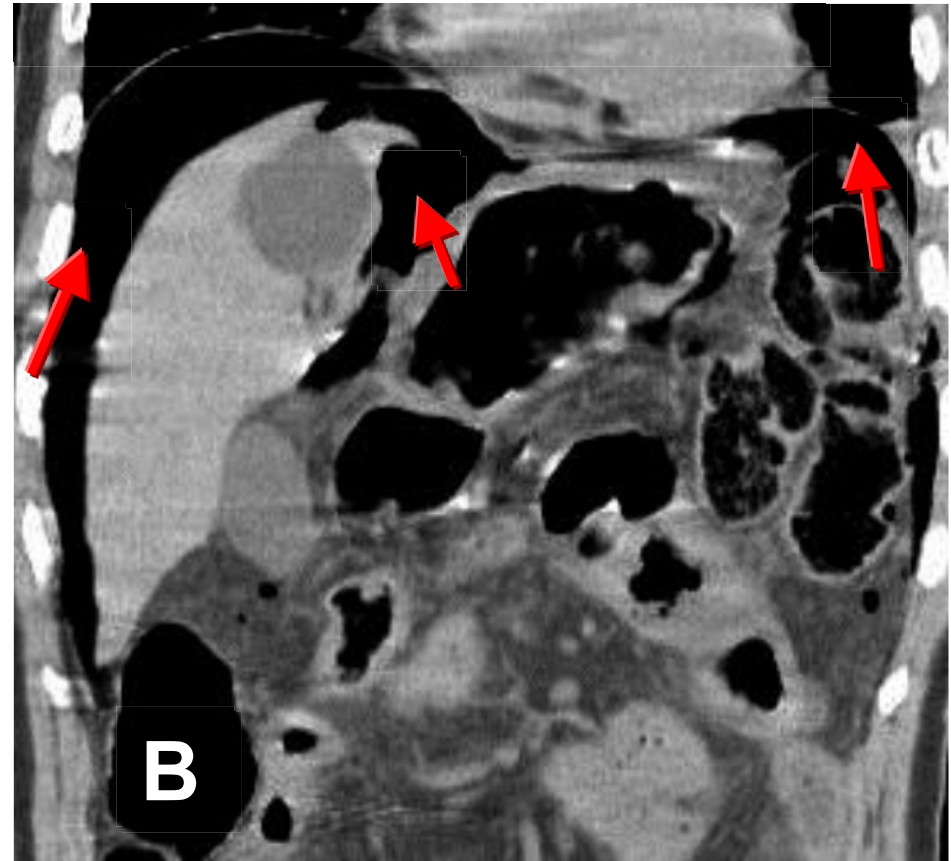
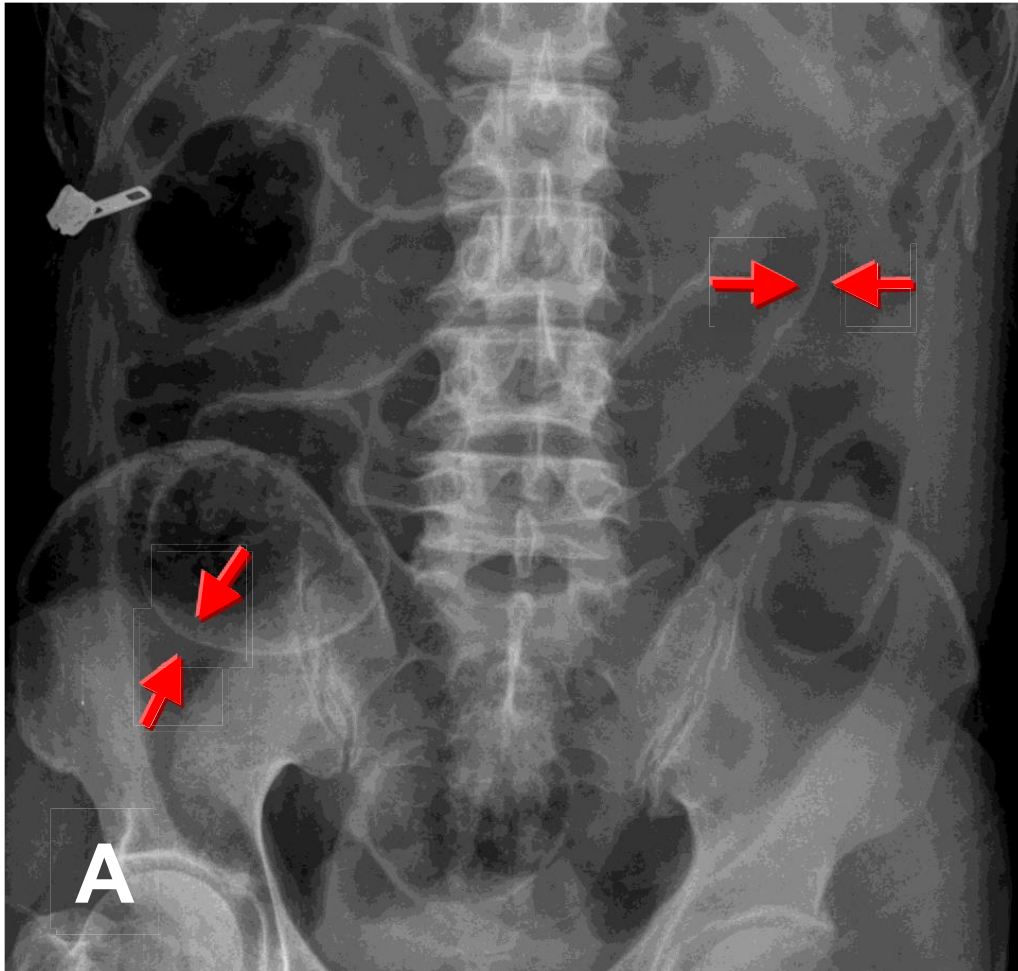


Free air with regler's sign



The Rigler's sign, also known as the double wall sign, is seen on an plain abdomen when air is present on both sides of the intestine i.e. air on both the luminal and peritoneal side of the bowel wall (arrow in A) indicating Pneumoperitoneum. CT showed free air in subphrenic regions (arrow in B)