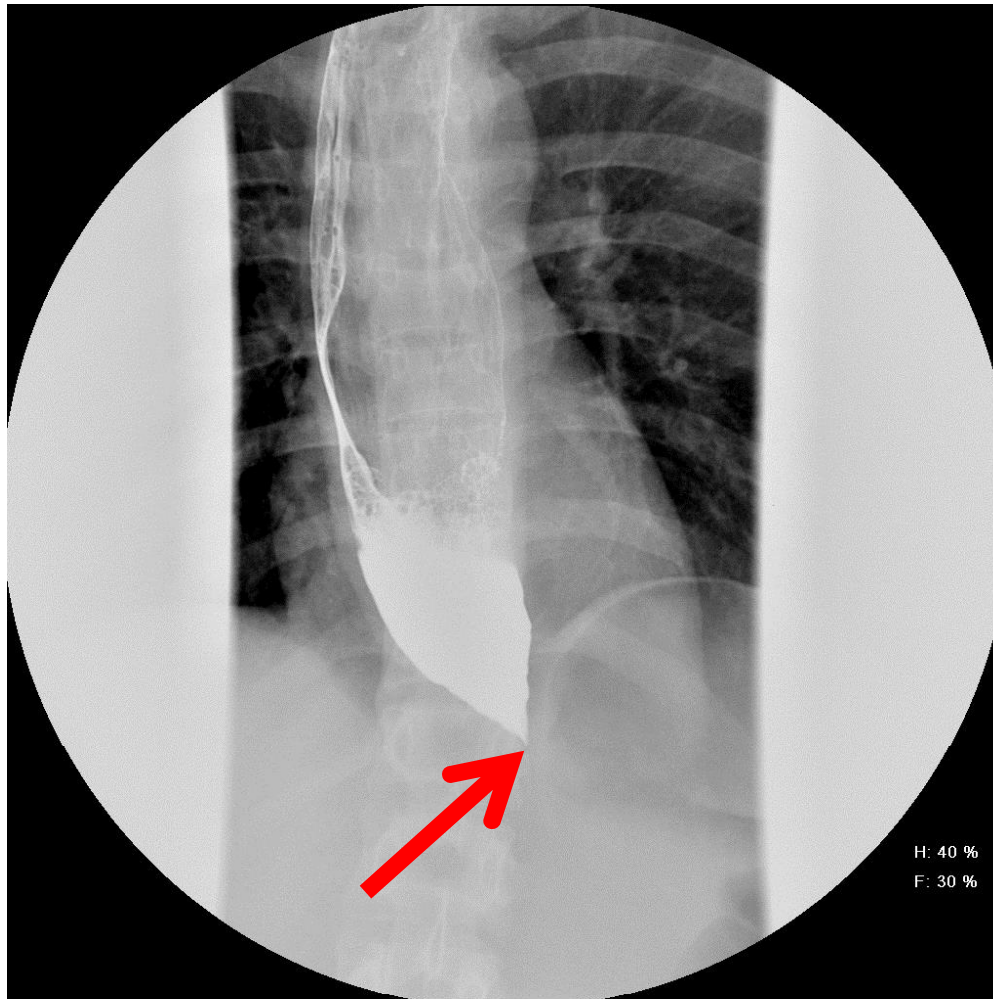


Achalasia



Achalasia is an uncommon swallowing disorder. In achalasia, nerve cells in the esophagus degenerate. The lower esophageal sphincter does not function correctly. Characteristic findings of achalasia on barium swallow include a persistently narrowed region at the end of the esophagus with proximal dilatation of esophagus (Bird beak sign, arrow).