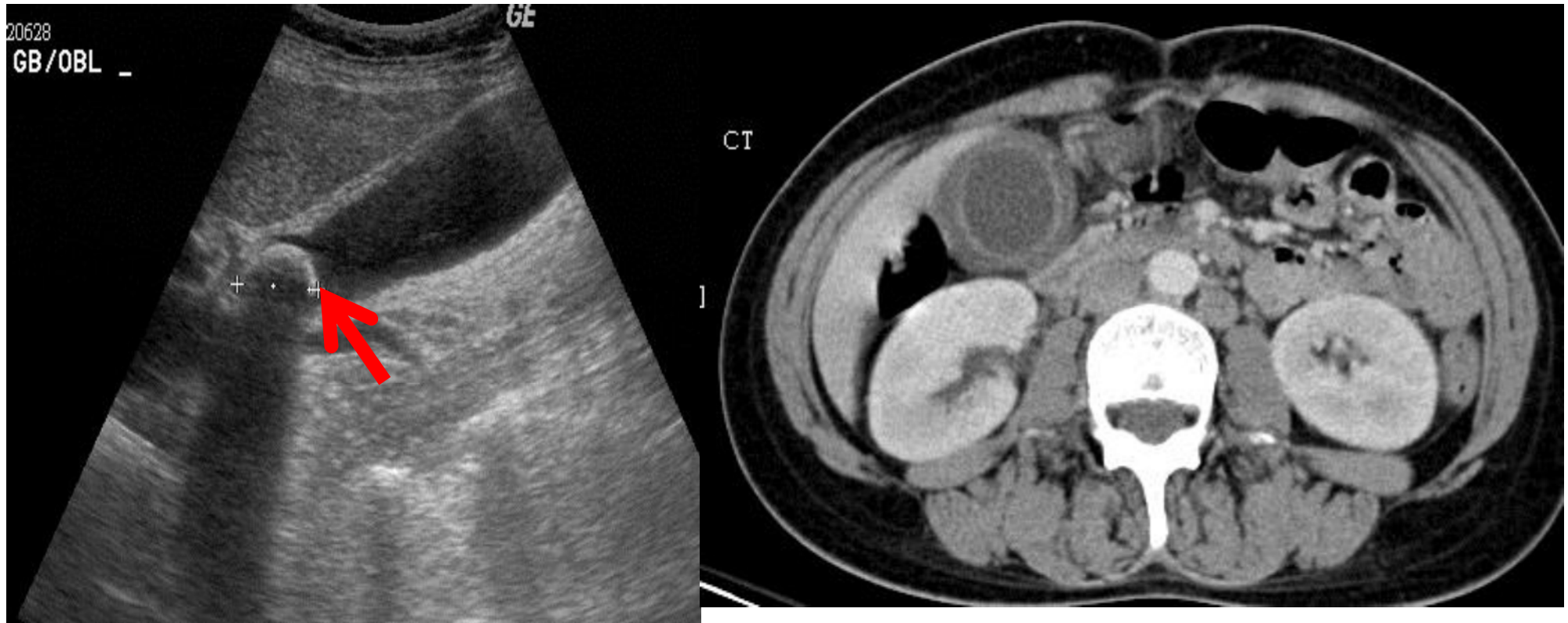


Gallstone with acute cholecystitis



Sonogram shows GB dilatation(>4cm), GB wall thickening(>3mm), Gallstone with posterior shadowing(arrow**), with positive Murphy sign. CT shows wall enhancement with edema. C/W acute cholecystitis.**