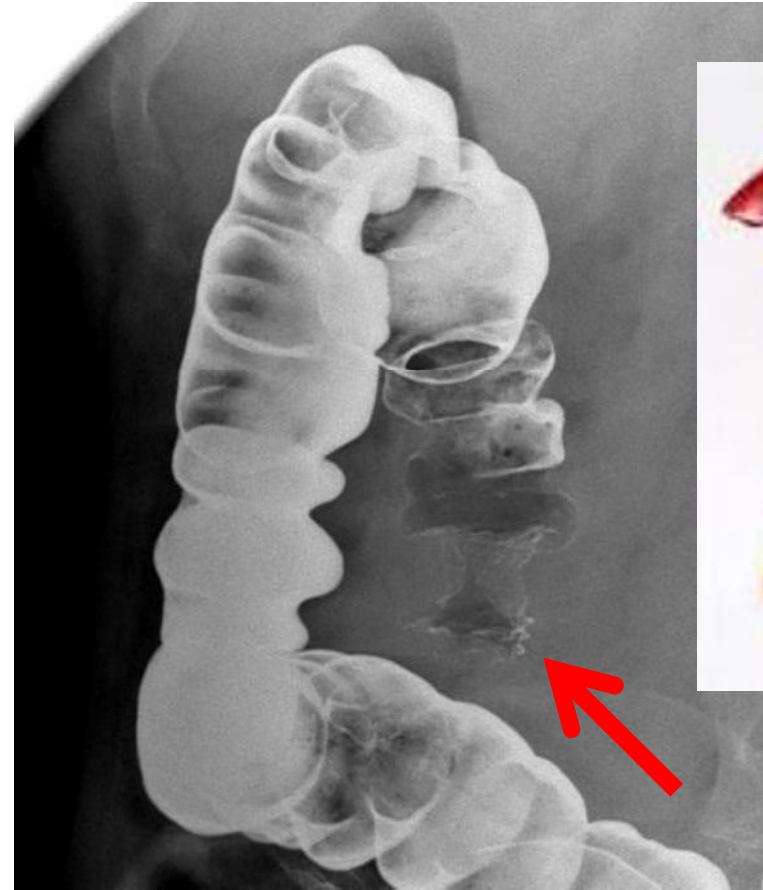
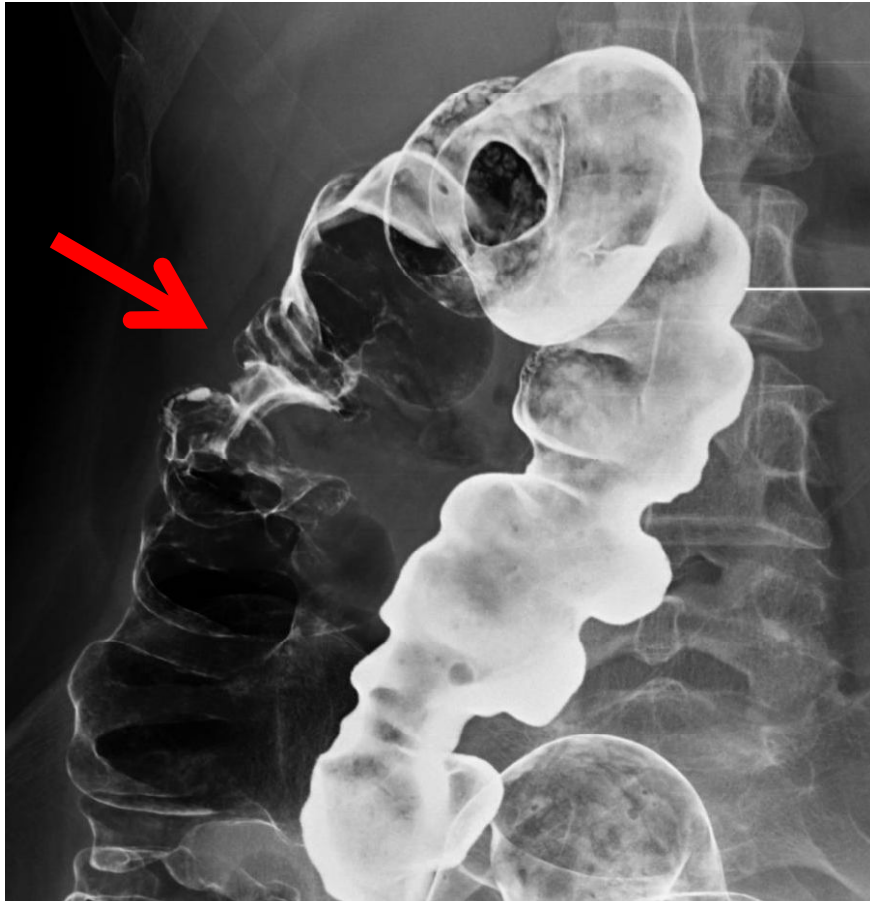

Ascending colon cancer



An **apple core sign** is most frequently associated with constriction of the lumen of the colon by a stenosing annular colorectal carcinoma.