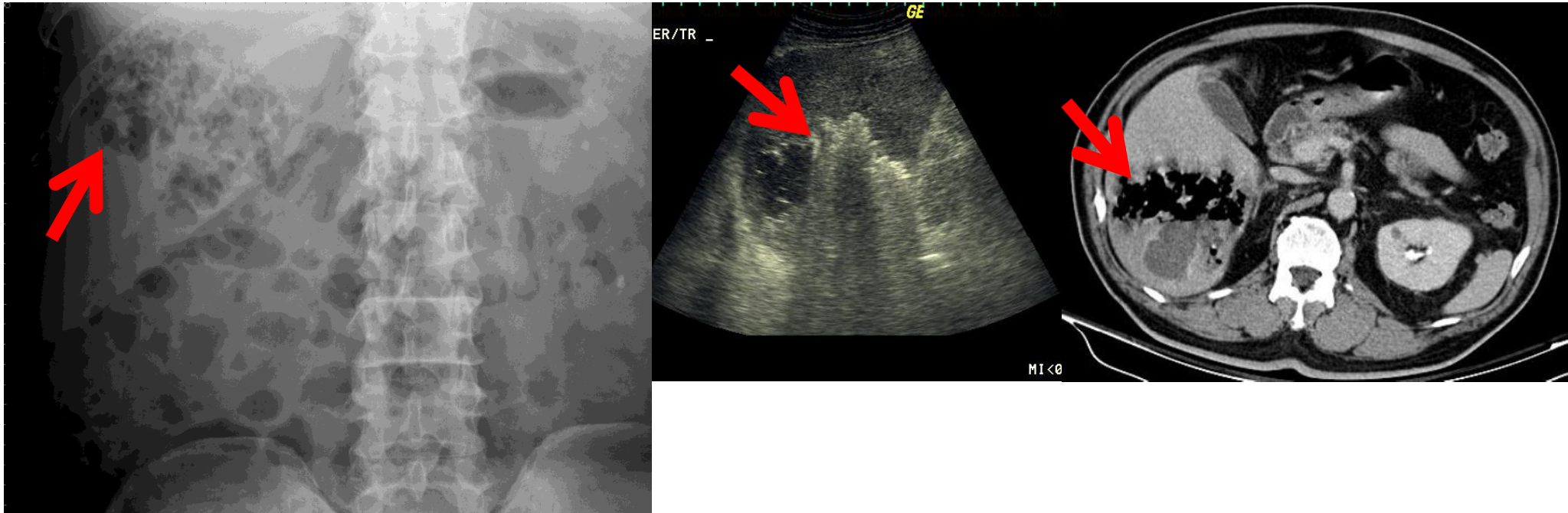


Gas forming liver abscess



Gas-forming liver abscess is associated with a high mortality rate and is commonly associated with DM and K.P.. Carefully look the RUQ gas in KUB, which shows high echogenicity with **dirty shadows at sonogram and very low density at CT.**