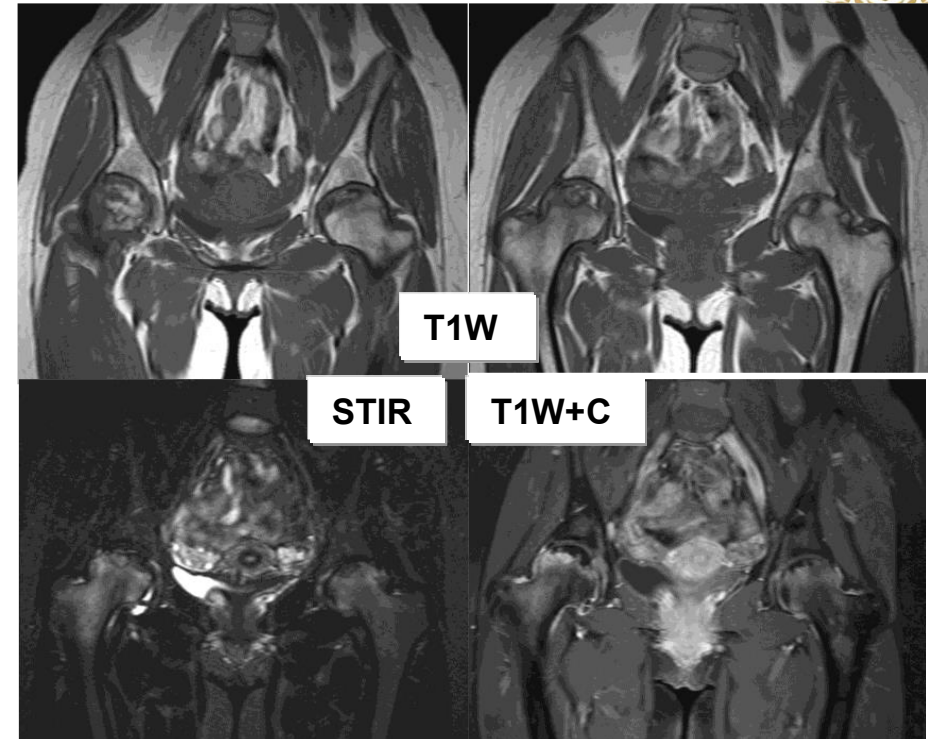
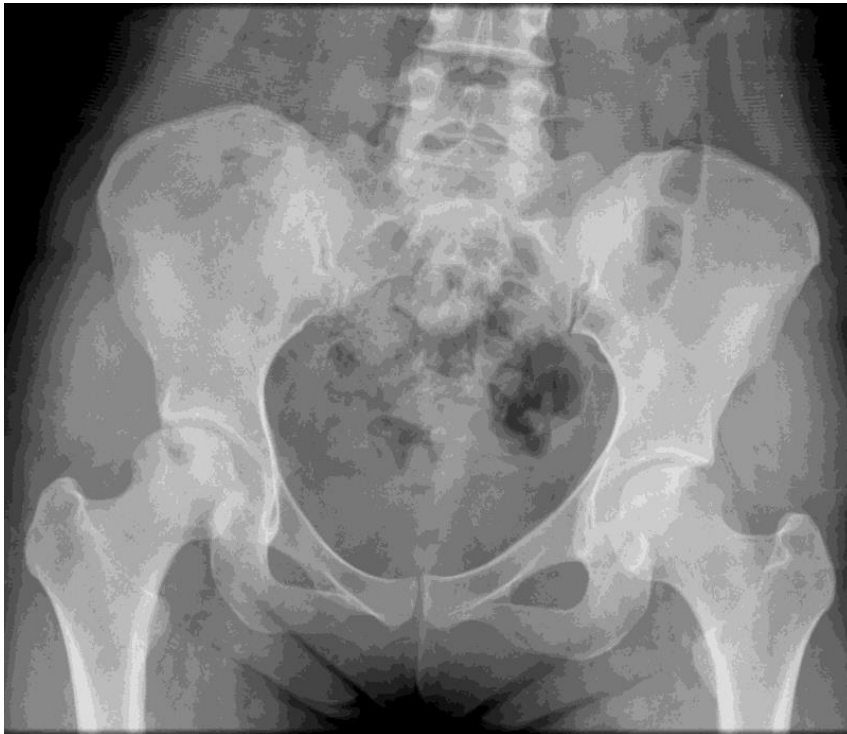

## Answer: Femoral head avascular necrosis



**Ficat classification**, combination on pain film, MRI

**stage 0** X-ray : normal

MRI : normal

**stage I** X-ray : normal or minor osteopaenia

MRI : edema

Bone scan : increased uptake

**stage II** X-ray : mixed osteopenia &/or sclerosis &/or subchondral cysts

MRI : geographic defect

Bone scan : increased uptake

**stage III** X-ray : crescent sign (subchondral lucency) & eventual cortical collapse

MRI : same as X-ray

**stage IV** X-ray : end stage with evidence of secondary degenerative change

MRI : same as X-ray