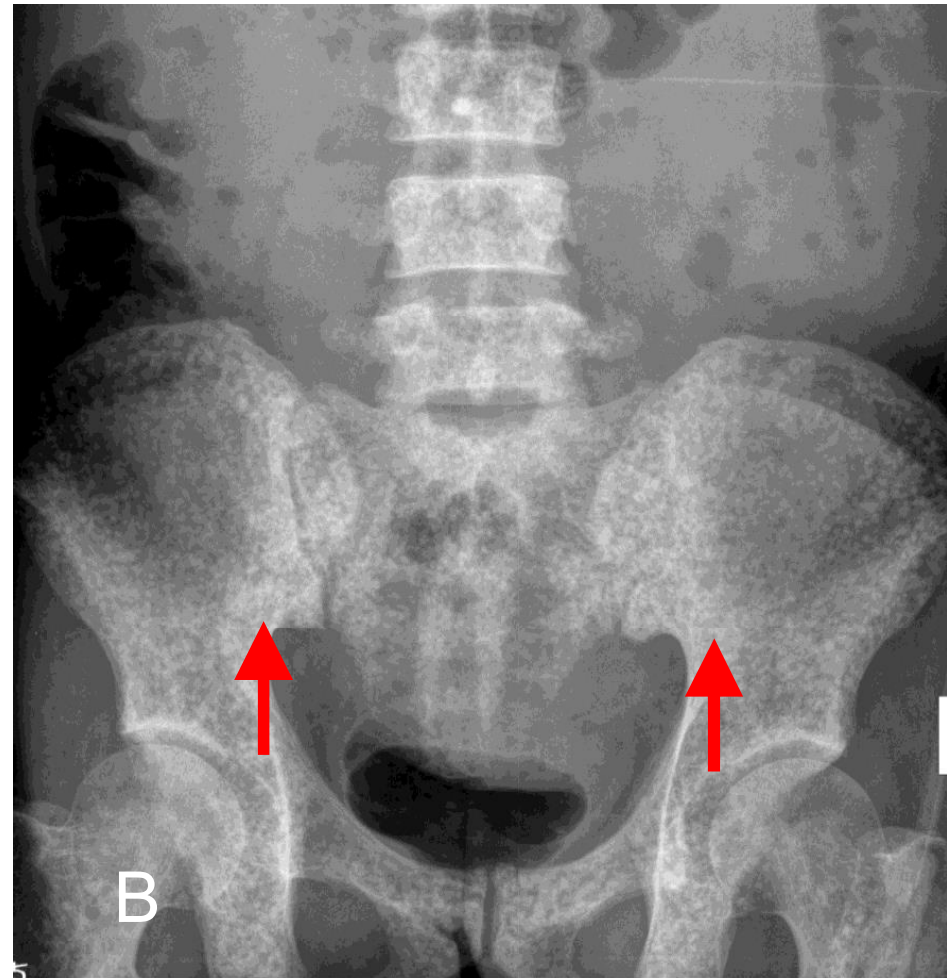
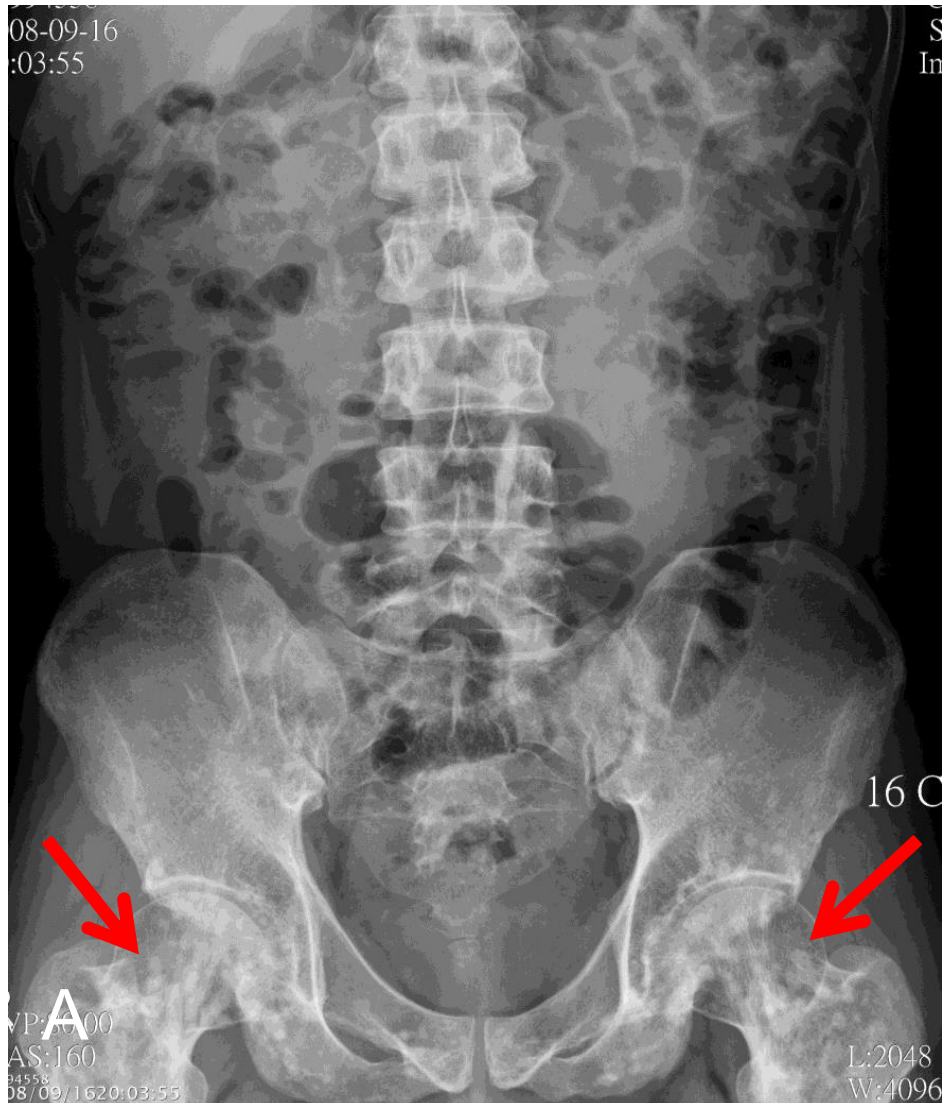


Answer: Osteopoikilosis



Osteopoikilosis is a benign, characterized by the presence of numerous bone islands in the skeleton (arrows in A). ranging from only 1- 2mm up to 1 - 2cm. It must be differentiated with osteoblastic metastasis that presenting with variant sized osteoblastic foci in more aged group (arrows in B).