

# Bonus Case

# Patient Profile

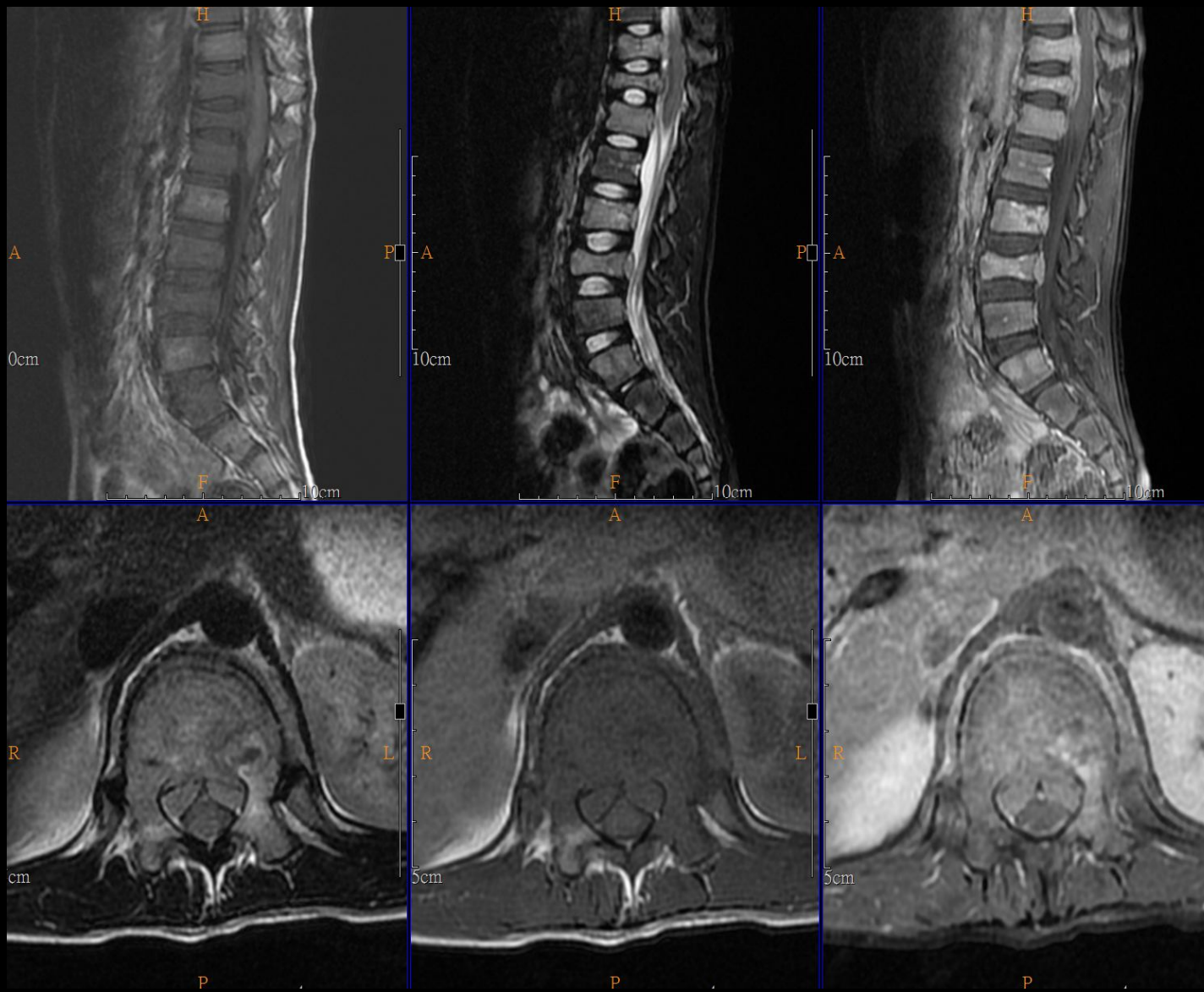
---

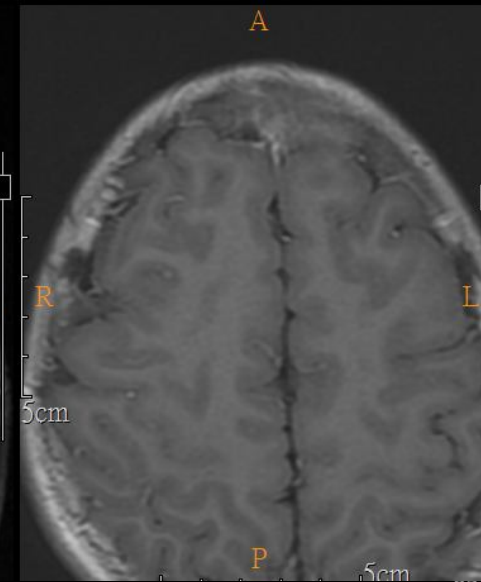
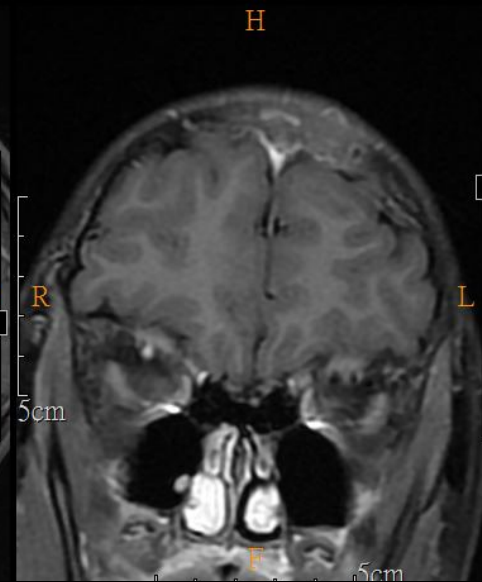
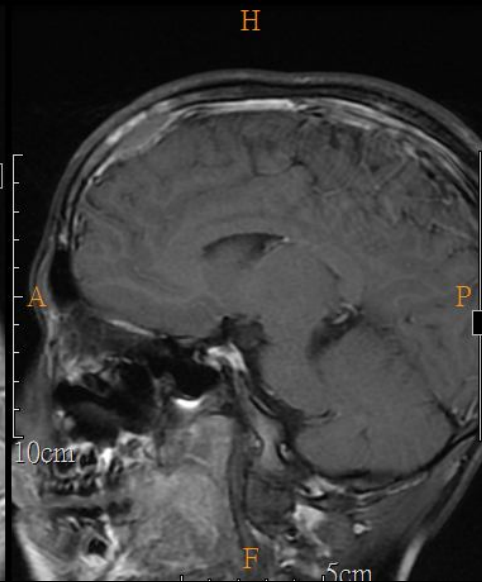
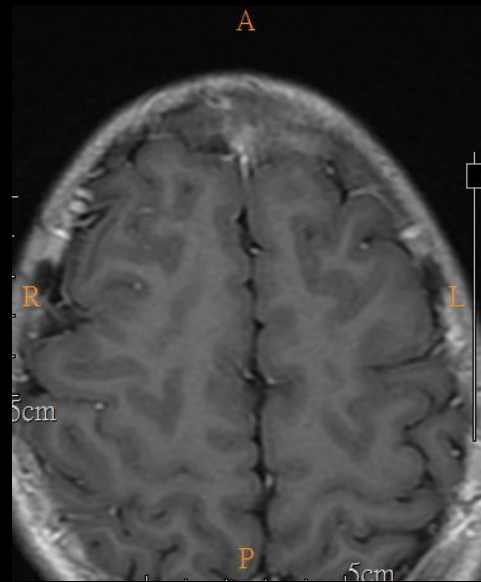
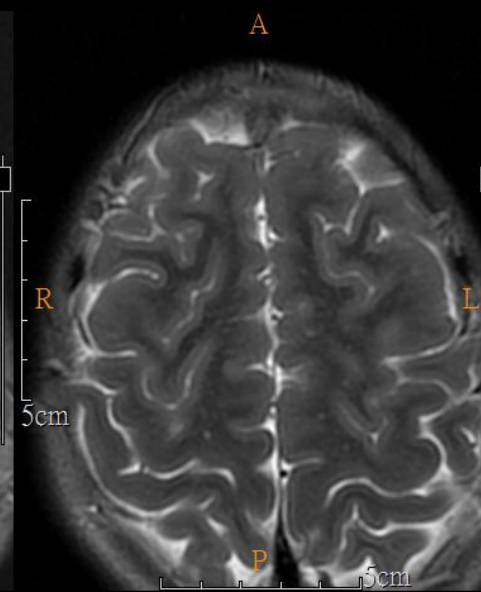
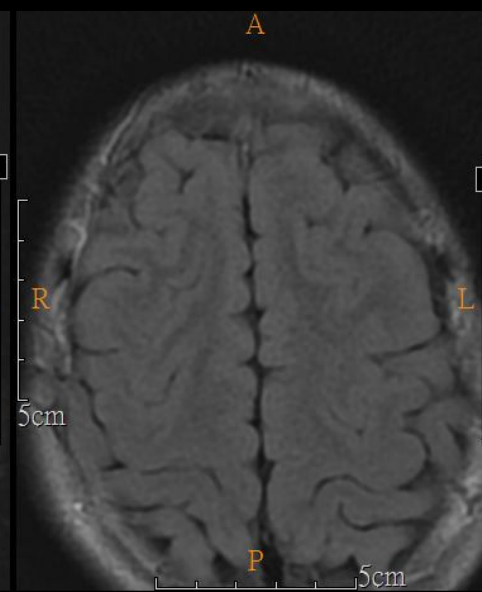
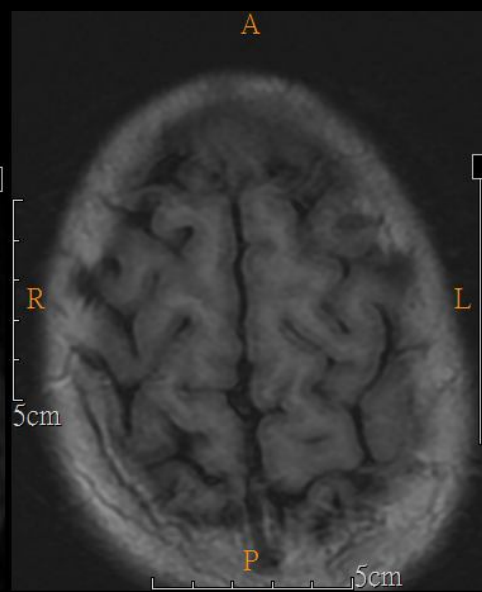
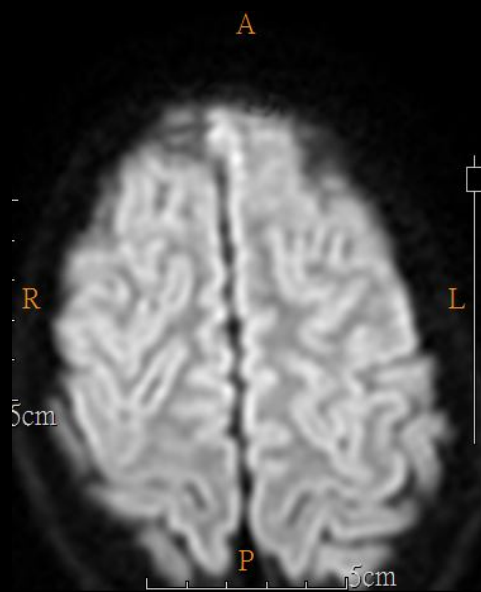
- 8 years old, male
- Chief complaint
  - Progressive low back pain for 4 weeks
  - Developed severe bilateral thigh pain for 2 weeks
- Past history
  - None

# Image

---

- 2018-11-15 L-spine MRI
- 2018-11-16 Brain MRI
- 2018-11-20 C+T spine MRI





# Differential Diagnosis

---

- Langerhans cell histiocytosis
- Other homologous malignancy
- Bony malignancy with pathological compression fracture
  
- The pathology report is pending

---

Thanks for your attention

---

影像醫學部 R4莊凱壹/鄭碩仁醫師/謝立群醫師