

**CASE 2**

**30 YEARS OLD WOMAN**

# Brief history

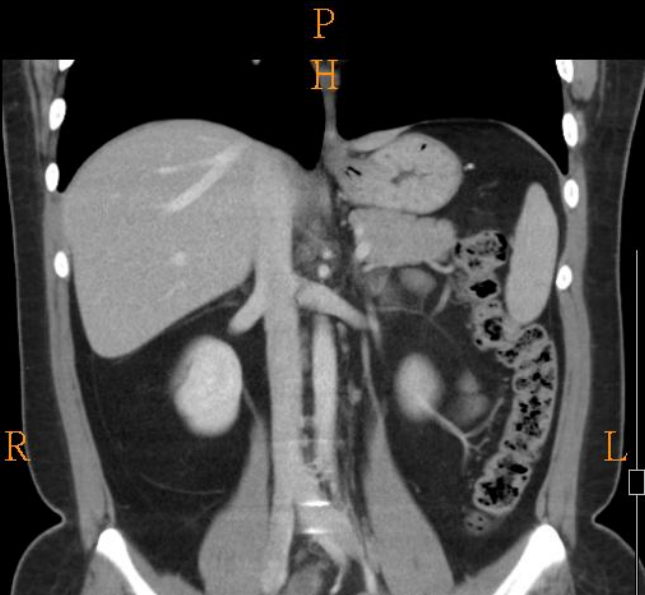
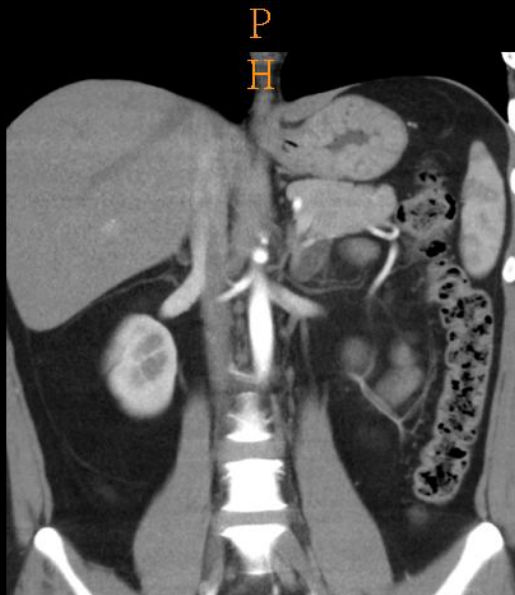
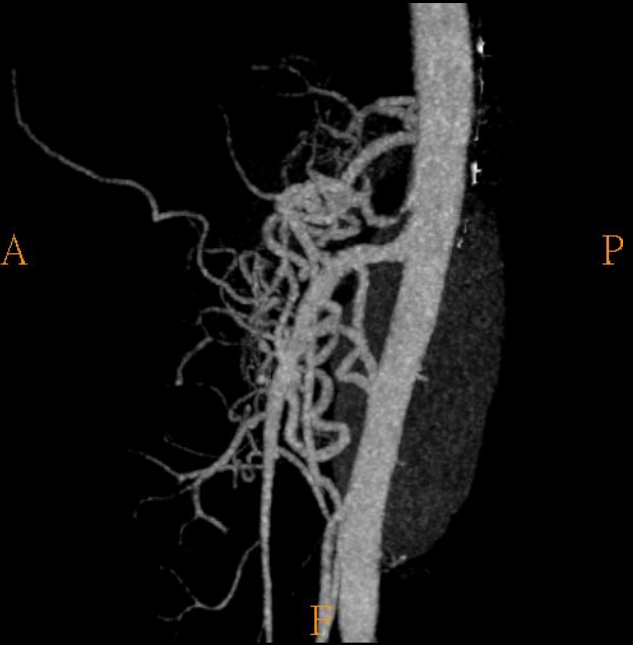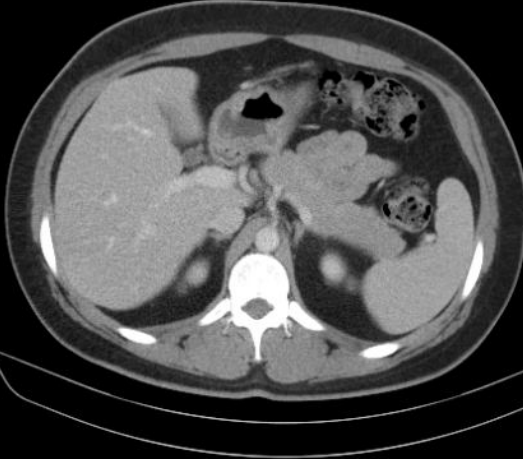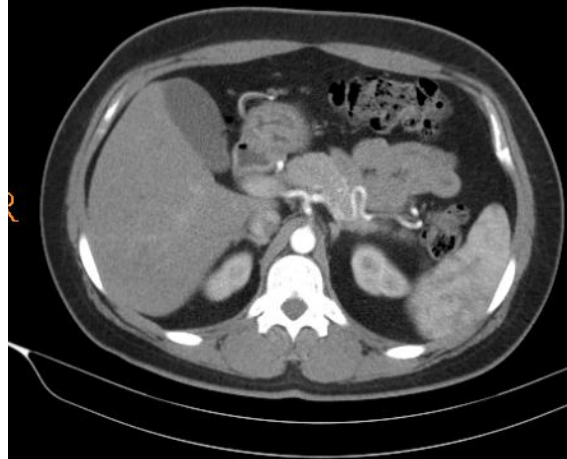- 30 years old woman
- PHx: Hypertension since high school
- Chief complain:
  - Blood pressure up to 188/90 recently.

# Imaging studies

- CT

A-phase

V-phase



# Diagnosis

- Median arcuate ligament syndrome

# Median arcuate ligament syndrome

- Abnormally low insertion of median arcuate ligament that compresses on proximal celiac axis.
- Typically thin women aged 20-40 years
- Most common signs/symptoms
  - Nausea, diarrhea, intermittent epigastric pain (particularly postprandial), and weight loss
    - =>vascular ischemia and intestinal angina
- Treatment
  - No treatment in absence of symptoms
  - Surgical release of median arcuate ligament mainstay treatment
  - However, treatment remains controversial

