

CASE 4

40 YEARS OLD MAN

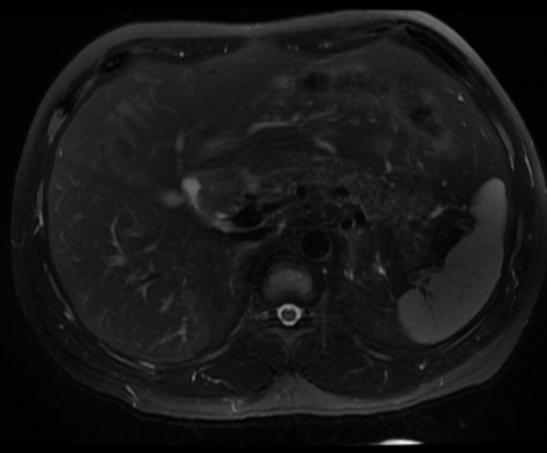
Brief history

- 40 years old man
- PHx: No major disease
- Chief complain:
 - Epigastric pain for 2 months.

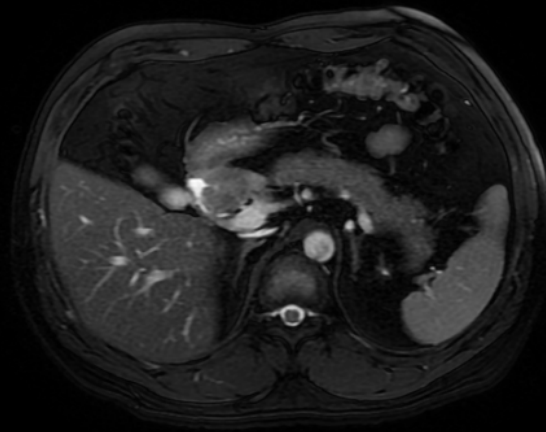
Imaging studies

- Liver MRI (+C)

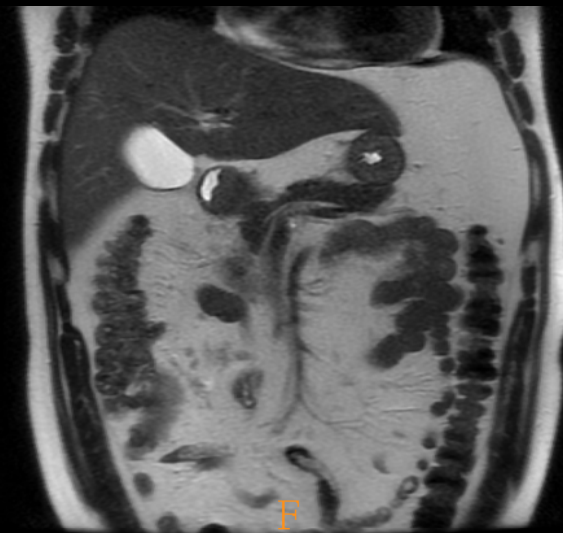
T2



FIESTA



T2

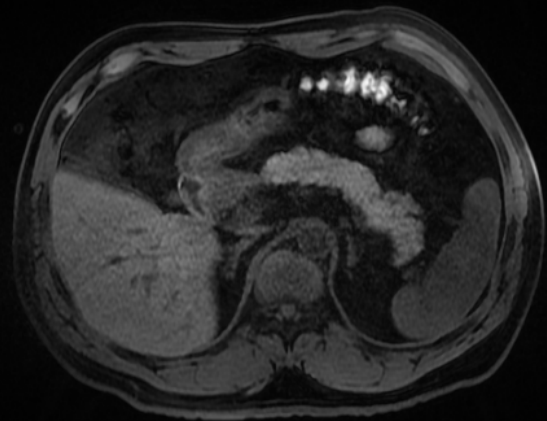


P
A

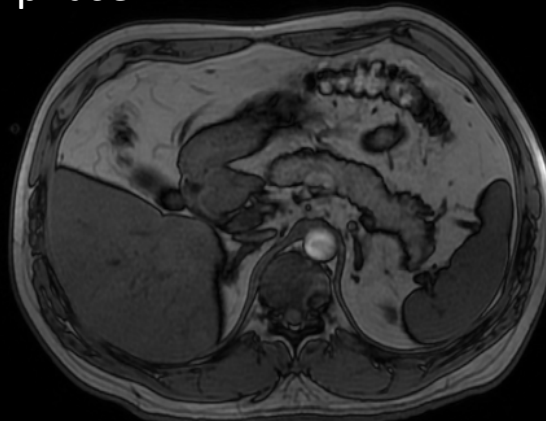
P
A

F
A

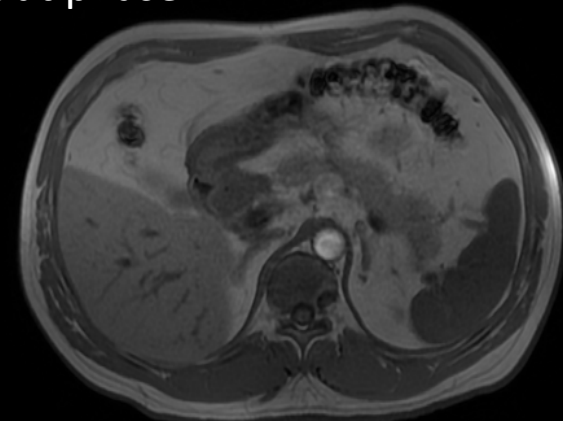LAVA



In phase



Out phase



L R

L R

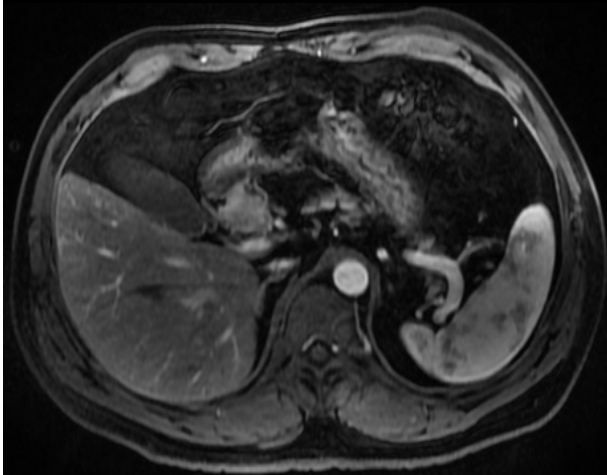L R

L R

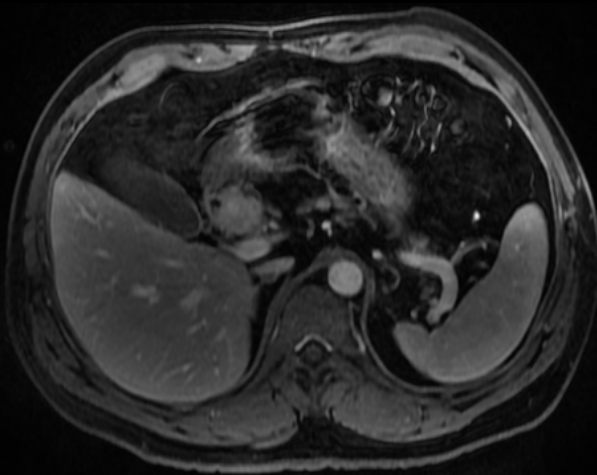
A-phase

V-phase

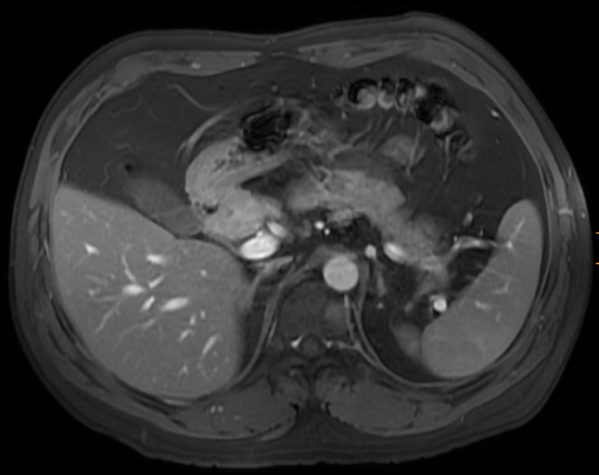
Delay phase



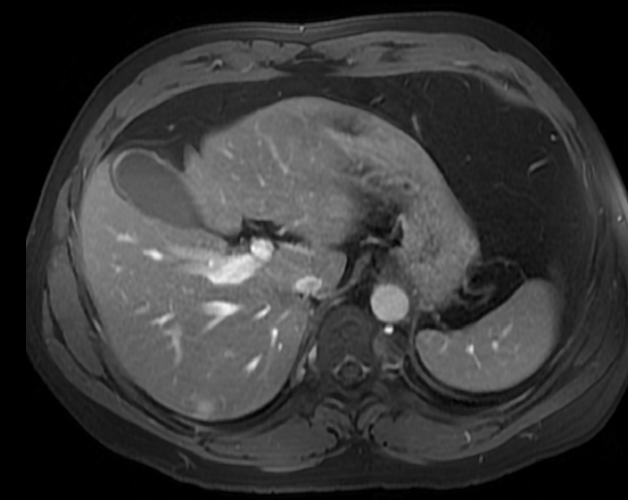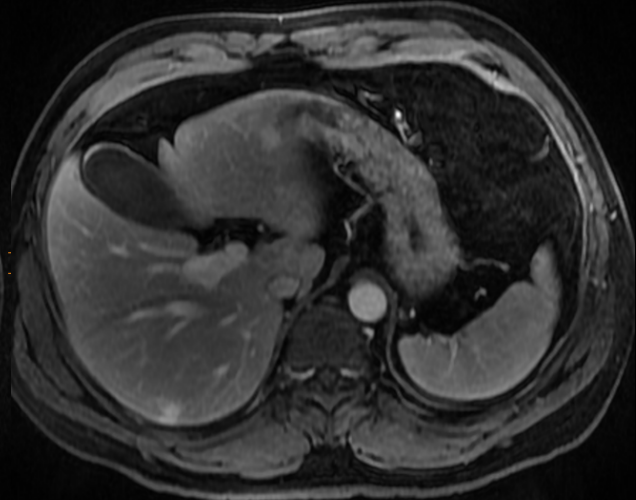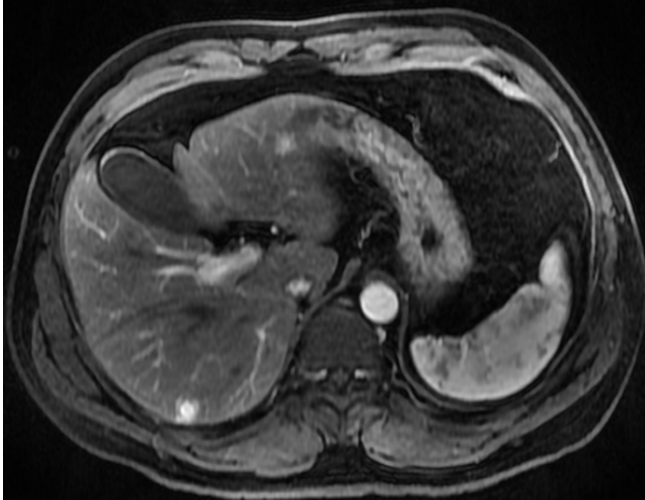LR

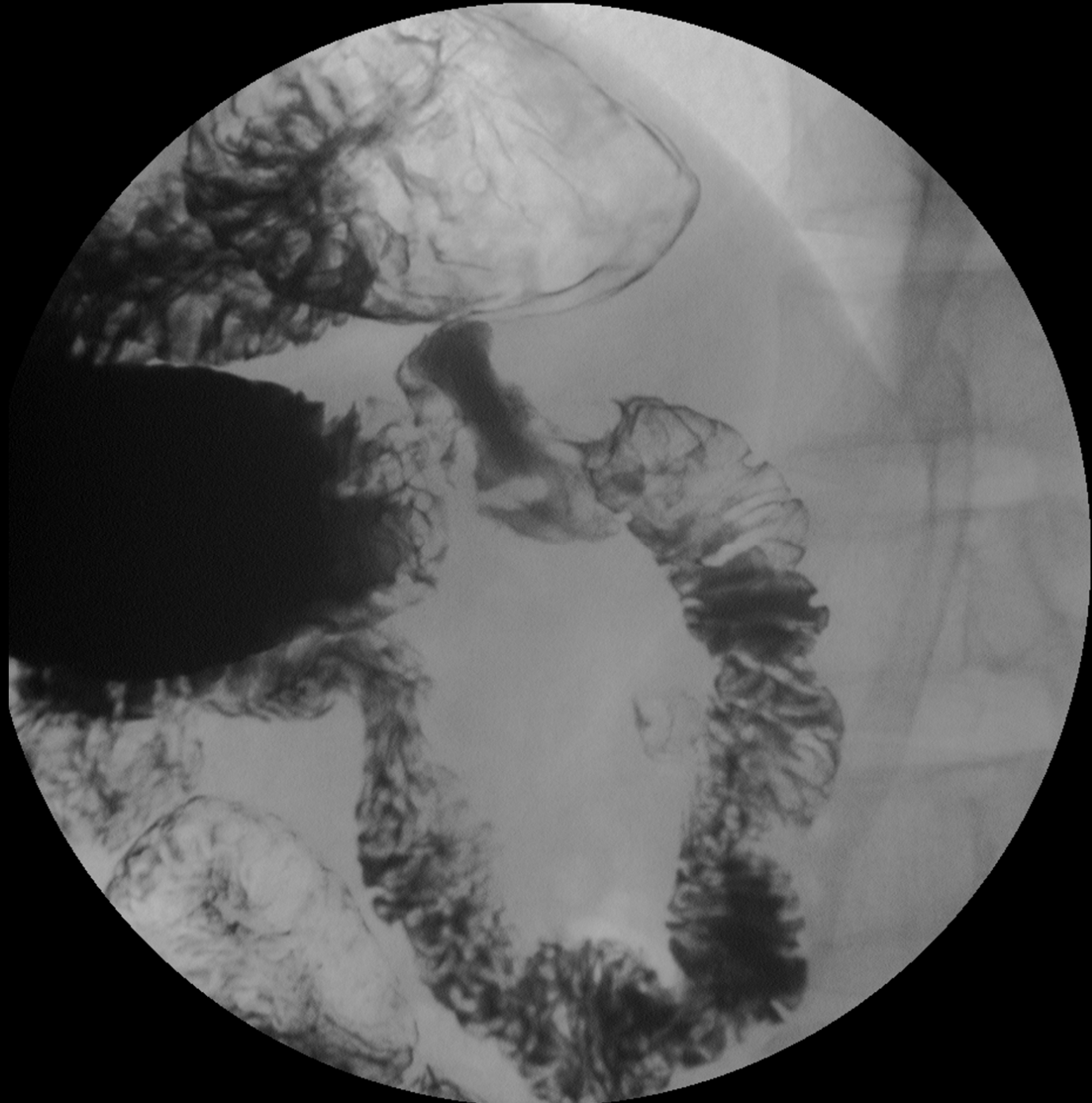


I



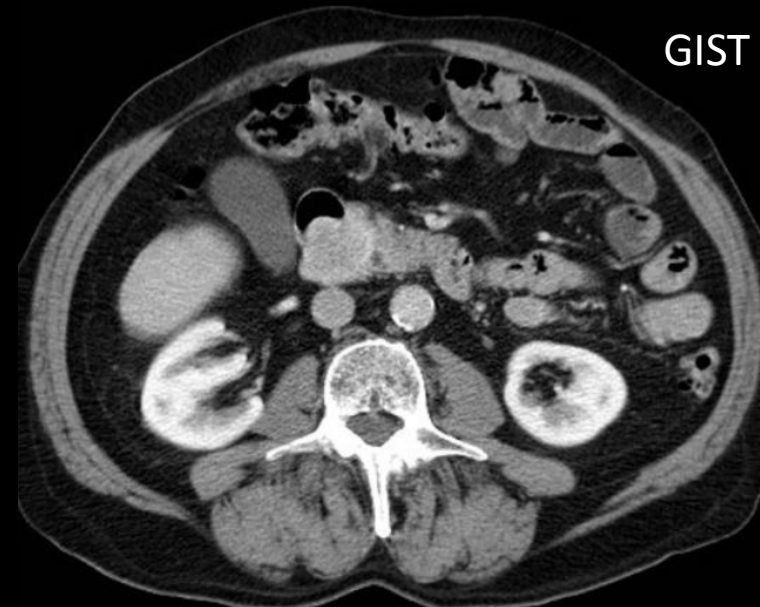
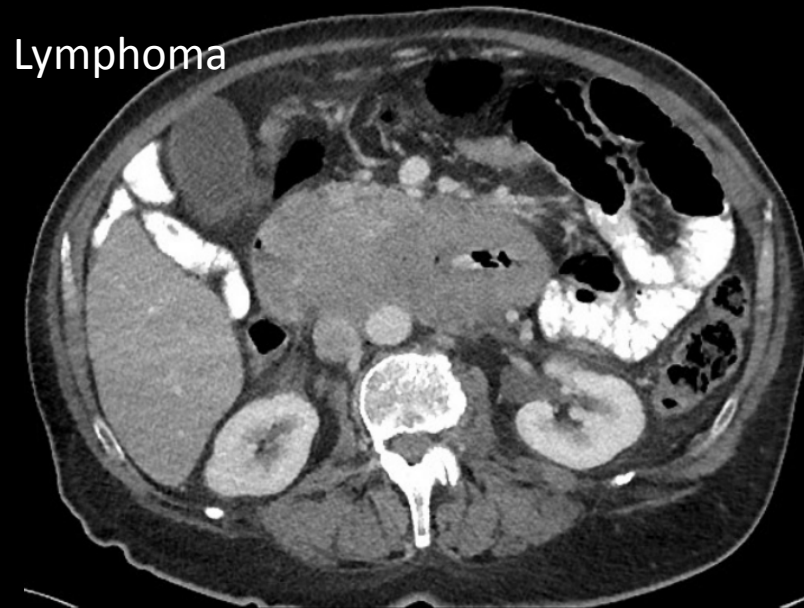
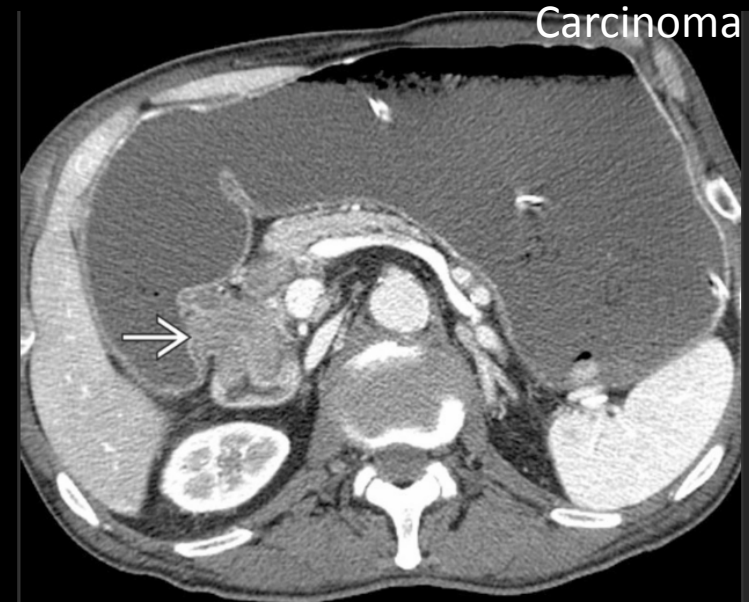
I





DDx:

- Duodenal carcinoid tumor
- Duodenal carcinoma
- GIST
- Lymphoma



- END