

**CASE 10**

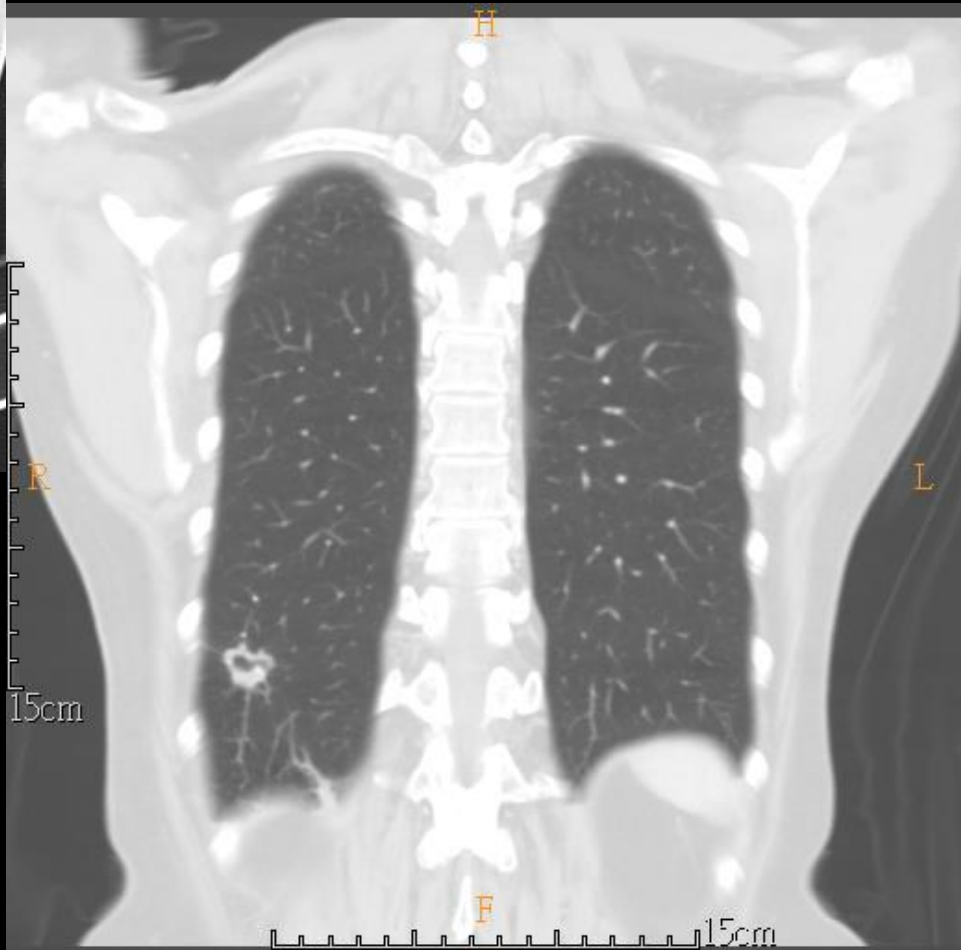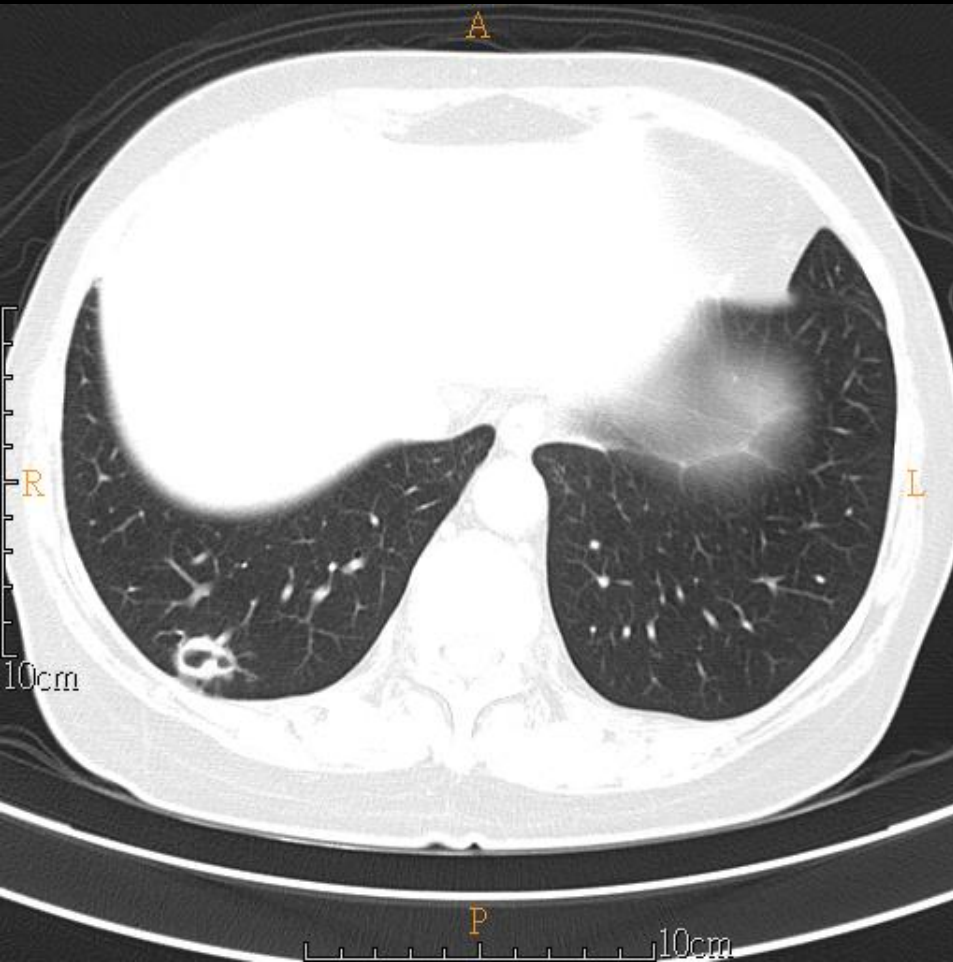
**60 YEARS OLD WOMAN**

# Brief history

- 60 years old woman
- PHx: Right breast cancer
- Chief complain:
  - Abnormal finding in regular follow-up

# Imaging studies

- 2020/10/14 CXR
- 2020/10/28 Chest CT (NoC+C)



# DDx

- lung metastasis

# Pathology

- Biopsy 11/11

病理診斷：Lung, lower lobe, right, CT-guided needle biopsy, chronic inflammation

組織報告：The specimen submitted consists of 2 tissue fragments, measuring up to 0.4 x 0.1 x 0.1 cm in size, fixed in formalin.