

CASE 11

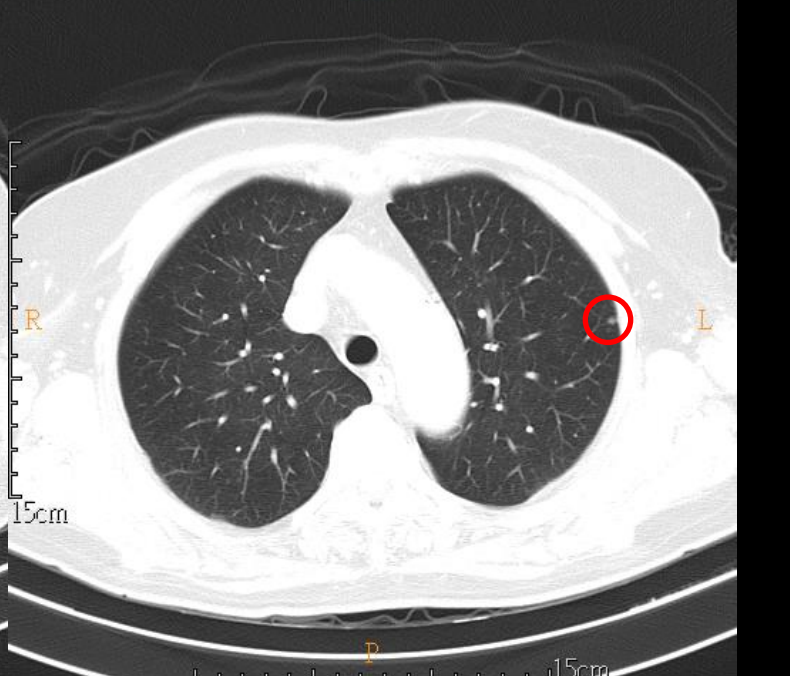
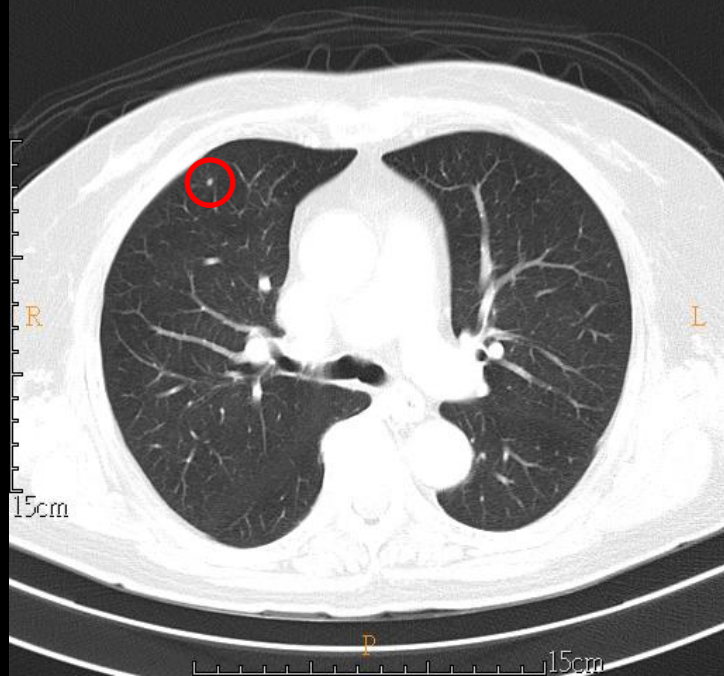
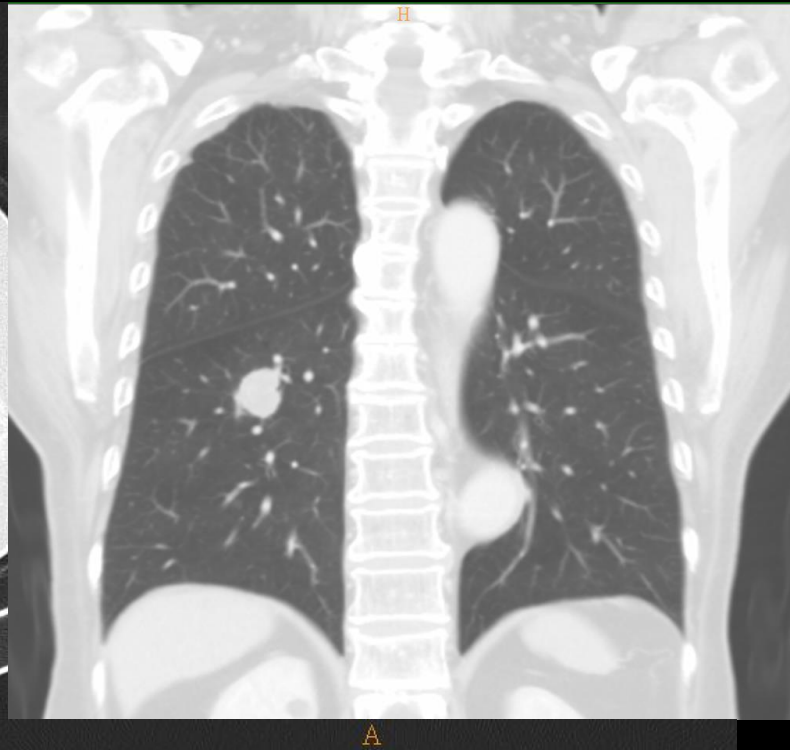
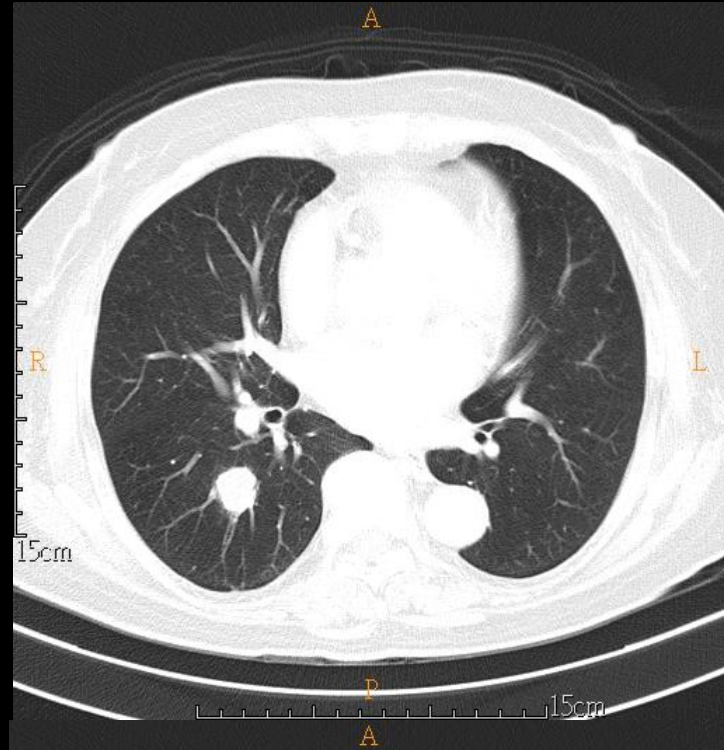
79 YEARS OLD WOMAN

Brief history

- 79 years old woman
- PHx: anorectal carcinoma
- Chief complain:
 - For tumor staging

Imaging studies

– 2020/08/14 Chest CT (NoC+C)



DDx

- lung metastasis

Pathology

- Biopsy 08/20

病理診斷：Lung, RLL, bronchoscopic biopsy, metastatic colorectal adenocarcinoma

組織報告：The specimen submitted consists of five tissue fragments measuring up to 0.7 x 0.3 x 0.2 cm, in size, fixed in formalin.