

**CASE 4**

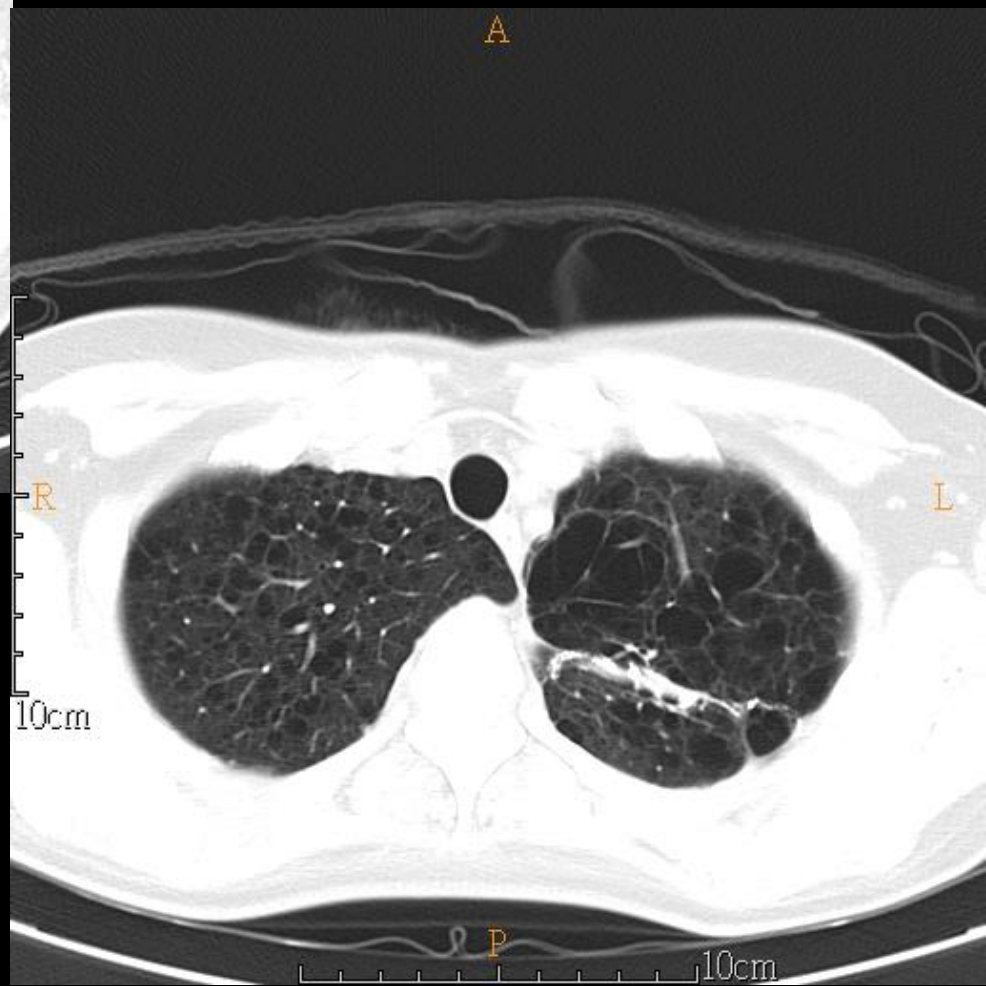
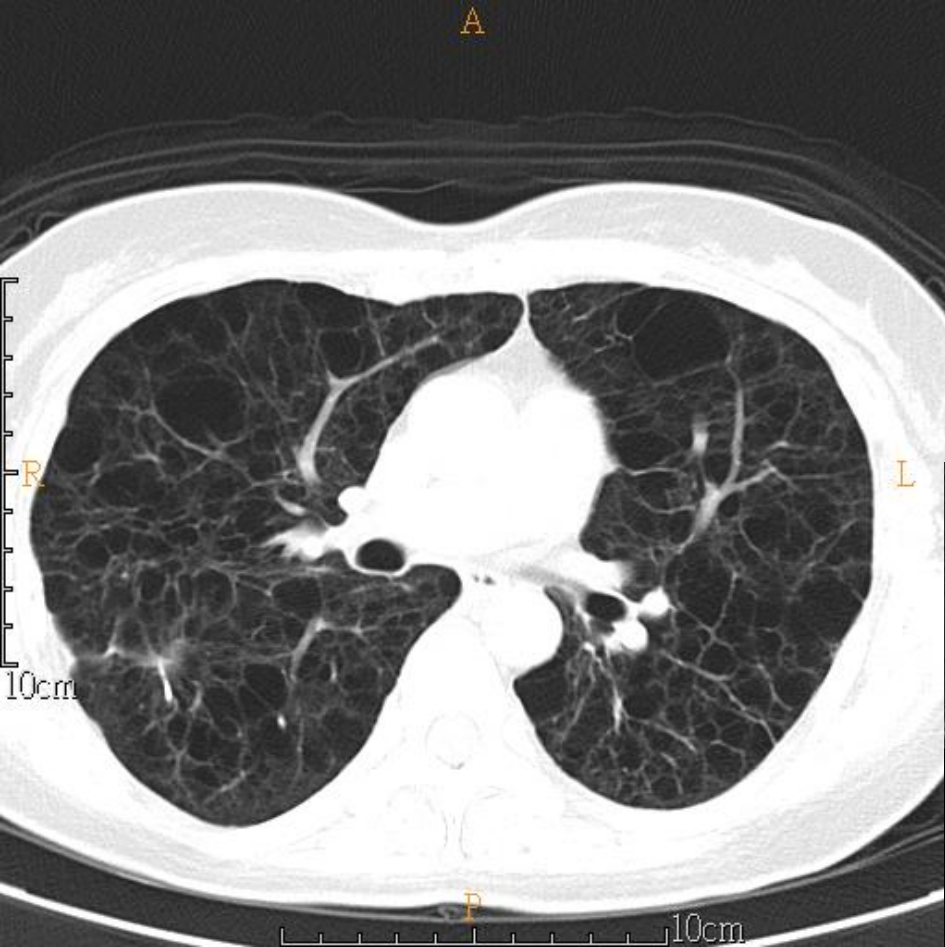
**48 Y/O WOMAN**

# Brief history

- 48 years old woman
- Chief complain:
  - Breathless sensation
  - Chest pain occasionally
  - On and off rhinorrhea

# Imaging studies

- 2020/12/01 CXR
- 2020/12/29 Chest CT (NoC)



# DDx:

- Lymphangiomyomatosis (LAM)
- Emphysema