

CASE 2

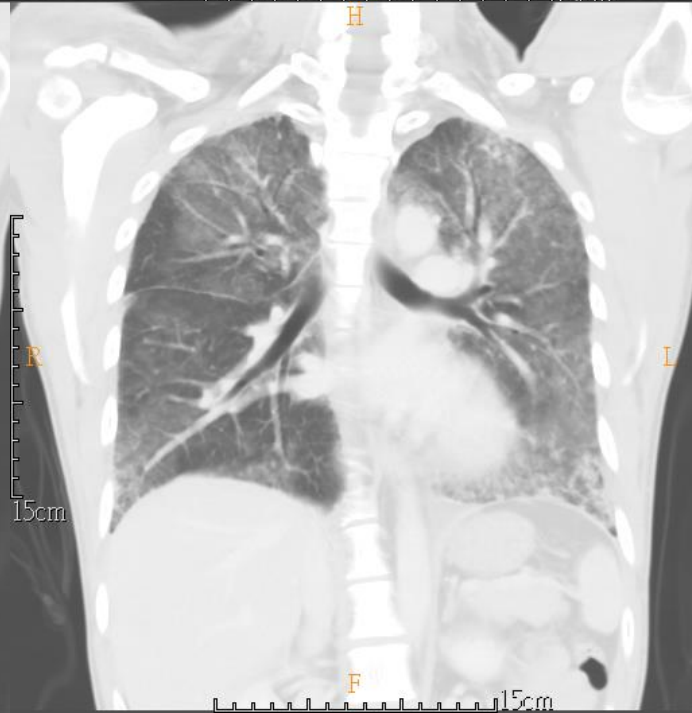
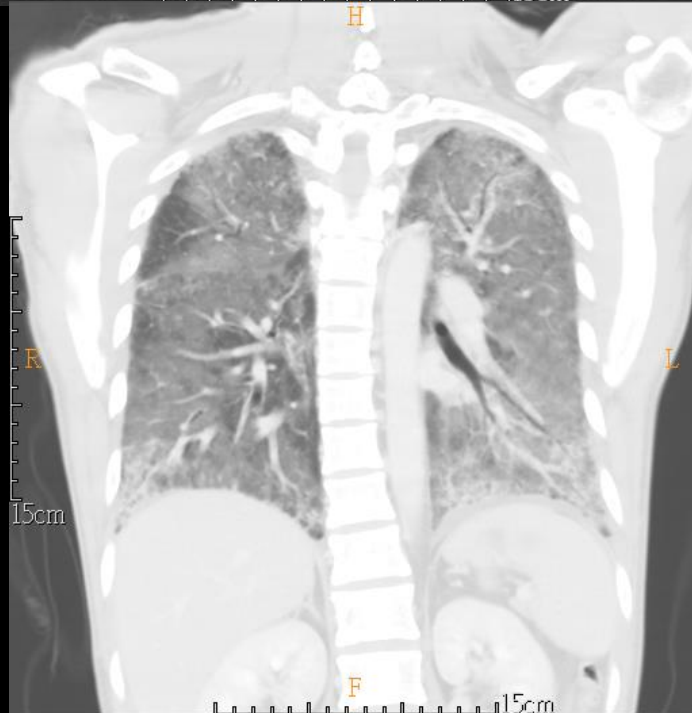
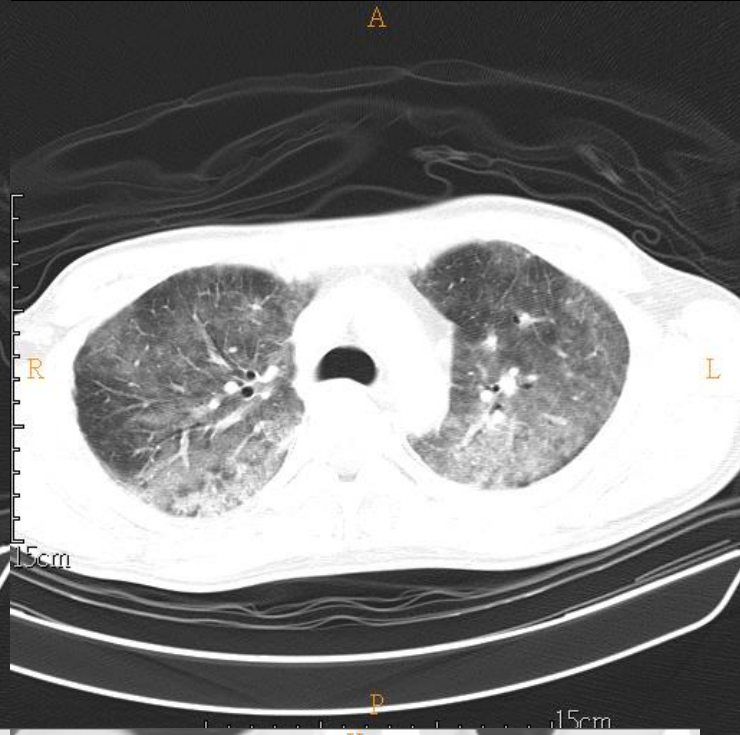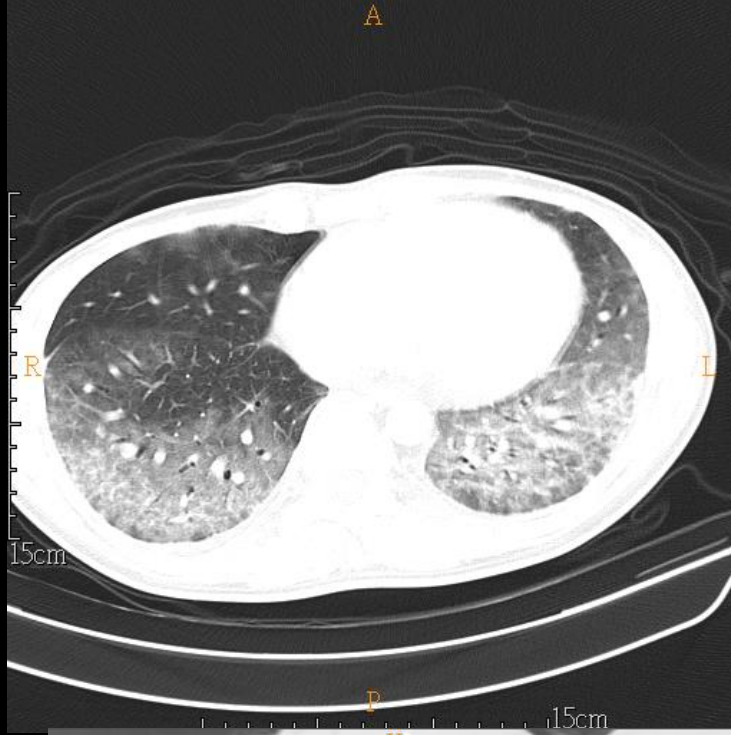
34 YEARS OLD MAN

Brief history

- 34 years old man
- PHx: HIV for 4 years without control
- Chief complain:
 - Fever for 3 days

Imaging studies

- 2021/01/05 CXR
- 2021/01/09 Chest CT (NoC+C)



DDx:

- CMV infection, according to the history

Lab

Toxoplasma IgG Ab (血液)(委外) IU/ml [弓漿蟲IgG 抗體]			0.1 IU/ml [<1.6]
Toxoplasma IgG結果 [弓漿蟲IgG 抗體]			Negative
Toxoplasma IgG生物參考區間 [弓漿蟲IgG 抗體]			Negative:<1.6 IU/mL; Equivocal:1.6-2.9 IU/mL; Positive:>=3.0
RPR (VDRL) (血液)		reactive[1:16]	
RPR(血液)生物參考區間		non-reactive	
TPPA (TPHA) (血液)		Positive[1:10240]	
TPPA(血液)生物參考區間		Negative[<1:80]	
*Cryptococcus Ag (血液)(委外)		Negative	
CMV IgG (血液)(委外) [巨大細胞病毒抗體 酵素免疫法]			>250.000 AU/ml [<6.000]
CMV IgG 結果 [巨大細胞病毒抗體 酵素免疫法]			Positive
CMV IgG 生物參考區間 [巨大細胞病毒抗體 酵素免疫法]			Negative:<6.0 AU/mL; Equivocal:6.0-15.0 AU/mL; Positive:> 15.0 AU/mL
CMV IgM (血液)(委外) [巨細胞病毒核抗原抗體]			0.080 index [<0.85]
CMV IgM 結果 [巨細胞病毒核抗原抗體]			Negative
CMV IgM 生物參考區間 [巨細胞病毒核抗原抗體]			Negative:<0.85 Index; Grayzone:0.85-0.99 Index; Positive:>=1.00 Index

簽收日期	1100106
簽收時間	1906
工作單號	1201410799
試管編號	1201410799
報告日期	1100107
報告時間	1435
*Legionella Ag (尿液)(委外) [退伍軍人症尿抗原試驗]	Negative
Pneumoniae Ag (尿液) [尿液肺炎球菌抗原]	Negative

CMV Pneumonia

- Immunocompromised adults
- Diffuse or lower lung zone predominance
- CT
 - Pulmonary consolidation
 - Patchy or diffuse ground-glass opacities
 - Small nodules in random distribution
 - Tree-in-bud opacities

CMV Pneumonia

- DDX
 - Pneumocystis jiroveci Pneumonia (PCP)
 - Drug Reaction
 - Viral pneumonia