

CASE 3

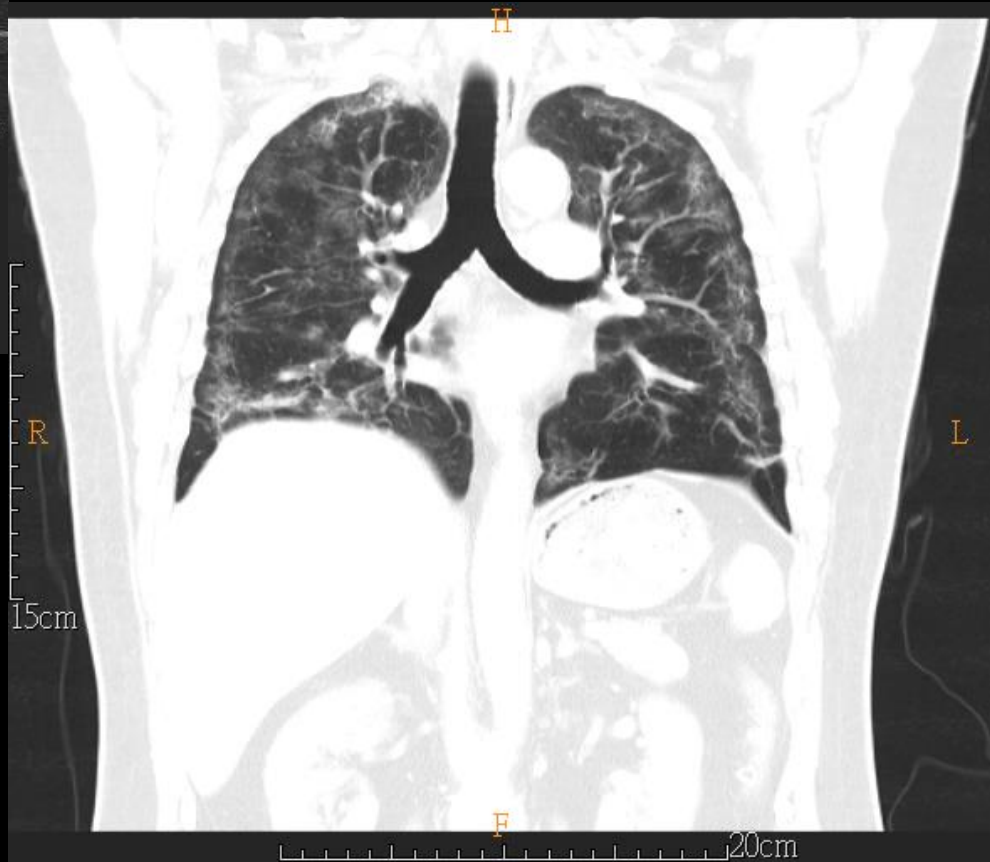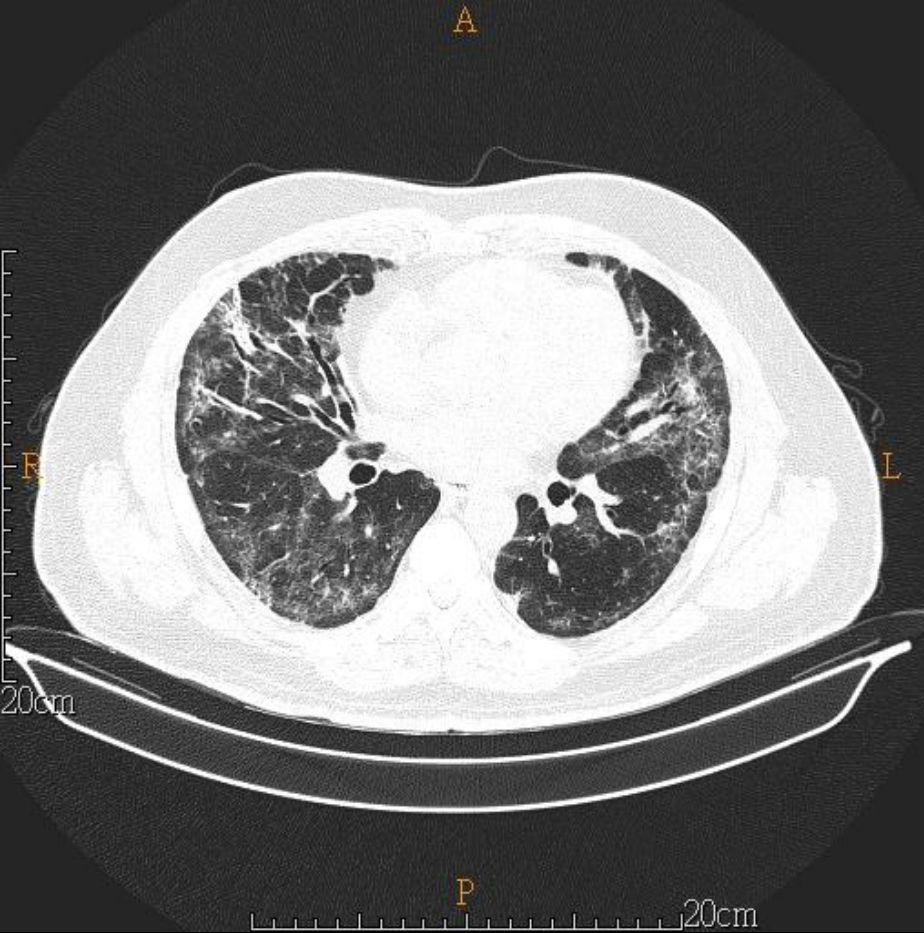
50 YEARS OLD MAN

Brief history

- 50 years old man
- PHx: asthma, hypertension
- Chief complain:
 - short of breath for 2+ weeks
- TOCC:
 - businessman in Ghana, Africa

Imaging studies

- 2020/11/20 CXR
- 2020/12/07 Chest CT (NoC+C)



DDx:

- COVID-19 pneumonia

Lab

- positive screening test in Ghan (11/05)