

**CASE 4**

**64 YEARS OLD MAN**

# Brief history

- 64 years old man
- PHx: type 2 DM, hypertension
- Chief complain:
  - short of breath for 1 week

# Imaging studies

- 2021/01/18 CXR
- 2021/01/18 Chest CT (NoC+C)

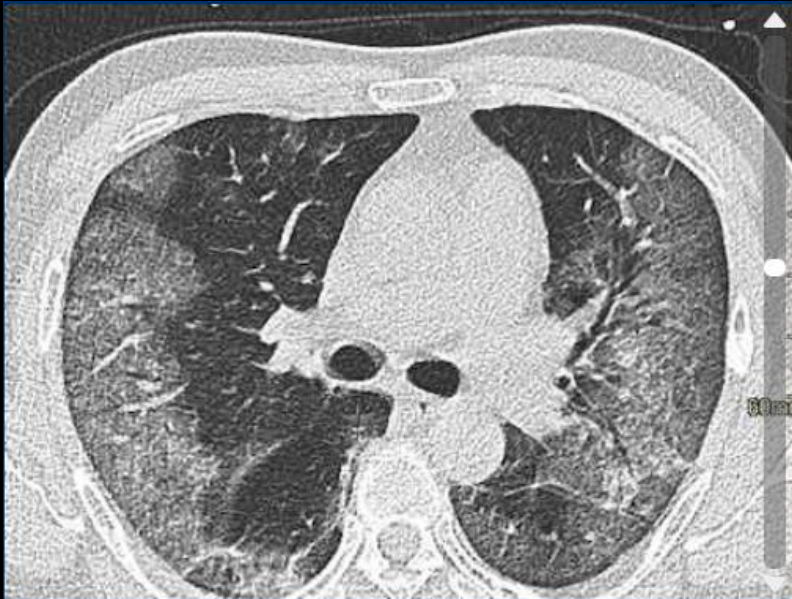
# Lab

簽收日期	<a href="#">1100118</a>	<a href="#">1100118</a>
簽收時間	1926	1753
工作單號	1502677667	1502677608
試管編號	1502677667	1502677608
報告日期	1100118	1100118
報告時間	1934	1806
WBC [白血球]		6.83 10 <sup>3</sup> /uL [4.00-11.00]
RBC [紅血球]		3.92 10 <sup>6</sup> /uL [4.20-6.10]
HGB [血紅素]		13.8 g/dL [13.0-17.0]
HCT [血球容積比]		38.4 % [39.0-52.0]
MCV [平均血球容積]		98.0 fL [80.0-99.0]
MCH [平均血球血紅素]		35.1 pg [26.0-34.0]
MCHC [平均血球血紅素濃度]		35.8 g/dL [33.0-37.0]
RDW [紅血球分佈寬度]		14.5 % [11.5-14.5]
PLT [血小板]		218 x10 <sup>3</sup> /uL [130-400]
MPV [平均血小板體積]		9.48 fL [7.20-11.10]
RDW-SD [紅血球分佈寬度-標準差]		50.3 fL
PDW [血小板分佈寬度]		18.2 fL
PCT [全套血液檢查 I (八項)]		0.21 % [0.16-0.35]
%NEUT [嗜中性球百分比]		81.9 % [40.0-74.0]
%LYM [淋巴球百分比]		9.6 % [19.0-48.0]
%MONO [單核球百分比]		8.2 % [2.0-12.0]
%EOS [嗜酸性球百分比]		0.1 % [0.0-7.0]
%BASO [嗜鹼性球百分比]		0.2 % [0.0-2.0]

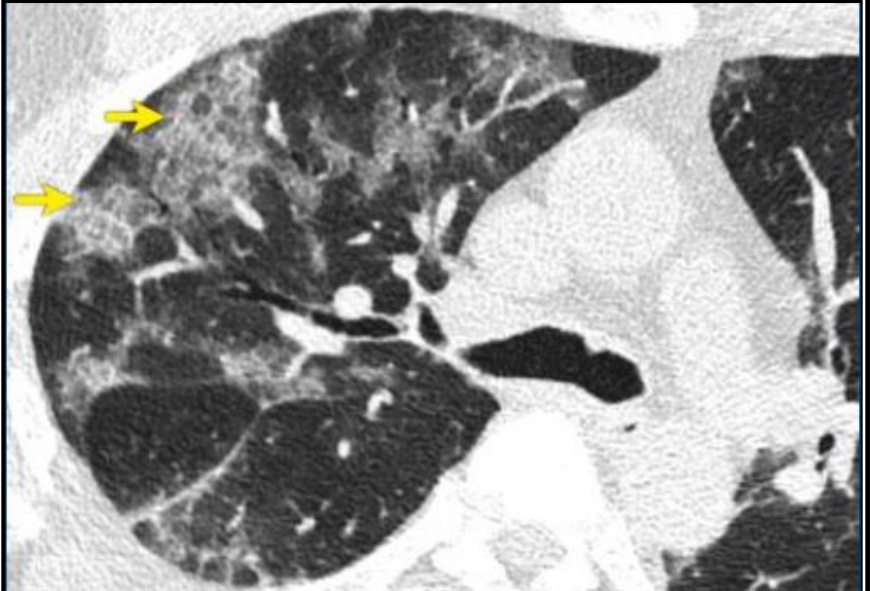
簽收日期	<a href="#">1100118</a>
簽收時間	1753
工作單號	1201414836
試管編號	1201414836
報告日期	1100118
報告時間	1828
Mycoplasma pneumoniae IgM(血液)	Positive

# COVID-19

- Ground glass
  - multifocal, bilateral and peripheral

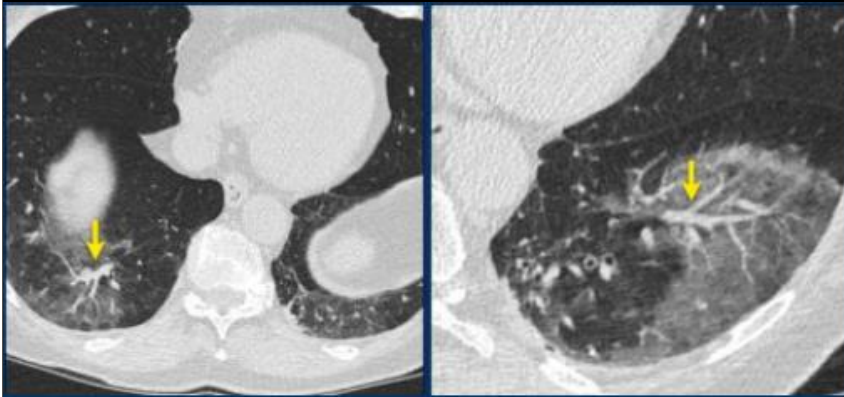


- Crazy paving
  - thickened interlobular and intralobular lines
  - combination with a ground glass pattern



# COVID-19

- Vascular dilatation
  - widening of the vessels in the area of ground glass



- Traction Bronchiectasis
  - in the areas of ground glass

