

**CASE 7**

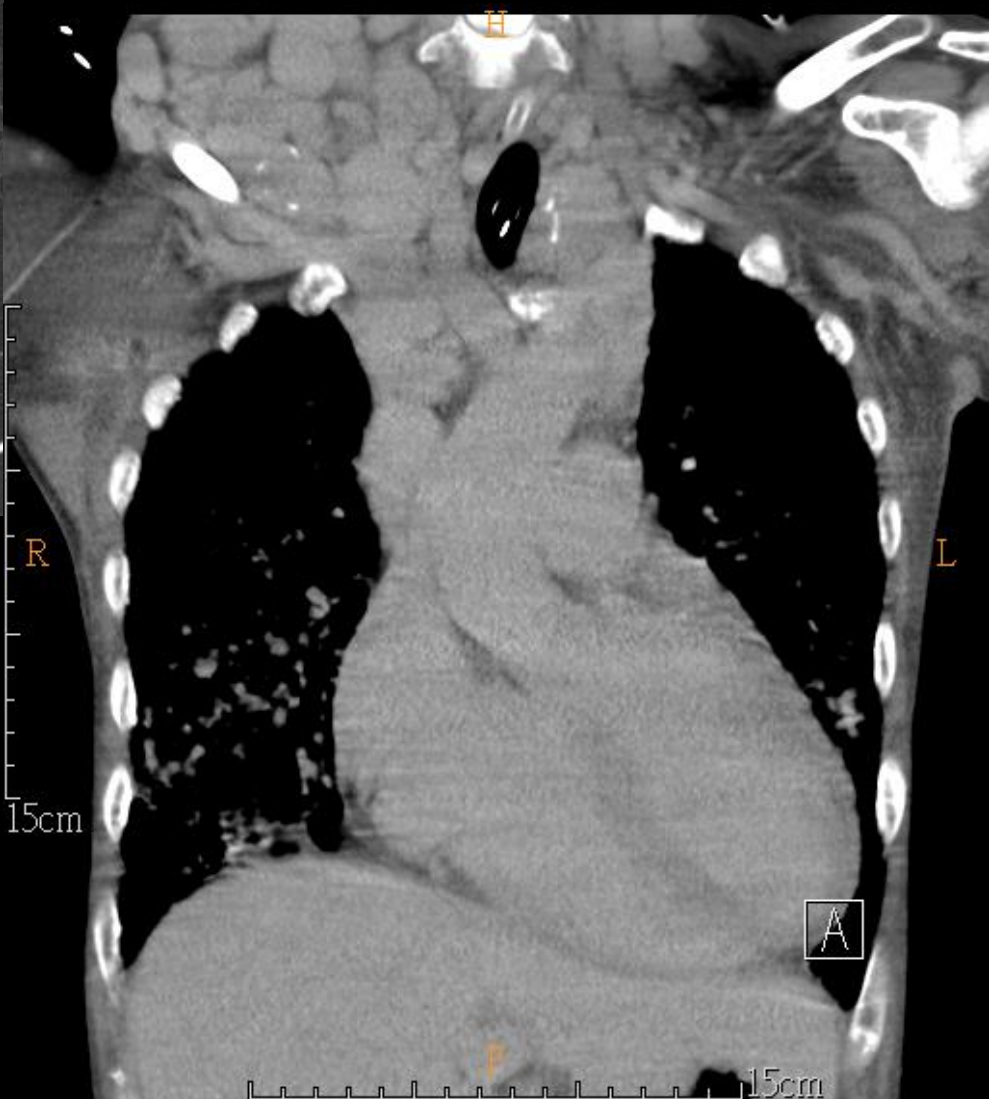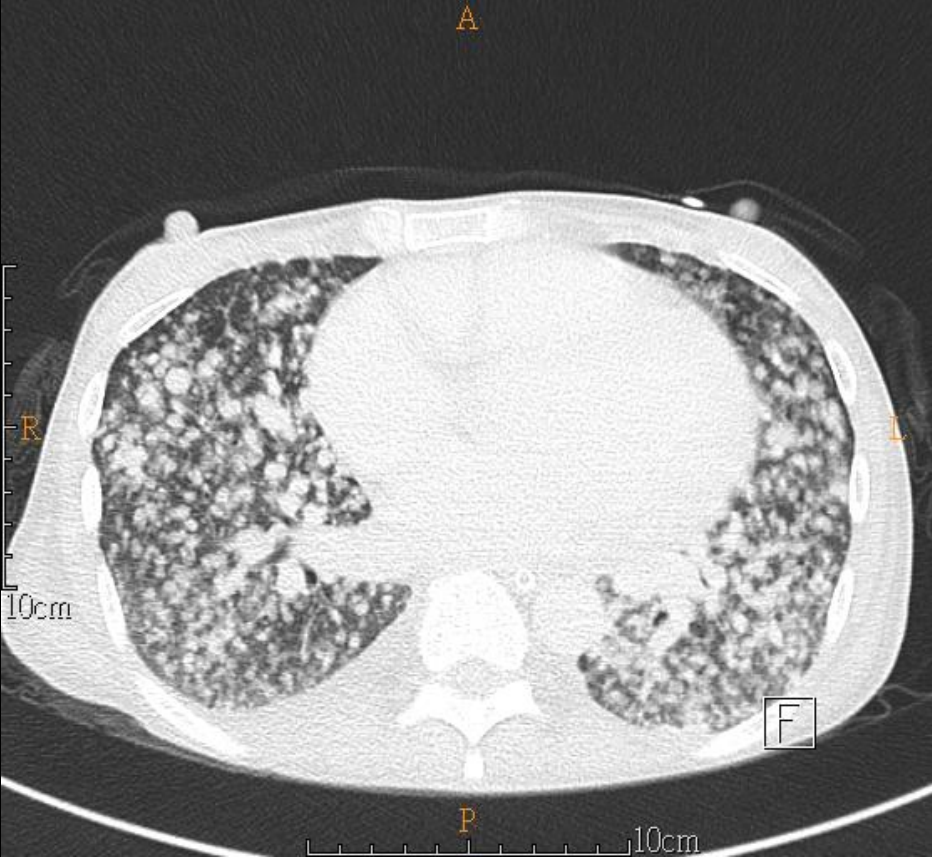
**46 YEARS OLD WOMAN**

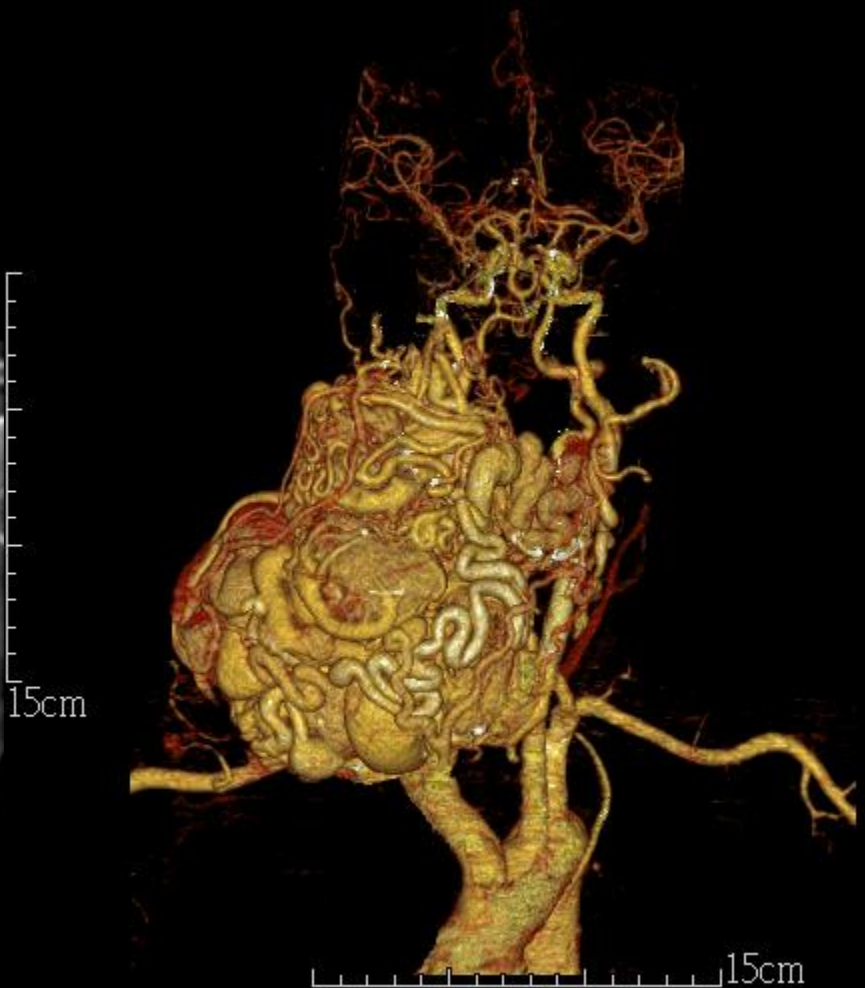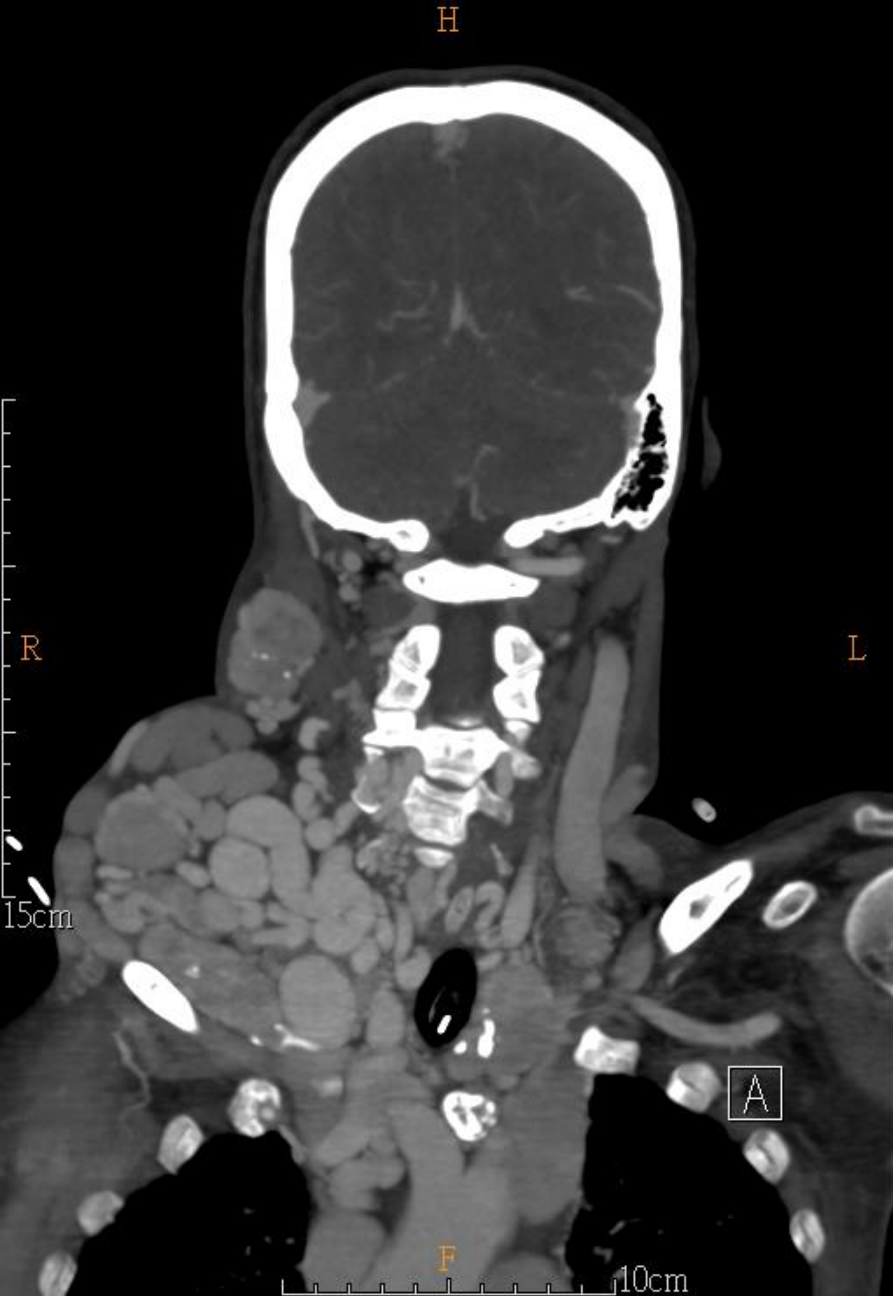# Brief history

- 46 years old woman
- PHx: hyperthyroidism and right neck swelling more than 10 years
- Chief complain:
  - Right leg regional swelling for few months
  - Exertional dyspnea for 2-3 months

# Imaging studies

- 2020/12/11 CXR
- 2020/12/14 Chest CT (NoC+C)





# DDx

- Chest
  - Hemosiderosis
  - other lung nodules
- Head & Neck
  - arteriovenous malformation

# Pathology

- Biopsy 12/15, 12/18

病理診斷：Soft tissue, right neck, biopsy, vascular hyperplasia and ectasia

組織報告：The specimen submitted consists of one tissue fragment measuring 0.5 x 0.4 x 0.2 cm in size, fixed in formalin.

病理診斷：Lung, bronchus, middle lobe, right, bronchoscopic biopsy, negative for malignancy

組織報告：The specimen submitted consists of one tissue fragment measuring 0.2 x 0.2 x 0.2 cm, in size, fixed in formalin.