

**CASE 9**

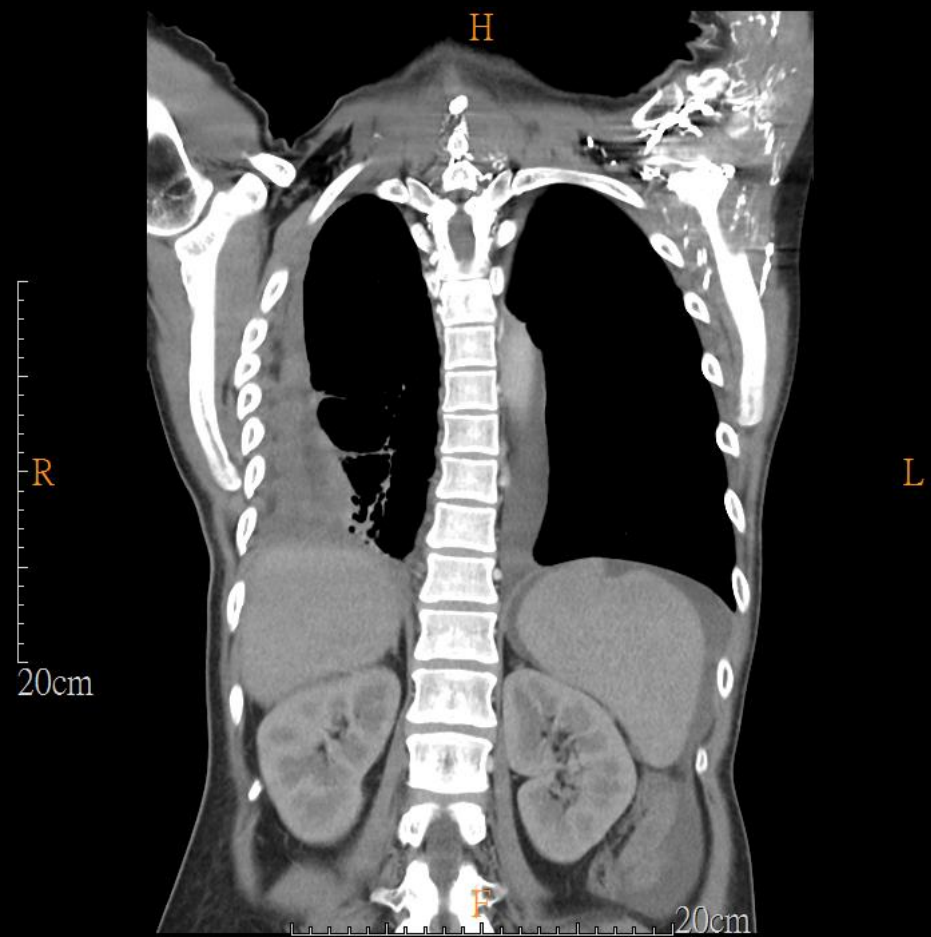
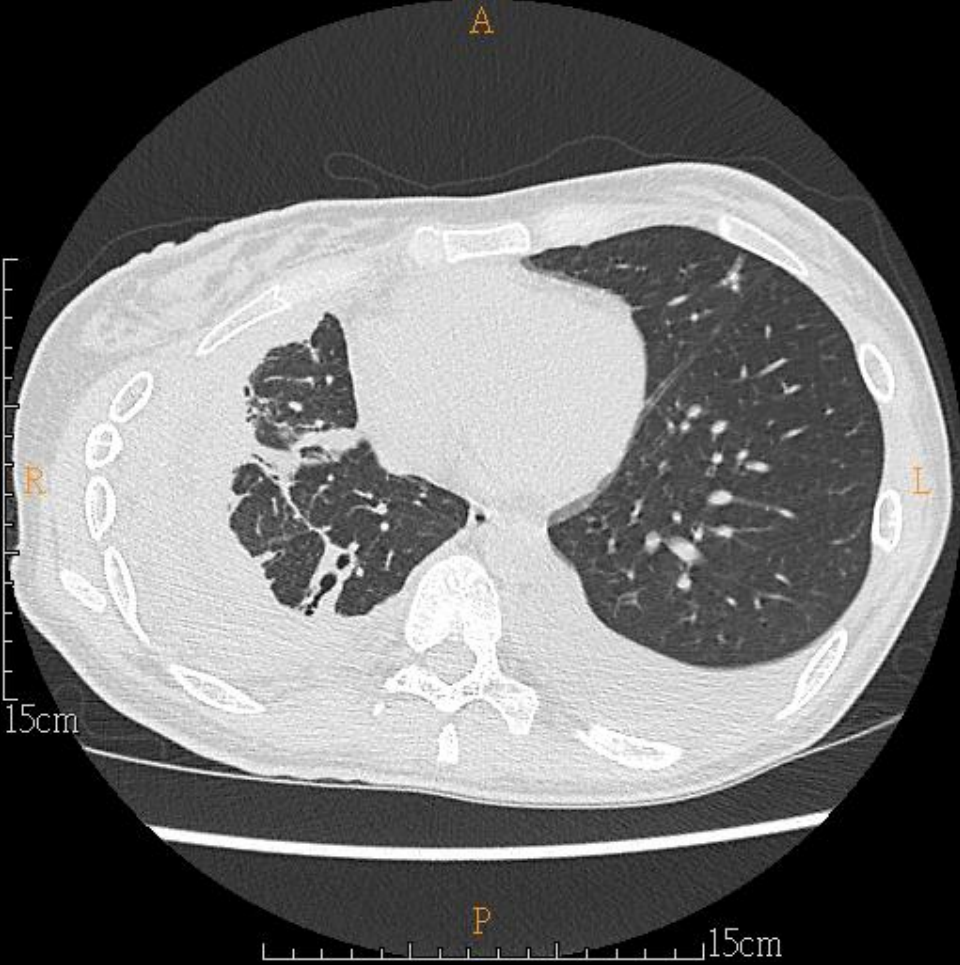**33 YEARS OLD WOMAN**

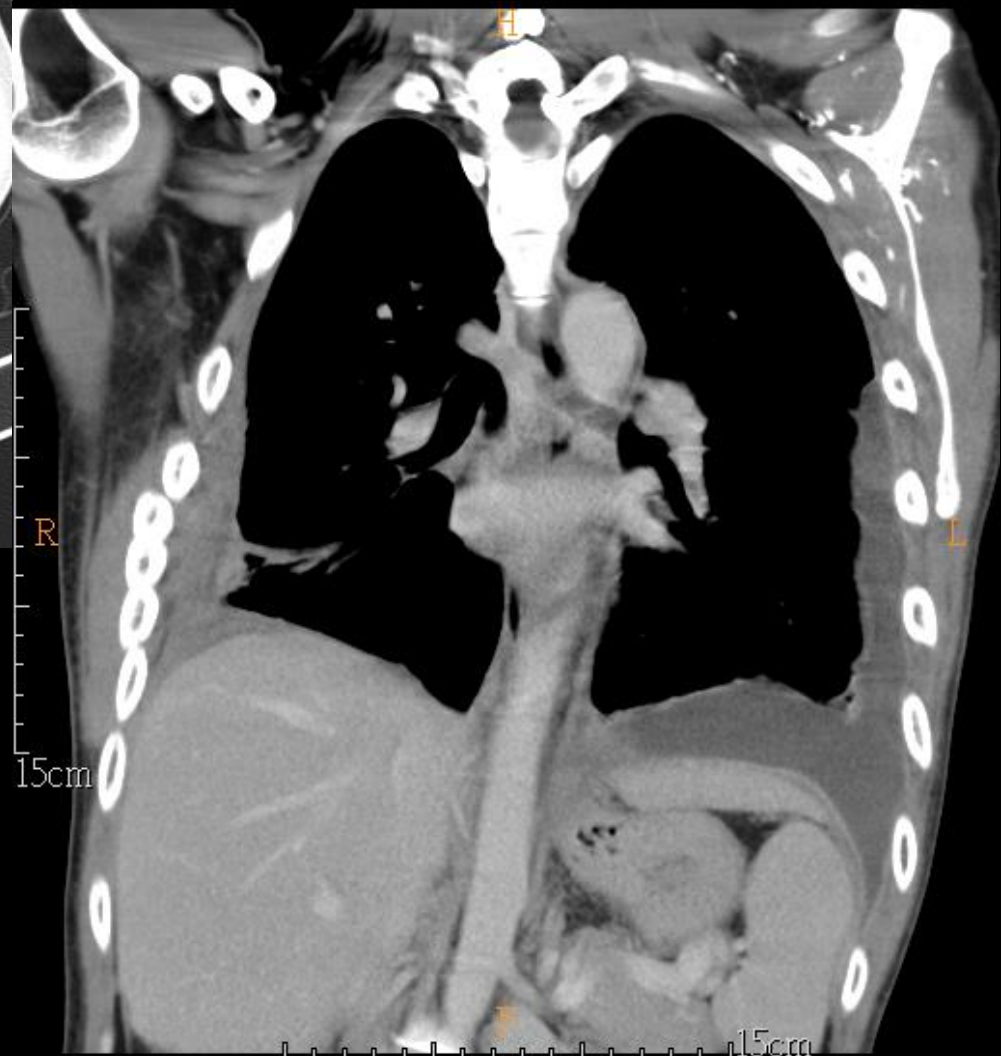
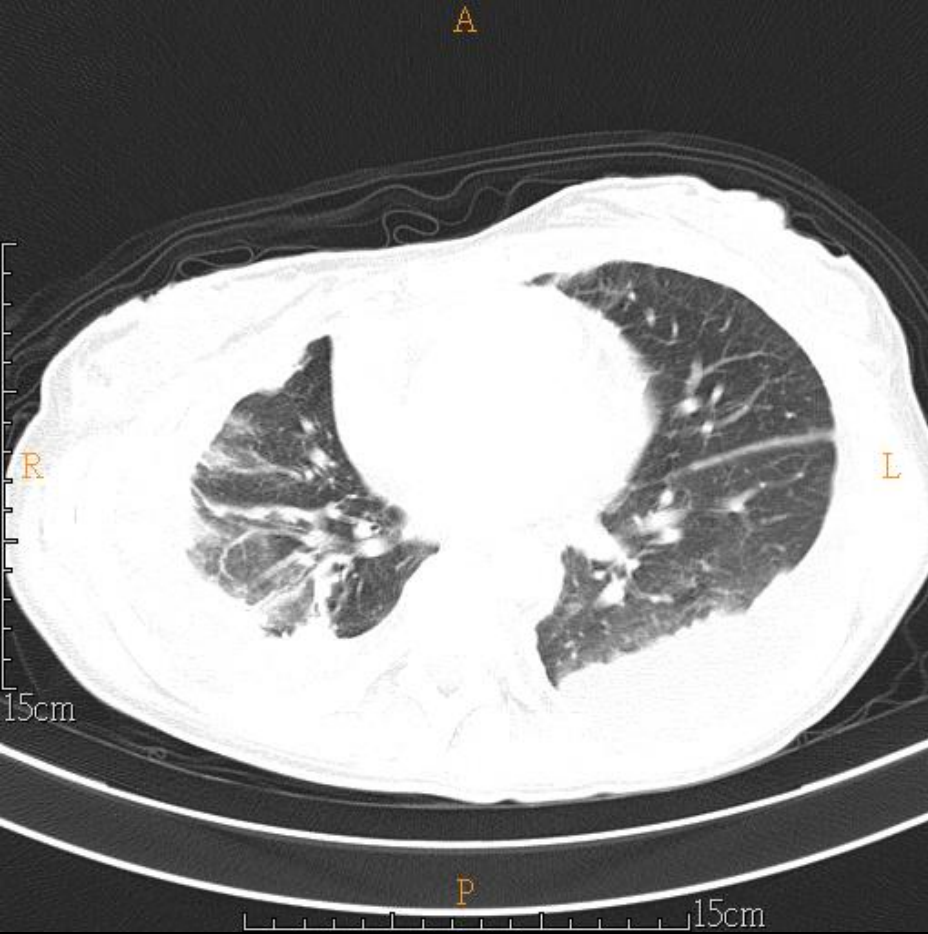# Brief history

- 31 years old woman
- PHx: denied
- Chief complain:
  - Abnormal CXR finding at healthy examination

# Imaging studies

- 2020/10/21 CXR
- 2020/10/22 HRCT
- 2020/12/31 Chest CT (NoC+C)





## DDx:

- Pleural tumor
- Empyema necessitans
- chronic TB pleurisy

# Pathology

- Biopsy 10/27

病理診斷：Pleural, right , CT-guided biopsy, chronic granulomatous inflammation

組織報告：The specimen submitted consists of two tissue fragments measuring up to 2.0 x 0.1 x 0.1 cm in size, fixed in formalin. Grossly, they are gray, soft, and cord-like.

# Lab

簽收日期	<a href="#">1091229</a>
簽收時間	1607
工作單號	1900528060
試管編號	1900528060
報告日期	1100114
報告時間	1346
Culture	TB culture (Pleural)(外送)
註記	
委外代檢機構	市立萬芳醫院
TB 細菌培養結果	MGIT 陽性 and ICT 陽性 (生物參考區間: 陰性)
細菌培養結果	
Isolated 1	