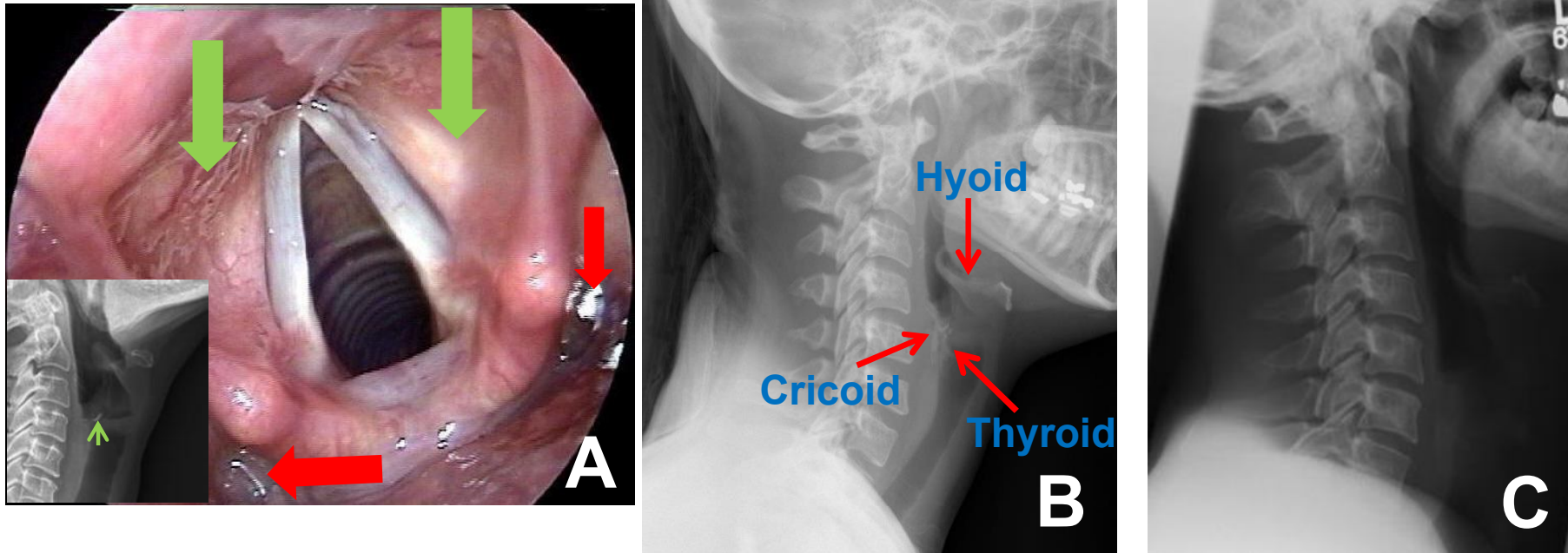


# Ans: Fish bone in throat



**About 80% of foreign body in the throat occur in young children less than 4 years of age. Fish bone in the throat most commonly happens to adult. The thin bone is often lodged in the vestibules of the larynx (green arrows in A) and pyriform sinus (red arrow in A). A lateral neck x-ray with low kVp has better chance to see the foreign body (B). A standard x-ray for cervical spine will always miss the small foreign objects (C). Knowing the anatomy of anterior neck cartilage may help differentiate fish bone from normal bone (B).**