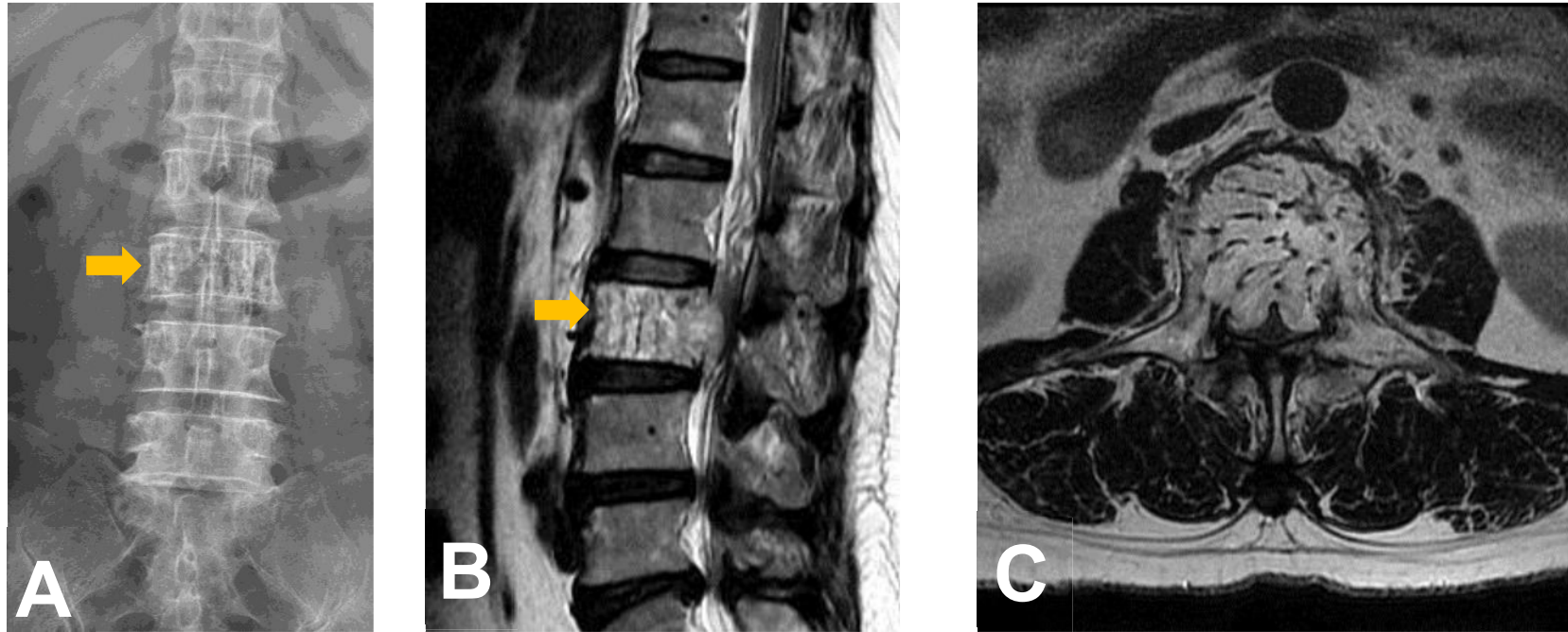


Ans: Vertebral hemangioma



Vertebral hemangioma is benign vascular tumor and the most common incidental findings in routine MR scan. Typical plain film findings are loss of bone density with coarse vertical trabeculae (Jail bar – figure A and B) which appears on axial CT or MRI as “Polka Dot” pattern (figure C). Aggressive lesion may shows contrast enhancement on post contrast T1WI.