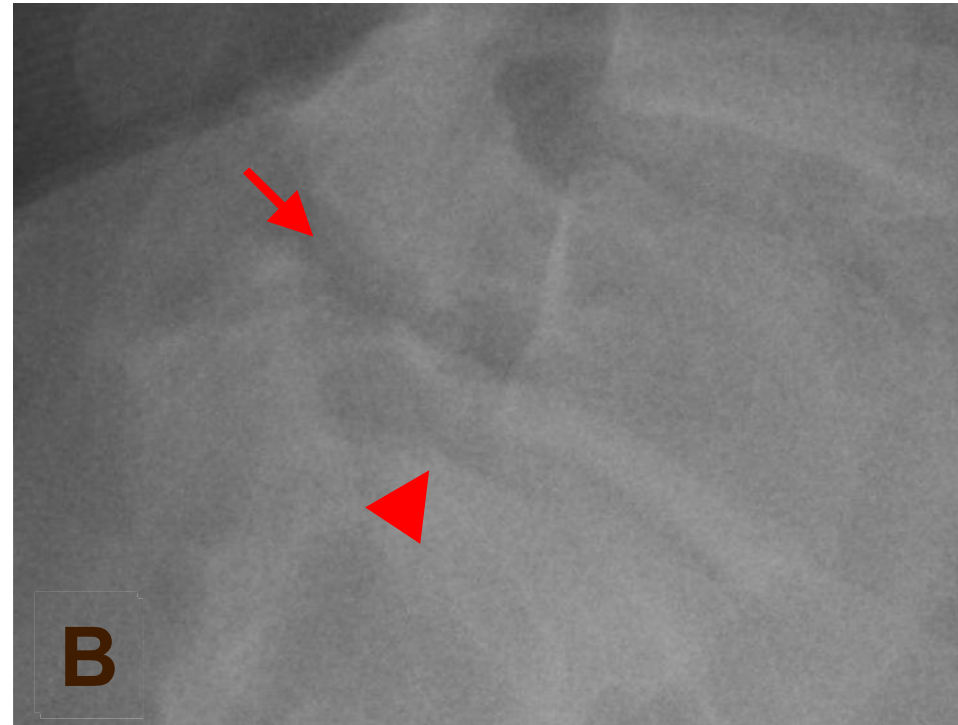
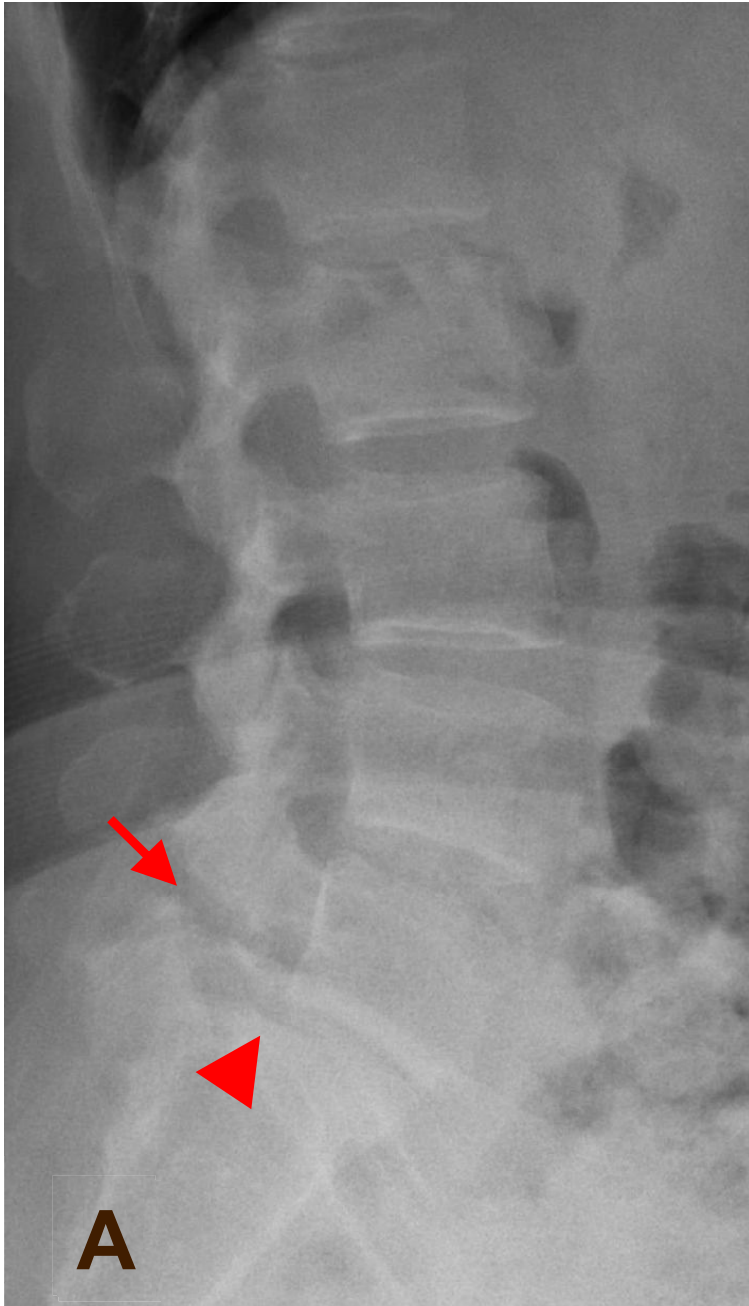

**Ans: Fracture at L5 pars articularis (spondylolysis) with spondylolisthesis**



Fracture of pars articularis may following form repetitive minor trauma, congenital malformation, hereditary hypoplasia or secondary to neoplasia, Spondylolisthesis is the anterior displacement of a vertebra in relation to the below vertebra. inflammation. Fracture at L5 pars articularis (arrow) & spondylolisthesis (grade I)(arrow head) are seen in A & B.