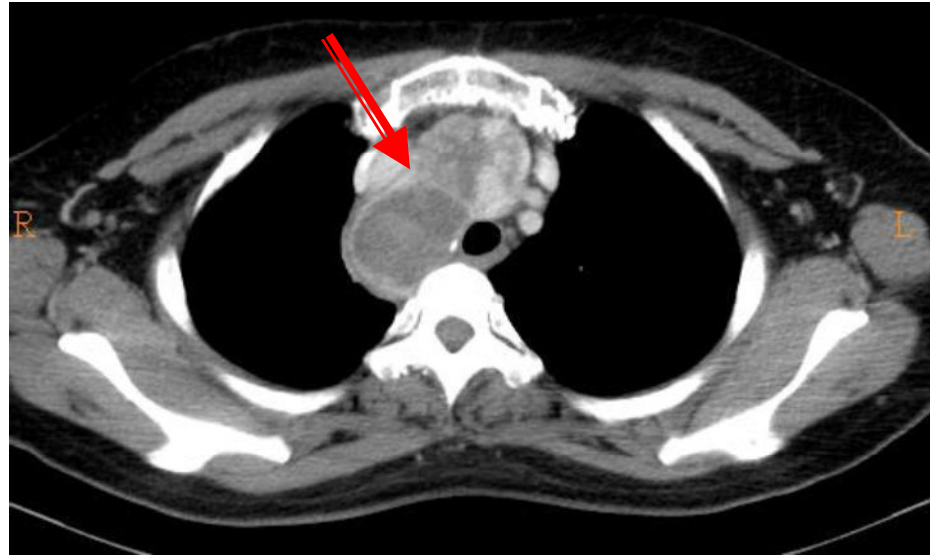


## ■ Final diagnosis: Intrathoracic goiter

Key points:



There is a lobulated heterogeneous enhanced mass (arrow) at right-sided superior mediastinum extension of cervical thyroid mass into mediastinum