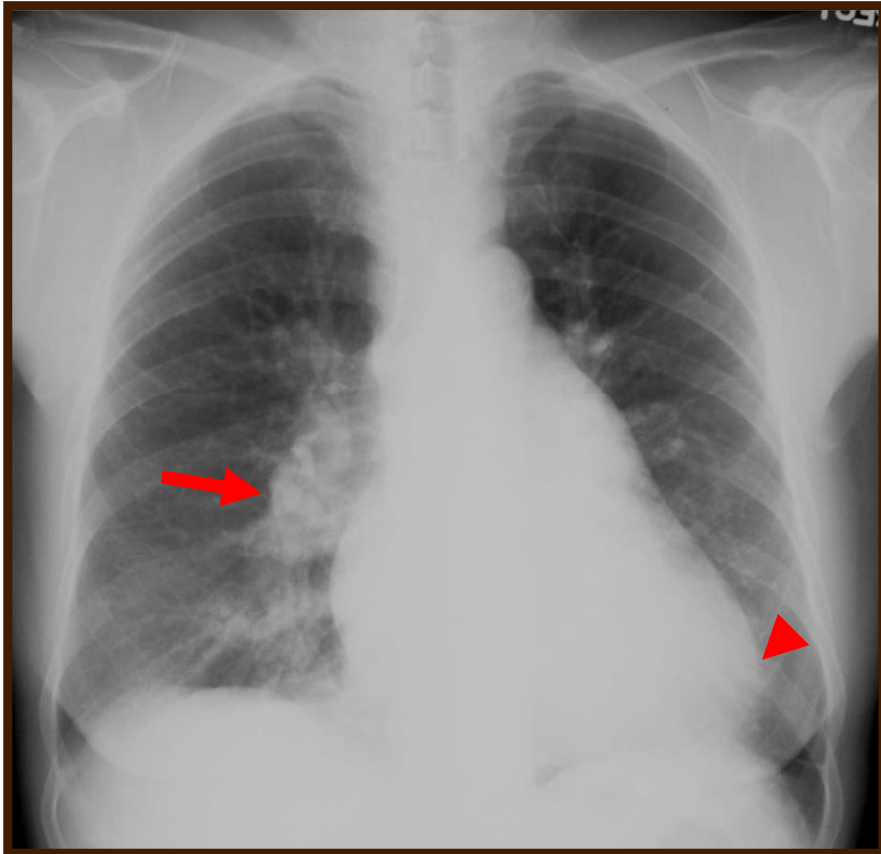


Final diagnosis: ASD



Key images

* bilateral hilar enlargement
(arrow)

* RVH
(arrow head)

DDx.

Increased pulmonary vascularity due to left to right shunt, such as ASD, VSD, PDA, the other such as PAPVR, systemic AV fistula etc.

DDx.

Idiopathic Pulmonary arterial hypertension, Left heart failure, or Fluid overload etc