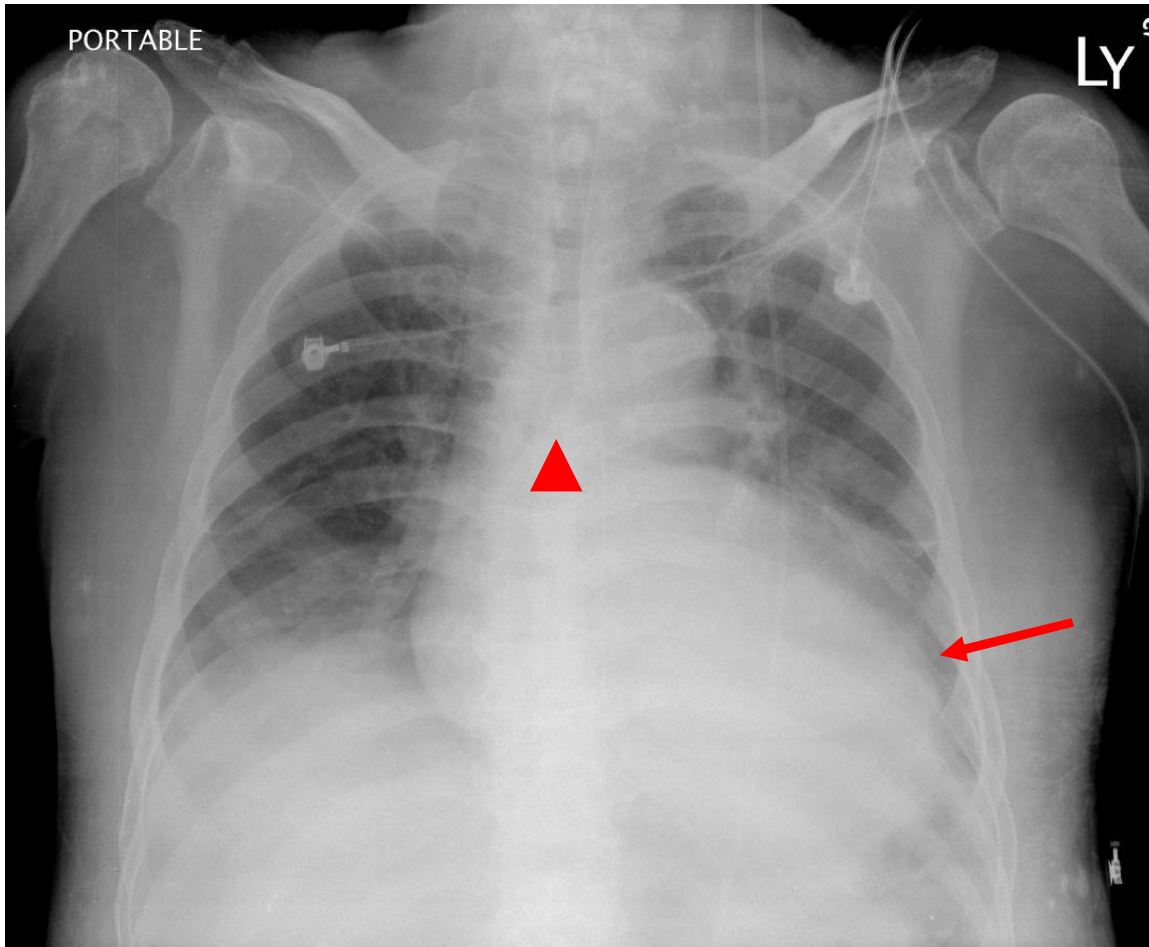


# Final diagnosis: Pericardial Effusion



Key points:

Water-bottle shaped appearance (arrow) and diagnosis by plain chest radiograph and associated with widened subcarinal angle (arrow head)

DDx.

cardiomegaly including  
Valvular heart disease,  
Dilated cardiomyopathy,  
Pericardial effusions or  
mediastinal tumor such as  
thymic cyst etc