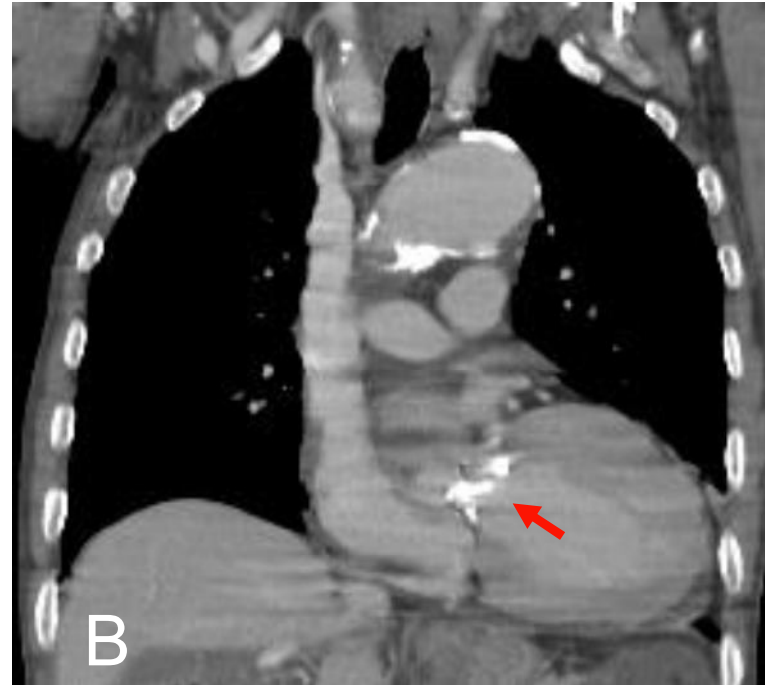
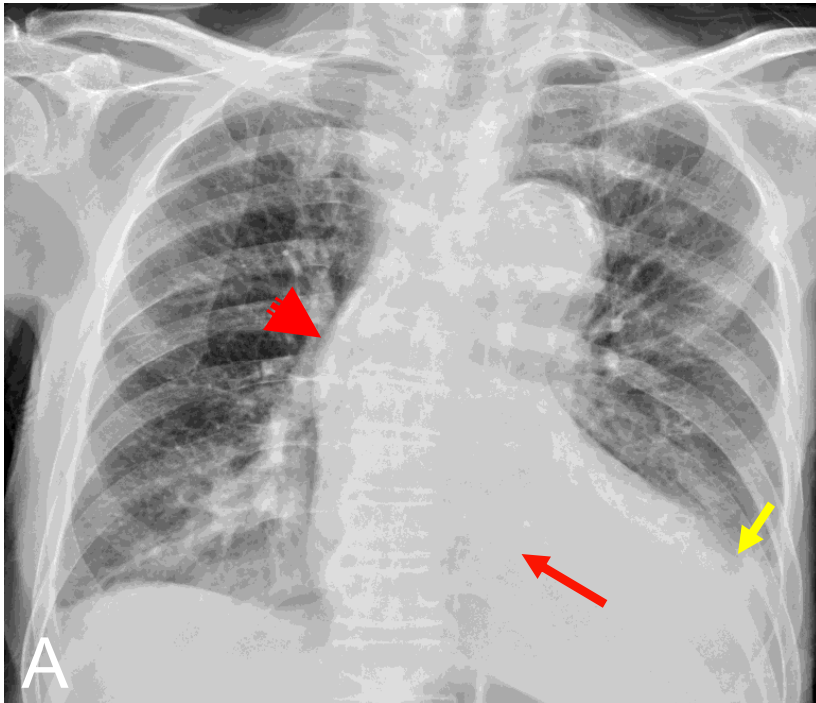


Dx. Aortic insufficiency, with aortic valve calcification



Aortic valve calcification (red arrow in A), post-stenotic dilatation of ascending aorta (arrow head in A), left ventricular enlargement (yellow arrow in A).

CT show aortic valve calcification (red arrow in B), compare with plain film the same position.