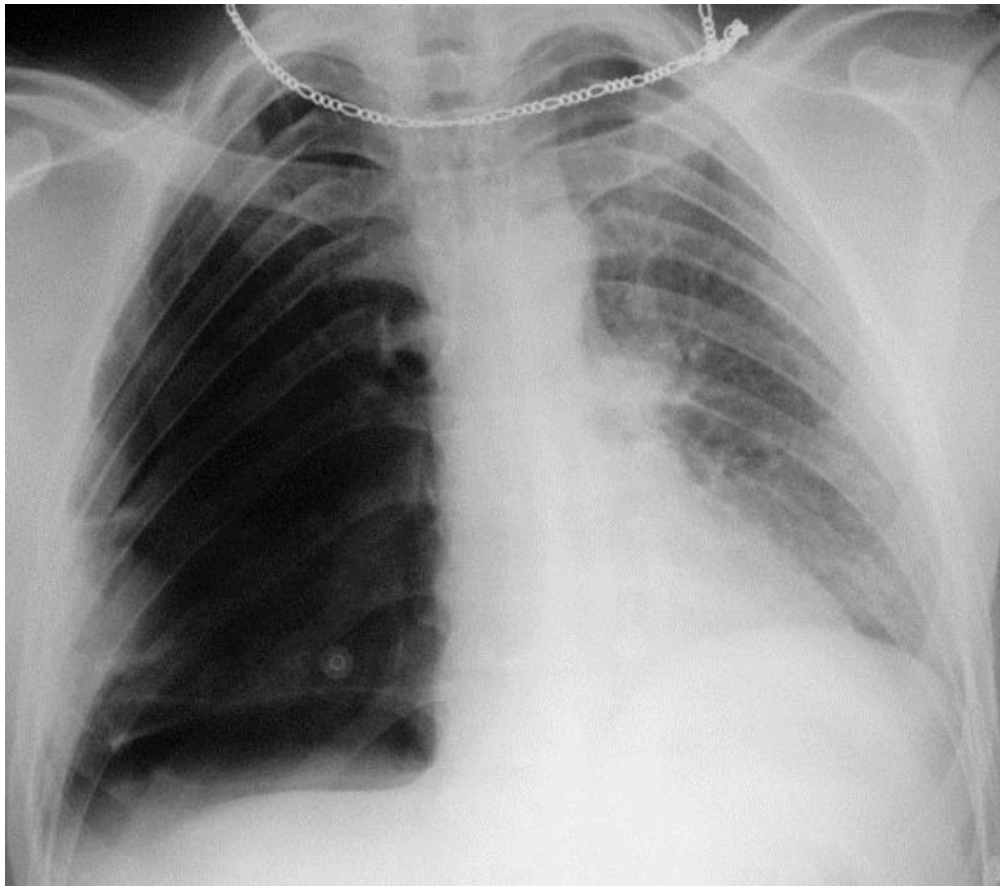


# ■ Final diagnosis: Tension Pneumothorax

## Key points: by plain film



### Findings:

- Hyperlucency of right hemithorax
- inverted right hemi-diaphragm
- leftward mediastinal shift
- Increased marking of contra lateral lung due to congested lung

### DDx. unilateral lucent lung

- air-trapping from Foreign Body Aspiration
- Swyer-James syndrome
- oligemia  
(massive Pul. Embolism)