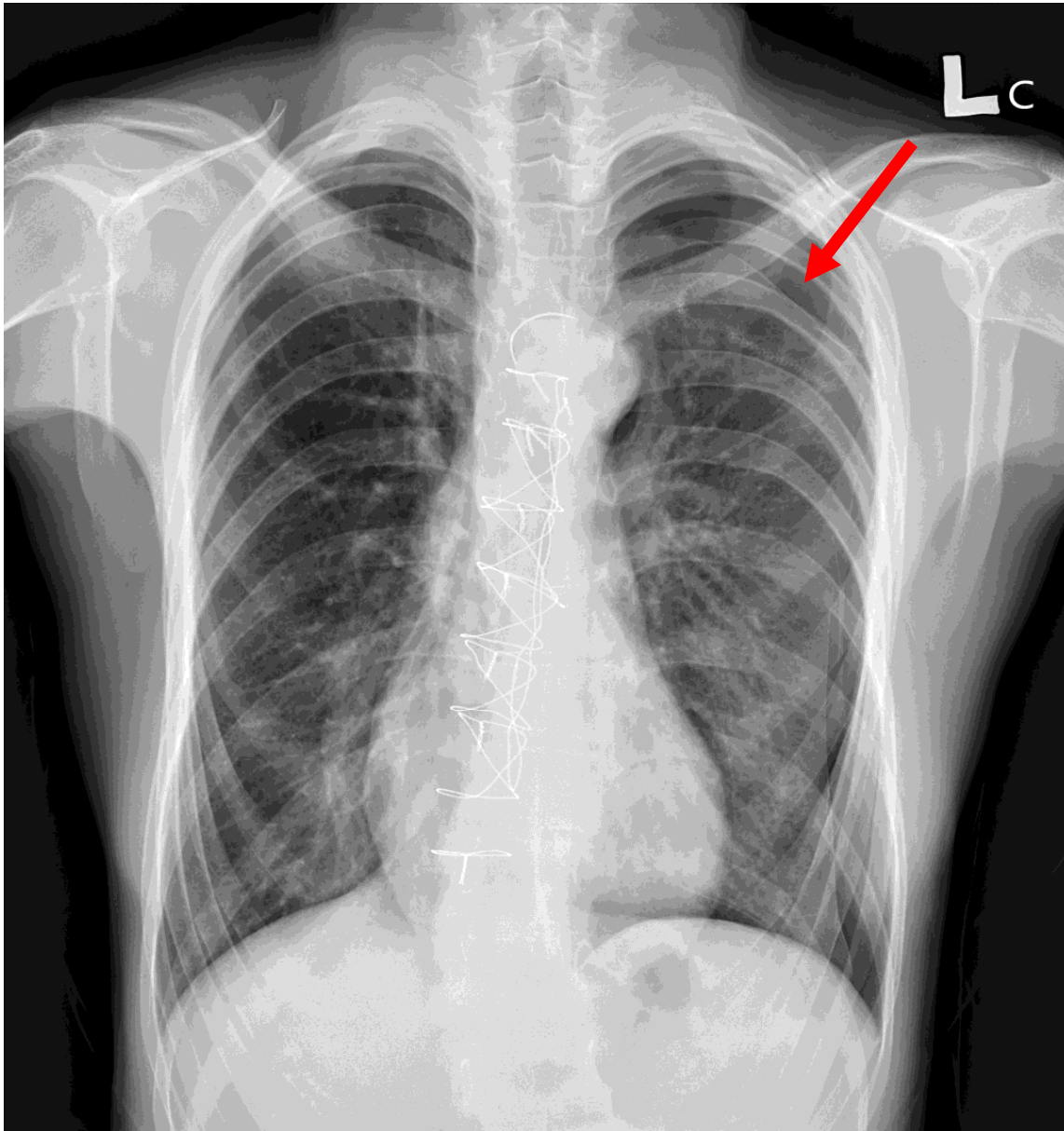


# Final diagnosis: Pneumothoax



Key points:

Diagnosis by plain chest finding:

Pleural line demonstration  
Adjacent lung passive atelectatic changes

DDx.

Giant bulla

Lobar emphysema