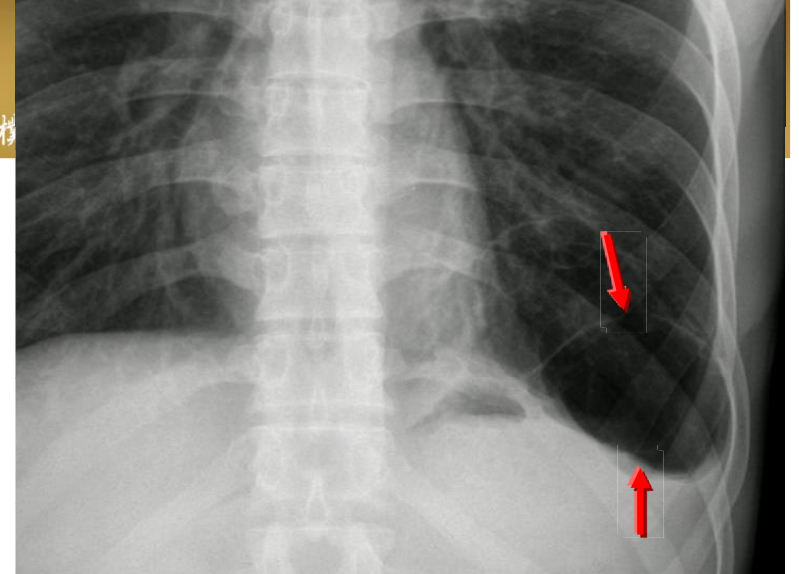


Pulmonary bullae



■ 診斷重點:

- Sharoply demarcated dilated air space within lung parenchyma > 1 cm in diameter with epithelialized wall < 1 mm thick due to destruction of alveoli
- Pulmonary bullae are focal regions of emphysema with no discenible wall which measure more than 1cm in diameter
- They are often subpleural in location and may result in spontaneous pneumothorax.
- In some cases bullae can be very large and result in compression of adjacent lung.